

ORIGINAL REPORT

CHANGES IN PROPRIOCEPTIVE SYSTEMS ACTIVITY DURING RECOVERY FROM POST-STROKE HEMIPARESIS

Alexander Thiel, MD², Beatrice Aleksic, MD², Johannes Ch. Klein, MD², Jobst Rudolf, MD², and Wolf-Dieter Heiss, MD¹

From the ¹Max Planck Institute for Neurological Research with Klaus-Joachim-Zülch-Laboratories of the Max Planck Society and the Faculty of Medicine of the University of Cologne and ²Department of Neurology, University of Cologne, Köln, Germany

Objective: To investigate the activity of proprioceptive systems during early recovery of motor function after ischaemic stroke in a prospective, longitudinal, functional imaging study.

Methods: Ten patients with unilateral infarction of the posterior internal capsule were investigated using oxygen-15-water positron emission tomography during passive extension of the index finger. Patients were assessed initially after stroke (mean 4.7 days) and again after rehabilitation. Changes in brain activation patterns were analysed.

Results: All patients showed significant improvement in motor function of the paretic limb. During passive finger movement of the non-paretic index finger, significant increases in cerebral blood flow were observed in the somatosensory areas I and II (SI and SII) of the non-infarcted hemisphere. Additionally, significant activation of ipsilateral SII in the infarcted hemisphere was observed. After rehabilitation, ipsilateral SII activation vanished and the normal activation pattern was restored. During passive movement of the paretic index finger only SI and SII of the infarcted hemisphere were activated. During rehabilitation, additional recruitment of SII in the non-infarcted hemisphere occurred.

Conclusion: Recovery from internal capsule infarction is accompanied by substantial changes in activity of proprioceptive systems of the paretic and non-paretic limb. These changes may reflect an inter-hemispheric shift of attention to proprioceptive stimuli associated with recovery.

Key words: functional imaging, proprioception, attention, post-stroke recovery.

J Rehabil Med 2007; 39: 520–525

Correspondence address: Wolf-Dieter Heiss, Max Planck Institute for Neurological Research, with Klaus-Joachim-Zülch-Laboratories of the Max Planck Society, and the Faculty of Medicine of the University of Cologne, Gleueler Str. 50, DE-31 Köln, Germany. E-mail: wdh@nf.mpg.de

Submitted May 10, 2006; accepted March 9, 2007

INTRODUCTION

Due to its outstanding significance for clinical rehabilitation, the investigation of motor systems employing active motor tasks has been the focus of several functional neuroimaging

studies of post-stroke patients (1–4). Little, however, is known about the role of proprioceptive systems in stroke rehabilitation, even in pure motor dysfunction. This is all the more surprising since physiotherapy, the therapeutic standard of hemiparesis rehabilitation, regularly makes use of proprioceptive facilitation strategies (5, 6) and the alteration of muscle tone in a paretic limb may have an impact on proprioceptors in muscles and tendons even if the fibre tracts of the proprioceptive system itself have not been affected by the brain lesion.

Few studies have so far investigated proprioceptive systems using functional imaging. Early positron emission tomography (PET) studies employing passive movement of a whole forearm in normal subjects observed contralateral activation, not only of the primary (SI) and secondary (SII) somatosensory cortex, but also of the primary motor cortex (MI) (7). More sophisticated passive activation paradigms using purely isometric stimulation of a single index finger, however, were able to demonstrate selective activation of contralateral SI and SII in normal subjects (8).

A study in which passive movement was compared with the illusion of movement induced by tendon vibration (9) has shown that perception of passive movements and illusions of movements are associated with different patterns of brain activation. Increases in regional cerebral blood flow (rCBF) in SI/MI and supplementary motor area (SMA) were only observed in response to passive movement encompassing multiple peripheral sensory inputs. On the other hand, both perception of passive movements and illusory movements induced by tendon vibration activated SII (12) and parts of MI (10). Comparison of activation intensities under different functional conditions indicates the involvement of SII in stimulus perception generation and of the SI/MI areas in the processing of proprioceptive input.

Even fewer studies have investigated the role of the SI and SII in stroke recovery. In these chronic patients, redistribution of relative activity between SI and SII within a single hemisphere (11), as well as shift of activity in SI and SII between both hemispheres (12), has been described in response to electrical stimulation. The only studies that have investigated passive movement of the forearm (13) or the wrist (14) in recovery from stroke have shown complex activation patterns encompassing contralateral sensorimotor cortex, bilateral

inferior parietal cortex and cingulum. It has been argued that these complex activation patterns in patients after stroke are, at least in part, caused by the large number of proprioceptors that were passively activated, as well as by attention of the subjects to the arm movement (15).

The significance of these studies for actual rehabilitation treatment may, however, be limited, because all patients were investigated in a stable chronic phase. Most spontaneous recovery of motor function takes place within the first weeks and months after stroke and early stimulation of the patient seems to be crucial for a good outcome of rehabilitation treatment (16). Our study has thus been designed to characterize post-stroke plasticity of proprioceptive systems during the very early stages of recovery. We investigated 10 patients with very small and circumscribed infarctions of the posterior limb of the internal capsule, in a longitudinal study at a mean of 4.7 days and 17.6 days after stroke. All suffered from paresis of the contralateral upper limb without impairment of tactile sensation. Since thalamocortical fibres projecting from the ipsilateral ventral thalamus to SI and SII also run through the posterior limb of the internal capsule, a modulatory effect on proprioceptive systems may be expected. We have chosen passively to extend the index finger of both the paretic and non-paretic hand in order to yield an activation that is very circumscribed in space, but highly intense due to the high density of proprioceptors in finger muscles and to minimize the differences in sensory input between resting and activation condition.

METHODS

Patients

Ten patients (5 men, 5 women, age range 38–69, median 62.5 years) with first-time acute stroke were included in this study, which was approved by the ethics committee of Cologne University's Medical Faculty. Computerized tomography (CT) and/or magnetic resonance imaging (MRI) performed within the first 3 days demonstrated a single ischaemic lesion in the posterior limb of the internal capsule on the right ($n = 7$) or left ($n = 3$) side. Intracranial haemorrhage or other causes of the neurological deficits were ruled out, occlusion or high-grade stenosis of neck or intracranial vessels were excluded by continuous wave- and Duplex-Doppler as well as trans-cranial Doppler sonography. Patients with severe internal disorders, and those who could not give informed consent to the study protocol, were not included in this study. All patients presented mild to moderate unilateral motor deficits without significant sensory loss. Patients with disturbances of higher brain function (e.g. aphasia, agnosia, neglect), of memory or of cognition were not included. Neurological deficits were assessed on initial clinical presentation and, on the days of activation studies, using the National Institutes of Health's Stroke Score (NIHSS), Modified Rankin Score, Barthel Index, Rivermead Motor Assessment, Perdue Pegboard Test and a finger tapping task. All patients received 45 minutes of physiotherapy per day according to the Bobath method in an individual therapy session.

Imaging

rCBF, at rest and during passive movement of the index finger of the affected and unaffected hand, was measured 4.7 (standard deviation (SD) 2.00) days and 17.6 (SD 3.34) days after stroke using intravenous single bolus injection of $H_2^{15}O$ (370 MBq, (17)) and a high-resolution PET scanner (ECAT EXACT HR, CTI/Siemens, Knoxville, TN, USA) in 3D mode (18), covering the whole brain including the cerebellum.

Patients received 12 consecutive injections of $H_2^{15}O$ at each session; 4 scans were acquired during rest, 4 during passive finger movement of the affected hand, and 4 of the unaffected hand. For passive finger movement, the paretic hand rested comfortably on a platform with the volar side down. The index finger was gently fixed on a splint and the tip of the splint was moved up and down by an eccentric motor, thus causing a dorsal extension of the finger in the metacarpo-phalangeal joint of 30° at a frequency of 0.7/second. During the control conditions the finger rested on the splint so that the sensory input over the skin of the finger was comparable between conditions, and differences in sensory input were minimized. Movement was started 10 seconds prior to tracer injection and was stopped at the end of the scan. Subsequent scans obtained in each patient were corrected for random coincidences, scatter and measured attenuation and reconstructed to 47 slices (3.125 mm thickness, 128×128 matrix of 2.16 mm pixels) yielding images of rCBF. For localization of infarction and PET-measured CBF changes, MRI was performed on a 1.5T Philips Gyroscan Intera (Philips, Best, The Netherlands) using a 3D gradient-recalled echo sequence (TR 700 ms, TE 8 ms) producing 256 trans-axial T1-weighted slices of 1 mm thickness.

Statistical analysis

PET datasets of the 3 patients with left hemisphere infarct were mirrored across the mid-sagittal plane so that, in all patients, the infarct was located on the right side of the image volume. All PET images were realigned, smoothed (Gaussian filter, FWHM 12 mm) and normalized to Montreal Neurological Institute (MNI) space using statistical parametric mapping (SPM) 99 (19). Scans were normalized for differences in global CBF by proportional scaling to a global mean CBF of 50 units. Statistical parametric t -images were calculated using the SPM general linear model. Voxels were considered as significantly activated if they exceeded a threshold of $p = 0.05$, corrected for multiple comparisons. The locations of significantly activated voxels are reported in Talairach co-ordinates after conversion from MNI to Talairach space.

In order to exclude the possibility that changes in resting flow pattern during recovery were responsible for the observed stimulation-associated changes in CBF, a set of volumes of interest (VOIs) was derived comprising left and right SI and SII by thresholding the parametric activation images at $t = 3.13$. CBF was measured in these VOIs and tested for differences between the initial and follow-up measurement.

Changes in motor performance and clinical outcome as well as correlations between behavioural scores and activation magnitude were assessed using Wilcoxon's paired signed rank test, paired t -test and Spearman's rank correlation, respectively. All behavioural data are reported as means and standard deviation.

RESULTS

Mean volume of infarction in the posterior limb of the internal capsule was 1.7 ccm (SD 2.15 cm³). The mean time post-stroke of the initial PET measurement and behavioural assessment was 4.7 (SD 2.00) days and 17.6 (SD 3.34) days for the follow-up assessment.

Motor impairment was mild to moderate on initial testing (NIHSS 5.1 (SD 0.99), Rankin Scale 2.3 (SD 0.95), Barthel Index 94.5 (SD 1.58), Rivermead Motor Assessment 23.9 (SD 8.27) and Pardue-Pegboard Test 25.5 (SD 8.17)). There was no significant correlation between initial clinical and motor scores and the infarct volume (Spearman's rank correlation coefficient, $p > 0.05$). However, a significant negative correlation between activation intensity and behavioural measures could be established for movement of the paretic hand in SI ipsilateral to the lesion ($p < 0.001$, $r = -0.83$) and SII ipsi-

lateral ($p = 0.054, r = 0.613$). Infarct volume was correlated significantly with activation of SI ($r = 0.93, p < 0.001$) and SII ($r = 0.77, p < 0.007$) in the hemisphere contralateral to the lesion during movement of the non-paretic hand, demonstrating a linear effect of lesion size onto activity in the unaffected hemisphere (Fig. 1)

Patients showed significant improvement ($p < 0.05$, Wilcoxon's paired signed-rank test) in all tests at follow-up indicating only mild residual impairment (follow-up NIHSS 1.4 (SD 0.84), Rankin Scale 1.0 (SD 0.00), Barthel Index 100 (SD 0.00), Rivermead Motor Assessment 32.2 (SD 4.61) and Pardo-Pegboard Test 30.1 (SD 8.13)). For a summary of results see Table I.

PET data

Stimulation of unaffected finger. Significant activations were found in the SI of the contralateral hemisphere in Brodmann area (BA) 3 (at $x = -37, y = -28, z = 47$) as well as the SII in BA40 and 39 (at $x = -51, y = -26, z = 19$) on the initial PET scan when comparing activation vs rest for the unaffected finger (Fig. 2a, Table II). Interestingly, activation within SII of the ipsilateral hemisphere during passive movement of the unaffected finger was observed (at $x = 55, y = -28, z = 17$). At follow-up, movement of the unaffected finger showed a persisting activation of the contralateral SI (at $x = -45, y = -22, z = 48$) and SII (at $x = -59, y = -24, z = 17$), but significant activation of ipsilateral SII was no longer observed (Fig. 2b, Table II).

Stimulation of affected finger. During passive movement of the affected finger at initial study, only significant activations of SI (at $x = 49, y = -24, z = 45$) and SII (at $x = 51, y = -30, z = 18$) in the contralateral hemisphere were observed (Fig. 2c, Table II). A minor activation of SII in the ipsilateral hemisphere did not reach significance. During movement of the

Activation in SI and SII of contralesional hemisphere during movement of unaffected hand versus lesion volume

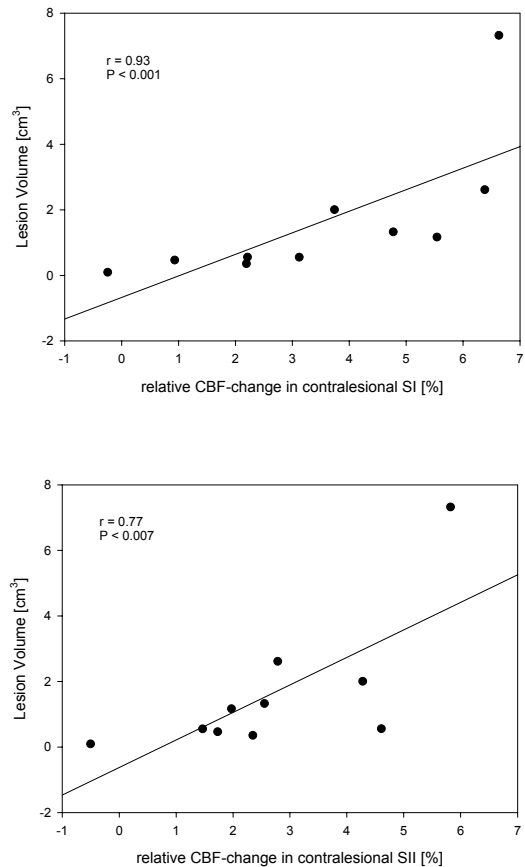


Fig. 1. Statistical parametric maps of the 4 contrasts investigated in the study. Shown are voxels that are significantly ($p = 0.05$ corrected for multiple comparisons) activated during passive finger movement of the affected and unaffected hand during initial and follow-up examination. CBF: cerebral blood flow.

Table I. Patients' clinical data at initial and follow-up examination.

Patient no.	Age Sex	Infarct side	Infarct Vol (cm³)	NIHSS *		mRS†		BI‡		RMA§		PTT¶	
				Initial	Follow-up	Initial	Follow-up	Initial	Follow-up	Initial	Follow-up	Initial	Follow-up
1	M 38	Right	7.323	7	3	2	1	95	100	32	33	28	36
2	M 56	Left	0.558	5	2	3	1	95	100	31	32	31	35
3	F 65	Right	0.468	5	1	3	1	90	100	24	30	30	28
4	F 66	Left	0.359	6	1	2	1	95	100	21	37	21	21
5	F 69	Left	0.555	4	0	0	1	95	100	10	33	42	48
6	M 44	Right	2.616	4	2	2	1	95	100	32	38	30	28
7	F 69	Right	0.096	5	1	2	1	95	100	30	30	22	31
8	F 61	Right	1.169	5	1	3	1	95	100	24	25	16	20
9	M 64	Right	1.329	4	2	3	1	95	100	25	38	18	28
10	M 46	Right	2.007	6	1	3	1	95	100	10	26	17	26
Mean	57.80		1.65	5.1	1.4	2.3	1	94.5	100	23.90	32.20	25.50	30.10
SD	11.27		2.15	0.994429	0.84327	0.949	0	1.58	0	8.266	4.61399	8.17	8.13
Median	62.5		0.8635	5	1	2.5	1	95	100	24.50	32.50	25.00	28.00

Difference significant at * $p = 0.002$; † $p = 0.01$; ‡ $p = 0.002$; § $p = 0.004$; ¶ $p = 0.02$.

NIHSS: National Institutes of Health Stroke Scale; mRS: modified Rankin Scale; BI: Barthel-Index; RMA: Rivermead Motor Assessment; PPT: Pardo-Pegboard Test; SD: standard deviation.

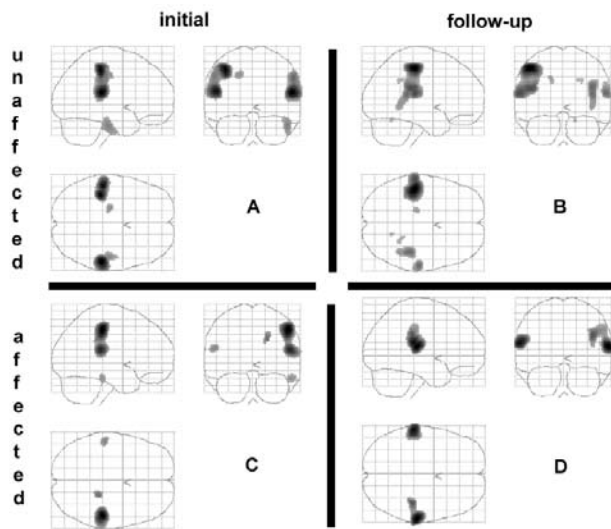


Fig. 2. Correlation between activation-related regional cerebral blood flow (rCBF) change in somatosensory areas I (SI) and somatosensory areas II (SII) of the unaffected hemisphere during passive movement of the unaffected finger and infarct volume. The greater the infarct, the greater the activity in the contralateral hemisphere.

affected finger at follow-up significant bilateral activation of SII occurred (Fig. 2d, Table II) (at $x = 61, y = -22, z = 13$ and $x = -61, y = -26, z = 19$). Activation of contralateral SI was also observed in a more inferior position than before (at $x = 39, y = -27, z = 27$) but did not reach significance at voxel level.

In the VOI analysis no difference in relative resting CBF between the initial and follow-up scans for the 4 VOIs was detected (Fig. 3) after correction for multiple comparisons ($p = 0.0125$).

Table II. Activated brain regions for passive finger movement of affected and unaffected limb with *t*-values and Talairach coordinates.

Region	Talairach			<i>t</i>	<i>p</i> (corrected)
	<i>x</i>	<i>y</i>	<i>z</i>		
Movement unaffected finger initial scan					
Right SII	55	-28	17	5.24	0.002
Left SI	-37	-28	47	5.13	0.004
Left SII	-51	-26	19	5.06	0.005
Movement unaffected finger follow-up					
Left SI	-45	-22	48	5.63	0.000
Left SII	-59	-24	17	4.56	0.036
Movement affected finger initial scan					
Right SI	49	-24	45	4.86	0.011
Right SII	51	-30	18	4.50	0.044
Movement affected finger follow-up					
Left SII	-61	-26	19	4.80	0.014
Right SII	61	-22	13	4.97	0.007
Right SI	39	-27	27	4.12	ns

SI: somatosensory areas I; SII: somatosensory areas II; ns: not significant.

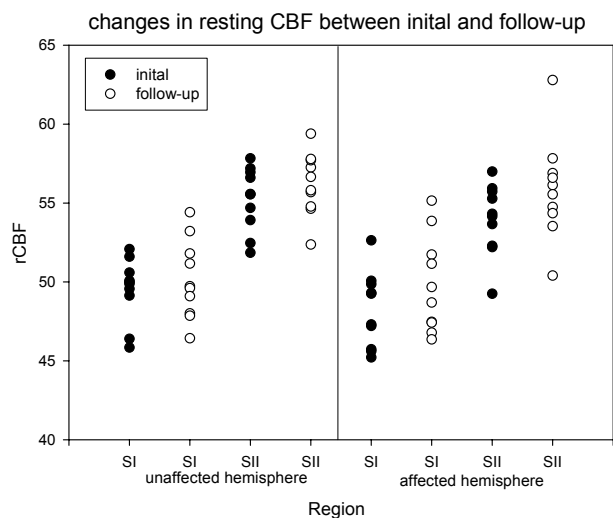


Fig. 3. Resting regional cerebral blood flow (rCBF) in somatosensory areas I (SI) and somatosensory areas II (SII) of both hemispheres. No significant differences between initial and follow-up scans were observed (paired *t*-test, corrected for multiple comparisons, $p = 0.0125$).

DISCUSSION

This study demonstrates that even a very simple stimulation paradigm, i.e. passive movement of the index finger of the affected (paretic) or the unaffected hand, elicits a complex activation pattern with bilateral cortical flow increases and spreading of activity beyond the cortical representation of the stimulated limb, as was repeatedly reported for various tasks in subacute and chronic subcortical strokes (20–22). In subcortical stroke, over-recruitment of motor and non-motor areas in both hemispheres was the main finding regardless of the type of stimulation. This was demonstrated in most active motor tasks (finger-to-thumb sequential opposition, thumb-to-index tapping and other movements of the upper limb), but also in passive elbow flexion (13) and flexion/extension of the paretic wrist (14).

Longitudinal studies, usually performed in subacute (weeks) to chronic state (months) after stroke revealed dynamic changes of these activation patterns suggesting that recovery is in most instances accompanied by an approximation of the normal activation pattern. Over time, focalization of activation to ipsilesional SM1 (23–25) occurred. This observation was consistent with findings from longitudinal studies in a rat stroke model in which functional improvement was accompanied by reactivation of the ipsilesional cortex (26).

The present study is the first to demonstrate similar dynamic changes in the acute phase of recovery after subcortical stroke, i.e. between 4.7 (SD 2.00) and 17.6 (SD 3.34) days. The activation paradigm, targeted to selectively activate proprioception with a minimal contribution from tactile senses and avoiding active muscle involvement (8), induced activation patterns in patients with moderate motor deficits due to subcortical ischaemic strokes that were different from those observed in normal volunteers. In normal volunteers, passive finger move-

ment activated only the contralateral primary and secondary sensory areas (8). Passive finger movement of the unaffected side in the first week after stroke additionally activated SII on the side ipsilateral to stimulation (the affected hemisphere). Passive movement of a finger in the paretic hand in the first week after stroke induced marked activation in SI and SII in the affected hemisphere, but only slight activation of contralateral SII; a pattern comparable to that in healthy subjects. However, with clinical improvement between scans, activation in SI and in SII of the affected hemisphere remained unchanged and activation of SII in the contralateral hemisphere became prominent. This activation during movement of the affected finger at follow-up corresponds to the pattern observed by Nelles et al. (13) at his initial scan (which was around day 20 after ictus, like our follow-up scan).

The pattern observed with passive finger movement of the unaffected side normalized over time.

Increased and extended activation in early reorganization was observed repeatedly in the first weeks after stroke (13, 27, 28). The activation of SII, which has the function of a higher order somatosensory centre (29, 30) with a sensorimotor integration role (14, 31, 32), changes during recovery. Ipsilateral SII activation in response to stimulation might be driven by contralateral SII via transcallosal fibres (33), and SII of the affected hemisphere becomes activated more strongly than SI with improvement of function. This activation suggests parallel information processing in SII mediated by direct thalamocortical input to SII maintained despite lower activation of the partly deafferented SI (11).

It is difficult to explain the changing patterns of activation in SII by plasticity of the proprioceptive system: the time span is very short, and the involvement of the ipsilateral hemisphere by stimulation of the unaffected finger cannot be attributed to a lesion effect onto proprioceptive processing. One possible explanation for this sudden occurrence of the ipsilateral (contra-lesional) activity during passive movement of the unaffected finger may be a reduction in transcallosal inhibition of the affected onto the intact hemisphere. The fact that activity in SI and SII of the unaffected hemisphere was correlated with volume size may also support this hypothesis. The existence of these mechanisms has recently been demonstrated by our group for the language system (34). However, in subcortical infarctions no differences in inter-hemispheric inhibition between control subjects and patients after stroke were found in studies with double pulse transcranial magnetic stimulation (35, 36). Only during the phase of movement preparation was an inhibitory influence from the intact onto the affected hemisphere observed (36), a finding which is unique for subcortical infarcts and contrary to what is known from cortical infarcts. It is thus more likely that this finding indicates a disturbance of the cortical-basal ganglia loop for movement preparation (37) of the affected hemisphere and not a disturbance of transcallosal inhibition because the transcallosal fibres are intact in patients with subcortical stroke.

An alternative explanation for these changes in activation patterns might be attentional modulation of activity in SII

(15). The observed pattern of activation is compatible with increased attention to proprioceptive input in the very early course after stroke. At that time, attention modulates only the activation pattern elicited by movement of the unaffected limb, since networks of the affected hemisphere are disturbed by the lesion. Later on, the effect of attention, expressed as activation of SII, may shift to movements of the affected limb and go along with early recovery and resolution of neglect. After this refocusing of attention to the paretic side, mechanisms of neuronal reorganization, as described, for example, by Nelles et al. (13) determine further recovery: The "less efficient reorganization process" (2) involving the ipsilateral cortex (i.e. ipsilateral to the stimulated finger) may be replaced by the restitution of the activation patterns involving predominantly the sensorimotor area of the afflicted hemisphere. However, these mechanisms extend beyond the observation period in our study, and are described in the study by Nelles et al. (13). It has to be tested in future studies whether rehabilitation or pharmacological strategies can accelerate the attentional shift (38) and the reactivation of physiological activation patterns, and whether these interventions will improve rehabilitation of motor function after stroke.

ACKNOWLEDGEMENT

The study was supported by a grant from the Marga and Walter Boll-Foundation, Kerpen, Germany.

REFERENCES

1. Weiller C. Imaging recovery from stroke. *Exp Brain Res* 1998; 123: 13–17.
2. Calautti C, Baron JC. Functional neuroimaging studies of motor recovery after stroke in adults: a review. *Stroke* 2003; 34: 1553–1566.
3. Cramer SC. Functional imaging in stroke recovery. *Stroke* 2004; 35: 2695–2698.
4. Ward NS, Cohen LG. Mechanisms underlying recovery of motor function after stroke. *Arch Neurol* 2004; 61: 1844–1848.
5. Taub E, Uswatte G, Elbert T. New treatments in neurorehabilitation founded on basic research. *Nat Rev Neurosci* 2002; 3: 228–236.
6. Nudo RJ. Recovery after damage to motor cortical areas. *Curr Opin Neurobiol* 1999; 9: 740–747.
7. Weiller C, Juptner M, Fellows S, Rijntjes M, Leonhardt G, Kiebel S, et al. Brain representation of active and passive movements. *Neuroimage* 1996; 4: 105–110.
8. Mima T, Sadato N, Yazawa S, Hanakawa T, Fukuyama H, Yonekura Y, et al. Brain structures related to active and passive finger movements in man. *Brain* 1999; 122: 1989–1997.
9. Radovanovic S, Korotkov A, Ljubisavljevic M, Lyskov E, Thunberg J, Kataeva G, et al. Comparison of brain activity during different types of proprioceptive inputs: a positron emission tomography study. *Exp Brain Res* 2002; 143: 276–285.
10. Naito E, Roland PE, Ehrsson HH. I feel my hand moving: a new role of the primary motor cortex in somatic perception of limb movement. *Neuron* 2002; 36: 979–988.
11. Taskin B, Jungehulsing GJ, Ruben J, Brunecker P, Krause T, Blankenburg F, et al. Preserved responsiveness of secondary somatosensory cortex in patients with thalamic stroke. *Cereb Cortex* 2006; 16: 1431–1439.

12. Forss N, Hietanen M, Salonen O, Hari R. Modified activation of somatosensory cortical network in patients with right-hemisphere stroke. *Brain* 1999; 122: 1889–1899.
13. Nelles G, Spiekermann G, Jueptner M, Leonhardt G, Müller S, Gerhard H, et al. Evolution of functional reorganization in hemiplegic stroke: a serial positron emission tomographic activation study. *Ann Neurol* 1999; 46: 901–909.
14. Loubinoux I, Carel C, Pariente J, Dechaumont S, Albucher JF, Marque P, et al. Correlation between cerebral reorganization and motor recovery after subcortical infarcts. *Neuroimage* 2003; 20: 2166–2180.
15. Johansen-Berg H, Christensen V, Woolrich M, Matthews PM. Attention to touch modulates activity in both primary and secondary somatosensory areas. *Neuroreport* 2000; 11: 1237–1241.
16. Johansson BB. Neurorehabilitation and brain plasticity. *J Rehabil Med* 2003; 35: 1.
17. Raichle ME, Martin WRW, Herscovitch P, Kilbourn MR, Welch MJ. Measurement of cerebral blood flow with C-11 butanol and positron emission tomography. *J Nucl Med* 1983; 24: 63.
18. Wienhard K, Dahlbom M, Eriksson L, Michel C, Bruckbauer T, Pietrzyk U, et al. The ECAT EXACT HR: performance of a new high resolution positron scanner. *J Comput Assist Tomogr* 1994; 18: 110–118.
19. Friston KJ, Frith CD, Liddle PF, Frackowiak RSJ. Comparing functional (PET) images: the assessment of significant change. *J Cereb Blood Flow Metab* 1991; 11: 690–699.
20. Weiller C, Ramsay SC, Wise RJS, Friston KJ, Frackowiak RSJ. Individual patterns of functional reorganization in the human cerebral cortex after capsular infarction. *Ann Neurol* 1993; 33: 181–189.
21. Cramer SC, Nelles G, Benson RR, Kaplan JD, Parker RA, Kwong KK, et al. A functional MRI study of subjects recovered from hemiparetic stroke. *Stroke* 1997; 28: 2518–2527.
22. Cao Y, D'Olhaberriague L, Vikingstad EM, Levine SR, Welch KMA. Pilot study of functional MRI to assess cerebral activation of motor function after poststroke hemiparesis. *Stroke* 1998; 29: 112–122.
23. Feydy A, Carlier R, Roby-Brami A, Bussel B, Cazalis MS, Pierot L, et al. Longitudinal study of motor recovery after stroke. *Stroke* 2002; 33: 1610–1617.
24. Calautti C, Leroy F, Guincestre J-Y, Baron J-C. Dynamics of motor network overactivation after striatocapsular stroke: a longitudinal PET study using a fixed-performance paradigm. *Stroke* 2001; 32: 2534–2542.
25. Small SL, Hlustik P, Noll DC, Genovese C, Solodkin A. Cerebellar hemispheric activation ipsilateral to the paretic hand correlates with functional recovery after stroke. *Brain*. 2002 Jul;125:1544–1557.
26. Dijkhuizen RM, Ren J, Mandeville JB, Wu O, Ozdag FM, Moskowitz MA, et al. Functional magnetic resonance imaging of reorganization in rat brain after stroke. *Proc Natl Acad Sci USA* 2001; 98: 12766–12771.
27. Silvestrini M, Cupini LM, Placidi F, Diomedei M, Bernardi G. Bilateral hemispheric activation in the early recovery of motor function after stroke. *Stroke* 1998; 29: 1305–1310.
28. Marshall RS, Perera GM, Lazar RM, Krakauer JW, Constantine RC, DeLaPaz RL. Evolution of cortical activation during recovery from corticospinal tract infarction. *Stroke* 2000; 31: 656–661.
29. Mishkin M. Analogous neural models for tactual and visual learning. *Neuropsychologia* 1979; 17: 139–151.
30. Murray GM, Zhang HQ, Kaye AN, Sinnadurai T, Campbell DH, Rowe MJ. Parallel processing in rabbit first (SI) and second (SII) somatosensory cortical areas: effects of reversible inactivation by cooling of SI on responses in SII. *J Neurophysiol* 1992; 68: 703–710.
31. Mattingley JB, Husain M, Rorden C, Kennard C, Driver J. Motor role of human inferior parietal lobe revealed in unilateral neglect patients. *Nature* 1998; 392: 179–182.
32. Leiguarda RC, Marsden CD. Limb apraxias: higher-order disorders of sensorimotor integration. *Brain* 2000; 123: 860–879.
33. Frot M, Mauguier F. Timing and spatial distribution of somatosensory responses recorded in the upper bank of the sylvian fissure (SII area) in humans. *Cereb Cortex* 1999; 9: 8548–8563.
34. Thiel A, Schumacher B, Wienhard K, Gairing S, Kracht LW, Wagner R, et al. Direct demonstration of transcallosal disinhibition in language networks. *J Cereb Blood Flow Metab* 2006; 26: 1122–1127.
35. Boroojerdi B, Diefenbach K, Ferbert A. Transcallosal inhibition in cortical and subcortical cerebral vascular lesions. *J Neurol Sci* 1996; 144: 160–170.
36. Murase N, Duque J, Mazzocchio R, Cohen LG. Influence of inter-hemispheric interactions on motor function in chronic stroke. *Ann Neurol* 2004; 55: 400–409.
37. Alexander GE, Crutcher MD, DeLong MR. Basal ganglia-thalamocortical circuits: parallel substrates for motor, oculomotor, “prefrontal” and “limbic” functions. *Prog Brain Res* 1990; 85: 119–146.
38. Goldstein LB, Matchar DB, Hoff-Lindquist J, Samsa GP, Horner RD. VA Stroke Study: neurologist care is associated with increased testing but improved outcomes. *Neurology* 2003; 61: 792–796.