

CASE REPORT

PROSTHESIS TO ENABLE A PATIENT WITH ABOVE-ELBOW AMPUTATION TO RESUME HUNTING

Laurent THÉFENNE, PhD¹, Bénédicte GUÉRIN, OT¹, Arnaud JOUVION, MD¹, Hélène BISSERIEUX, MD¹, Bertrand TOURÉ², Janyce CANTU², Thomas TRAPPIER, MD¹, Maxime OBRECHT, MD and Gratiane DE BRIER, MD¹

¹Service de MPR-HIA Laveran, Marseille Cedex, France

²Etablissement Touré Couderc, Marseille Cedex, France

Background: Creating a custom prosthetic device is challenging. The requirements of the patient's life must be taken into consideration when manufacturing the device. After having met the requirements for an autonomous daily life, adjustments can be made for recreational activities.

Subject and methods: A 67-year-old patient with an above-elbow amputation following a hunting accident wanted to use a rifle to hunt again. We considered her desires, the short stump, and the constraints of the type of hunting and environment, bearing in mind the safety of the patient and other hunters.

Results and conclusion: An orthopaedic prosthetic system was developed to allow her to pick up the rifle, aim (sight), and shoot with recoil. The 2 rifle supports are fixed onto a bolero vest. The supports are made of carbon fibre, which is lightweight, and the gun can be aimed between them. Appropriate safety was achieved. The efficiency depends on the patient. There are few publications regarding amputation cases of this type, in which the specification goals were precision and the ability to walk with the prosthesis. Multi-disciplinary collaboration enabled us to create a device that met the requirements of this case.

Key words: orthopaedic prosthesis; hunting; recreation; upper limb above-elbow amputation; firearms.

Accepted Nov 26, 2019; published Dec 17, 2019

JRM-CC 2019; 2: 1000025

Correspondence address: Théfenne Laurent, Service de MPR - HIA Laveran, Boulevard Laveran, CS 5004, 13013 Marseille Cedex, France. E-mail: laurentthefenne@orange.fr

LAY ABSTRACT

This case report describes a multidisciplinary collaboration (doctor, occupational therapist, orthopaedic technician and patient) to develop an ortho-prosthesis to enable the patient to resume her leisure activity, hunting, after having enabled her to regain autonomy in daily activities. The positive effect on the patient's psychological well-being is important and the result is very interesting.

The goal of an arm prosthesis is often to recreate the aesthetics and functional aspects of the amputated limb. One must therefore compensate for a lack of prehension, which can be complex. The need to compensate for a person's disability varies as a function of the patient's desires and the environment in which they developed. Therefore, in this case, a custom project was defined. This project was complicated because the patient had an above-elbow amputation.

It is not always possible to use the same prosthesis for all activities. For this patient, it was necessary to make several prostheses to meet various demands. The life project defined the device project. The multi-disciplinary team defined the therapeutic strategy by considering benefits and risks. The level of amputation is the main point in determining the possibilities of resuming physical activities that require upper limbs. Participation in an activity is useful in reducing inactivity, and has benefits for psychological well-being, but the varying needs of different sports and recreational activities create a mul-

titude of factors that influence the design, construction and use of a prosthesis.

This case report illustrates the original character of some requests to enable the resumption of a recreational activity. It describes the constraints related to resuming hunting for a patient with an above-elbow amputation. We describe here the method used to create a suitable prosthetic device, the results, and the difficulties encountered in resuming the use of firearms.

CASE REPORT

Following a hunting accident in December 2010, a 67-year-old woman, who is a retired farmer, underwent amputation at the upper quarter of the left humerus (**Fig. 1**). The patient is right-handed. Her main recreational activities include hunting, walking in the woods, and biking with her husband. She has 3 children and 2 grandchildren.

Initially, an aesthetic prosthesis was constructed in March 2011, which attached to the patient's chest with a strap. A myoelectric prosthesis, comprising a "sensor" hand and an Otto Bock© mechanical elbow, was constructed in May 2012. For 1.5 months the patient was monitored while operating the controls of the myoelectric prosthesis and integrating it into her daily life (**Fig. 2**). She was subsequently independent in most activities of daily living. She resumed driving, using a steering ball and a satellite on the steering wheel for commands (indicator, windscreen wipers). She used her myoelectric prosthesis for 3–4 h per day while cooking, cleaning and gardening. For the rest of the day the goal was strictly aesthetic. She did not want to resume biking. However, she had a strong desire to resume hunting.

After the initial phase of rehabilitation, the patient asked for a suitable solution to resume her favourite activity:

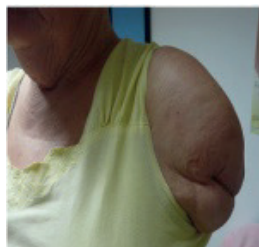


Fig. 1. Amputation.



Fig. 2. Using the myoelectric prosthesis during daily activity.

hunting with her husband, son, grandchildren and dog. She primarily wanted to hunt hares and thrushes in France.

METHODS

The constraints taken into consideration in planning the development of a suitable prosthesis related to the activity (hunting, using the rifle), the environment, the amputation, etc., as described in detail below.

Constraints related to hunting

Several constraints connected with hunting hares and thrushes were examined in order to best define the device (1, 2).

For hunting hares, one must be mobile and able to walk several km. The use of a rifle for this type of hunting can be broken down into several phases, as follows:

- cock the rifle;
- follow the target by sweeping rapidly (to match the speed of the hare);
- sight using standard devices on the rifle;
- the inclination and orientation of the weapon by orientation of the body and leg movement;
- shooting requires precision: ability to "release" a suitable pressure on the trigger without premature shooting;
- the arm must be held well so as not to deviate and to manage the rifle's recoil.

Hunting thrushes presents fewer constraints, because the person sits still when hunting. A support for the arm is sufficient (3).

Constraints related to using the rifle

- The patient was amputated on her left side. She shoulders and shoots with her right hand.
- The main goal of the prosthesis is to support the rifle before and during sighting and shooting.
- The solution should consider the horizontal position of the arm.
- In addition, the stock is relatively short with a very weak lever arm.
- The position of the body in flexion or extension varies the shooting angle.

Constraints related to the environment

- The user will be moving almost constantly, following dogs over several km.
- External constraints are humidity, dust, cold ($>5^{\circ}\text{C}$) and vibrations.
- The solution must therefore be as light as possible, not be an encumbrance, and must be balanced.

Constraints related to the amputation

- The amputation is short and above the elbow.
- It is important to focus on the dynamic forces on the prosthesis.

Other constraints

- Cost: the prosthesis is not reimbursed by social security. As the patient had been injured in a hunting accident, the prosthesis might be financed by the patient's insurance.

- Aesthetics: this criterion is not primary; above all, the prosthesis must be functional.

RESULTS

In order to limit the constraints and handling difficulties identified, the planned firearm was a light-weight rifle with a cartridge ejector.

Neither the aesthetic prosthesis nor the myoelectric one could be used as a support. The mechanical elbow can be fixed in any position, but maintaining it above horizontal for a long period of time with movement of the sight was impossible. On the other hand, a myoelectric actuator was not used, in order to limit the risk of untimely opening and closing of the hand.

As to the constraints related to the short residual member, after analysis of the main solutions described in the literature, none of which were helpful, and after discussion with other certified Prosthetic and Orthotics (CPOs), it was decided to create a new system.

A functional prosthesis with a folded elbow and a gutter-type end actuator for the rifle with an 8-strap chest fastener was not an option. The lack of force cannot generate anteflexion, abduction and adduction under the constraint of the weight of the rifle. This deficiency also prevented channelling the recoil.

The solution finally used was obtained after several phases of development, with the specifications and modifications related to field trials, with the participation of the patient and meeting technical requirements. The rifle is held at 4 places: the shoulder, the predominant hand, the support director linked to the residual limb, and a support positioned under the barrel. A system to guide the rifle avoids the need to displace the rifle laterally.

The prosthesis is therefore primarily a bolero, a plastron with braces, a holding support and a steering bar, with everything connected to a stiffening bar. It took approximately 2 months to reach this solution. The total cost was EUR 3,500.

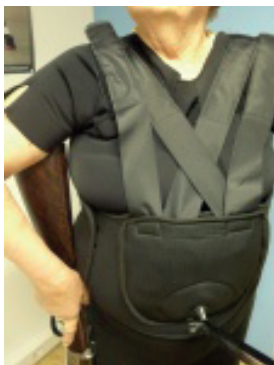


Fig. 3. Bolero and plastron (fixation socket on the bottom). The bolero distributes the load, which is fixed to the socket and the healthy side. The plastron, made of polyisoprene, breathable 3D fabric and a heat-moulded plate, is positioned on the abdomen, providing additional support for the rifle.

Bolero

The bolero (**Fig. 3**) is a vest sewn in one piece with a back opening and a Velcro closure. The tailoring was custom manufactured by Sober© in Marseilles, France. The bolero is made of 3-mm thick neoprene. The advantages of this material are that it does not tear, it is lightweight, it does not wear much, it can be deformed, and it easily adapts to the shapes. It has a good calorific ratio. The bolero is thin enough to be worn under a hunting vest. Its disadvantage is that it causes excessive perspiration.

The bolero does not limit abduction and flexion of the right arm. The left sleeve closes around the abdomen to support the residual limb and reduce the mechanical stresses of the socket on the short stump.

The bolero closes at the back, and requires the assistance of another person to put it on. The use of Velcro makes it easy to adjust and tighten as needed when hunting. The patient is always accompanied on her hunt; therefore, she does not need to put on the prosthesis on her own, but rapid and easy installation is desirable.

Plastron

A plastron (**Fig. 3**) was connected to the bolero. It provides for a controllable amplitude of 8 cm. Creation in 2 pieces was favoured to make it easy to lace up, transport, control, and lift. The plastron closes on the right side with Velcro. Fixing the support to hold the rifle is done using a kangaroo pouch and webbing, which fixes the set and distributes the weight of the rifle over the whole body.

The plastron distributes the constraint pressures related to the weight of the 2 supports and the rifle, and thus controls rotation of the rifle. It also includes an abdominal tray, thermo-formed from polyisoprene, padded with ventilated 3D fabric, which provides additional support for the rifle.

Socket and support bracket (Fig. 4)

The carbon fibre socket is an essential item that enables control of the rifle along all planes, assisted by the bolero and the plastron.

The support bracket is made of 2 aluminium rods that fit into one another. The lower part inserts at the bottom in the kangaroo pouch, using a knee. The fixation between the rods is performed by a tightening screw. This



Fig. 4. Holder bracket installed with the rifle. Tube made of pre-angled carbon fibre in flexion for the socket, needed to control the precision of the sight, assisted by the plastron.

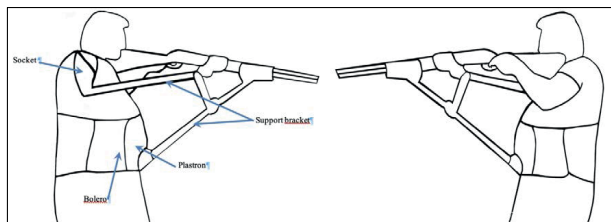


Fig. 5. Left- and right-side diagram. The bolero, which is fixed on the socket and on the healthy side, distributes the load. The plastron provides additional support for the rifle. The socket controls the precision of the aim, assisted by the plastron. Two support brackets; 1 proximal and 1 distal.

provides control of the length of the support, enabling the best angle to be set for different types of shooting (Fig. 5 and Fig. 6).

DISCUSSION

As for the current patient, most upper limb amputations are due to trauma (85% in the USA in 2011 (4), nearly 72% in an English study (5)). Soldiers are major victims of traumatic amputations due to conflict. Those amputated above the wrist are generally younger than our patient. Two primary programmes exist in the USA to improve the usefulness of prostheses in everyday life, as summarized by Gonzales Fernandes (6). There is a constant need to find solutions. In effect, nearly 35% of patients abandon their sophisticated prosthesis (5). This rate is even greater if the amputation is proximal. Problems are therefore more major and difficult to resolve if the amputation is above the elbow. Since there is no elbow articulation, the length of the residual member is a key factor in the adaptation and final success of a prosthesis (not too long to put on a mechanical or electrical elbow, but not too short in order to maintain the socket and transmit forces). It is also difficult to capture signals for myoelectric prostheses.

The level at which the current patient's arm was amputated therefore posed a number of problems for her device. With specialized multi-disciplinary management, the prosthesis for activities of daily living was relatively successful, as seen by her independence in many activities, and the fact that she uses it in a functional mode for several hours per day.

Participation in a sports activity contributes not only to physical well-being, but also psychological well-being (7). Depending on the type of sport, the prosthesis is not always sufficient, whether an upper or lower limb. A recreational activity as demanding as shooting or hunting is not possible with this type of prosthesis for above-elbow amputation. It is also not possible to rely only on the usual criteria described in the literature; one must innovate for the specific patient's project (1). Shooting in competition has been part of the Paralympics since 1976. Various stages have been studied, and were the basis for various prototypes (3, 8). However, such devices do not replace



Fig. 6. Sight with inclination of the trunk.

the human anatomy and do not meet the primitive goal of being aesthetic. They can be designed with a sporting performance goal. The small number of people with arm amputations, and the range of levels and different sports, do not enable development programmes to be set up, like those for people with a lower limb amputation.

The importance of the multi-disciplinary team, described by all the authors, was significant in supporting the analysis, construction, and assistance in use of the device in the current case. Shooting is an asymmetrical activity. It requires precision to make a shot (the prosthesis needs to be designed for the hand usually used to shoot, or the patient needs to modify their habits). It is therefore difficult to shoot precisely with a myoelectric prosthesis whatever the level of amputation. The risk of a sudden triggering, the need to feel the limit of the trigger and the trigger are difficulties to overcome.

A support can be used for the rifle in order to arm it and handle the recoil; this does not systematically require a prosthesis (3, 8). However, this solution is not very mobile, especially for static shooting (on a step or wheelchair). Hunting mobile game requires a certain amount of mobility, and one might need to walk for several km. These actions are complicated by an above-elbow amputation level. Very few solutions were found in the literature. This is another argument to support the surgical teams in making substantial efforts to save the elbow (9).

Use of the current prosthesis was a success: shooting can be performed in safe conditions (for others and for the patient). In case of danger, the rifle barrel can instantly be aimed downwards. Installation and removal of the rifle from the prosthesis can be done without assistance, and rapidly, also for safety reasons. The patient found shooting easy, as shown by her results in the shooting stand. She hunted her first hare in March 2013.

We searched for published data for soldiers whose upper limbs were amputated and who wanted to resume shooting. However, this was evidently a difficult problem, related to the resumption of their professional activities. In the French Army, amputation of an upper limb on the dominant side, whatever the level, is a disabling injury for shooting, and therefore prevents the soldier from



Fig. 7. Using the prosthetic device. (a) Testing the device at a shooting range; (b) hunting.

going on missions, primarily due to the disappearance of the fingers needed for the trigger. Adapting the stock, or completely changing it, is often the rule for proximal upper limb amputees (5). We did not find an effective solution in the literature.

Regarding administrative procedures to validate the prosthesis and obtain a hunting license, under French law there is no contraindication to resuming hunting, whatever the type of amputation. There is no medical validation committee. A medical certificate is required, however. Tests were therefore conducted in an ecological area before the first hunt. Tests at a shooting range validated the solution, enabling the patient to learn how to use the prosthesis and control the adjustments (**Fig. 7**).

The patient was able to resume hunting using this prosthesis (**Fig. 8**). The psychological impact was major, and the degree of subjective satisfaction was 80%.



Fig. 8. To the hunt!

Conclusion

Prosthetic advances exist for people with upper limb amputations, and sports and recreation can open the way to improvements in prosthetic technology.

In the case described here, sharing ideas, confronting difficulties, and the technical skills of a team comprised of the patient, physical therapists, prosthetists and physicians made it possible to deliver a result that was validated by the first shooting range tests, and for the patient to resume hunting.

With an open mind, a new attitude, an ability to understand, as well as patience and the willingness to experiment and develop, a better future for disabled people in sports and recreation can be achieved.

REFERENCES

1. Batavia AI, Hammer GS. Toward the development of consumer-based criteria for the evaluation of assistive devices. *J Rehabil Res Dev* 1990; 27: 425–436.
2. Bertin L. Tout savoir sur le tir de chasse techniques classiques et nouvelles méthodes. 2005. Larivière.
3. Radocy B. Upper-extremity prosthetics: Considerations and designs for sports and recreation. *Clinical Prosthetics & Orthotics* 1987; 11: 131–153.
4. Resnik L, Meucci MR, Lieberman-Klinger S, Fantini C, Kely DL, Disla R, et al. Advanced upper limb prosthetic devices: implications for upper limb prosthetic rehabilitation. *Arch Phys Med Rehabil* 2012; 93: 710–717.
5. Datta D, Selvarajah K, Davey N. Functional outcome of patients with proximal upper limb deficiency – acquired and congenital. *Clin Rehabil* 2004; 18: 172–177.
6. González-Fernández M. Development of upper limb prostheses: current progress and areas for growth. *Arch Phys Med Rehabil* 2014; 95: 1013–1014.
7. Bragaru M, Dekker R, Geertzen JHB, Dijkstra PU. Amputees and sports: a systematic review. *Sports Med* 2011; 41: 721–740.
8. Rubin G, Fleiss D. Devices to enable persons with amputation to participate in sports. *Arch Phys Med Rehabil* 1983; 64: 37–40.
9. Tintle LSM, Baechler LMF, Nanos CGP, Forsberg LJA, Potter MBK. Traumatic and trauma-related amputations: part ii: upper extremity and future directions. *J Bone Jt Surg-Am* 2010; 92: 2934–2945.