

CASE REPORT

A CASE OF DORSAL SCAPULAR NEUROPATHY IN A YOUNG AMATEUR BOXER

Tony FARRELL, MRCS, BSc, MB, Bch BAO, Muiris KENNEDY, FRSC, MB, Bch and Conor O'BRIEN, FRCPI, MB, Bch, MSC
Orthopaedic Department, Midlands Regional Hospital, Tullamore, Ireland

Neuropathies of the muscles surrounding the shoulder joint are a well-documented cause of pain and weakness in sports people. Repetitive or excessive traction on the nerve supplying the affected muscle is believed to be the primary mechanism. We describe a case of this phenomenon in a young amateur boxer which has never been described in the literature previously. We document our hypothesis on the mechanism of injury as well as a successful treatment strategy we employed. This paper is designed to highlight shoulder pain with associated winging of the scapula should make one wary of a dorsal scapular neuropathy particularly in a sports person who utilises repetitive forceful actions.

Key words: neuropathy; boxer; rehabilitation; shoulder; sport

Accepted Jun 15, 2018; Published Sep 20, 2018.

JRM-CC 2018; 1: 1000002

Correspondence address: Tony Farrell, From the Orthopaedic Department, Midlands Regional Hospital, Tullamore, Ireland. E-mail: Anthony.farrell@ucdconnect.ie

Neuropathies of the muscles surrounding the shoulder joint are a well-documented cause of pain and weakness in sports people (1–3). Repetitive or excessive traction on the nerve supplying the affected muscle is thought to be the primary mechanism (4–6). Although this phenomenon is usually confined to the suprascapular nerve, in severe cases, the rhomboid muscles can also be affected, indicating involvement of the dorsal scapular nerve (7). We report here a case of dorsal scapular neuropathy in a young amateur boxer, which, to our knowledge, has not been reported previously in a boxer.

CLINICAL CASE

A 29-year-old right-hand-dominant man presented to the clinic with a 4-year history of intermittent left scapular tip pain. He reported that the pain started during an intensive

LAY ABSTRACT

Continuous and repetitive stressful motion has been shown to damage nerves over a period of time. This is particularly common in sports that involve a lot of overhead activity such as baseball and volleyball. Continuous stretching of the nerve results in reduced signals sent to its target muscle. This will eventually cause the muscle to waste away and the patient will begin to experience pain and dysfunction. We describe a case of this phenomenon in a young amateur boxer. We detail the probable mechanism of this injury and steps that we took to remedy the problem. At the time of writing there is no other documented case of dorsal scapular neuropathy in this sporting population but it is something clinicians should bear in mind when dealing with athletes with repetitive, forceful shoulder movements.

boxing training session following use of the heavy bag. He was an experienced amateur boxer, having represented Ireland nationally in the sport, and had to rest for some weeks after the initial incident. However, upon returning to training, the pain would return after any strenuous exercise involving punching with the left hand. Specifically, he found that rotating his arm just prior to making contact with the heavy bag was the most exacerbating action.

Physical examination did not find any muscle wasting, and revealed only very minor winging of the left scapula. The patient had good active and passive range of motion in his left arm that was comparable to the uninjured limb. Palpation was negative for any abnormalities, but the patient reported some pain deep to the tip of the left scapula. Interestingly, there was an intermittent audible “clunk” from the scapula when the patient repeated the punching movement on the left side.

X-ray films of the left shoulder were grossly normal (Fig. 1). Magnetic resonance imaging (MRI) was contraindicated due to metal remnants in the patient’s eye. Routine blood work-up was normal.

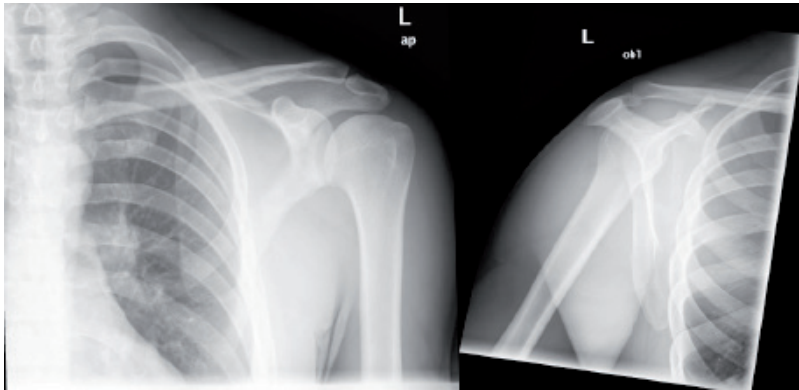


Fig. 1. Anteroposterior (AP) and lateral views of the left shoulder.

The dorsal scapular motor study of the rhomboid showed a normal distal latency of 3.65 ms, with a significant amplitude loss of 0.6 mV (normal > 10 mV). Motor studies of the axillary and supra-scapular nerves were within normal limits. Needle electromyography (EMG) to the rhomboid showed positive sharp waves and a reduced recruitment pattern, with large amplitude motor units recruiting at approximately 40 – 50% of normal. The needle EMG study was diagnostic for dorsal scapular nerve neuropathy.

Having identified the pathophysiology of the injury we elected to employ a non-operative treatment plan with intensive physiotherapy over a 3-month period, focusing on correcting the imbalance between agonist and antagonist muscle groups. After this period the patient reported resolution of his symptoms and, objectively, the winging of the scapula that was noted previously had completely resolved.

DISCUSSION

Neuropathies of the muscles surrounding the shoulder joint are a well-documented cause of pain and weakness in sports persons, particularly in sports that involve repetitive or forceful actions, e.g. volleyball and baseball (1–3, 8). To our knowledge there have been no reported cases of isolated dorsal scapular neuropathy in a boxer.

The dorsal scapular nerve arises from the anterior portion of cervical nerve C5. It commonly pierces the middle scalene muscle and continues deep to levator scapulae, where it then innervates the rhomboid muscles (**Fig. 2**) (9). Isolated dorsal scapular nerve injury is uncommon, with the mechanism believed to be injury to the scalene muscles (10). However, considering the mechanism in this case study, we propose a different mechanism of injury.

The serratus anterior is often colloquially known as the “boxer’s muscle”, as it is responsible for protraction of the scapula, i.e. pulling the scapula forward around the rib cage during a punching motion. If we consider that the rhomboid muscle works in direction opposition to the serratus anterior, it is easy to see how the nerve supplying the rhomboids could become stretched. A repetitive im-

balance between muscle groups could potentially lead to a dorsal scapular neuropathy similar to the mechanism thought to be responsible for supra-scapular nerve neuropathies observed in volleyball and baseball (1–3, 8).

It is unsurprising that the patient has made a substantial recovery following intensive physiotherapy and strengthening of the rhomboid muscle group over a period of 3 months. Although he is unlikely to compete at the level he was at 4 years ago he can now train and complete activities of daily living in the absence of pain or restriction.

Conclusion

Isolated dorsal scapular neuropathies are an uncommon injury. Shoulder pain with associated winging of the scapula should make one wary of a dorsal scapular neuropathy, particularly in a sports person who utilizes repetitive forceful actions. Neurophysiology studies may be the only diagnostic test that can aid in the diagnosis of this unusual condition. The primary treatment of choice is intensive physiotherapy, with a focus on balancing of agonist and antagonist muscle groups.

REFERENCES

1. Feretti A, Decarli A, Fontana M. Injury of the suprascapular nerve at spinoglenoid notch. The natural history of infraspinatus atrophy in volleyball players. *Am J Sports Med* 1998; 26: 759–763.
2. Holzgrafe M, Kukowski B, Eggert S. Prevalence of latent and manifest suprascapular neuropathy in high performance volleyball players. *Br J Sports Med* 1994; 28: 177–179.
3. Sandow MJ, Ilac J. Suprascapular nerve rotator cuff compression syndrome in volleyball players. *J Shoulder Elbow Surg* 1998; 7: 516–521.
4. Cummins CA, Messer TM, Nuber GW. Suprascapular nerve

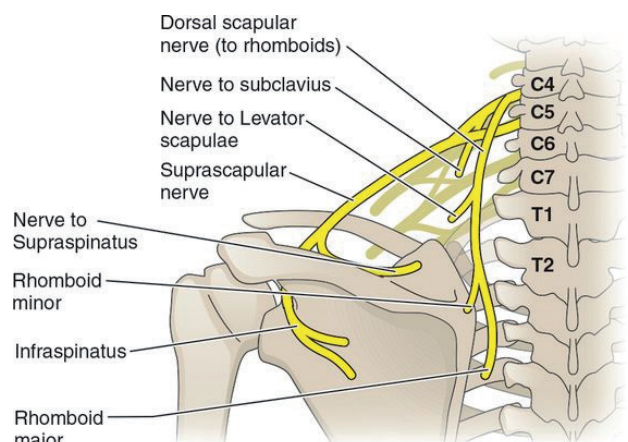


Fig. 2. Anatomical details of the involved nerves. Most common path of the dorsal scapular nerve and its branches.

- entrapment. *J Bone Joint Surg (Am)* 2000; 82: 415–424.
5. Callahan JD, Scully TB, Shapiro SA, Worth RM. Suprascapular nerve entrapment. A series of 27 cases. *J Neurosurg* 1991; 74: 893–896.
 6. Witvrouw E, Cools A, Lysens R, Cambier D, Vanderstraeten G, Victor J, et al. Suprascapular neuropathy in volleyball players. *Br J Sports Med* 2000; 34: 174–180.
 7. Ravindran M. Two cases of suprascapular neuropathy in a family. *Br J Sports Med* 2003; 37: 539–541.
 8. Cummins CA, Bowen M, Anderson K, Messer T. Suprascapular nerve entrapment at the spinoglenoid notch in a professional base ball pitcher. *Am J Sports Med* 1999; 27: 810–812.
 9. Moore K, Dalley A, Agur A. Clinically orientated anatomy, 6th edition. USA; Lippincott Williams & Wilkins: 2008.
 10. Akuthota V, Herring S. *Nerve and Vascular Injuries in Sports Medicine*. USA; Springer Science & Business Media: 2009.