

REHABILITATION OF AMPUTEES FOLLOWING MALIGNANT TUMOURS

Theodore Najenson and Michael Levy

Tel Aviv University School of Medicine, Loewenstein Rehabilitation Hospital, Raanana, Israel

The problem of malignant tumours in bone and soft tissue of the lower limbs is well known and has been discussed in several textbooks from the pathological and therapeutic point of view. However, from the point of view of rehabilitation this problem has received little attention, as pointed out by Freed (1).

Since this article deals with the rehabilitation of patients, we are primarily concerned here with the treatment of the malignant disease prior to rehabilitation. It is clear from the literature that surgical treatment is indicated. Conservative non-surgical treatment such as radiotherapy or chemotherapy are generally used as a palliative only, and in the majority of cases are used when surgical intervention is contraindicated, or because of the opposition of the patient to surgical operation involving the lower limb. Surgical treatment is sometimes also only palliative, a fact which makes ever more difficult the decision as to the nature of treatment, i.e. the choice between extensive bone resection and amputation, and if amputation, the level at which this should be performed. During the past few years, the works of Pack (3), Troup & Bickel (6), Pack & Miller (4), Phelan, Grace & Moore (5), Nilsson (2) have stressed the advantages which lie in high amputation such as hip desarticulation or hemipelvectomy. Our impression is that after this type of major operation, rehabilitation is less efficient, even if life expectancy is increased, and it is difficult to prove whether or not this is the case in growths affecting the limb below the hip joint, since these growths are uncommon and of different grades of malignancy.

During the 10 years that this department has been in existence, only 10 cases of amputation following malignant tumours in the lower limbs have been hospitalised for rehabilitation. This fi-

gure represents scarcely 4% of the total number of amputees admitted during this period.

All these 10 cases had been treated by conservative surgical methods and the results of this approach forms the basis of this presentation.

CASE REPORTS

Case 1

A 55-year-old weaver, married and the father of three children. Some 4 years before he was hospitalized, a malignant tumour of the chondrosarcoma type was diagnosed on the basis of biopsy, in the lower third of the right thigh. The patient refused to allow amputation on the grounds that as long as he could use the limb it was his duty to continue to work as long as possible, even though his refusal might shorten his life. The tumour continued to grow until the thigh reached a diameter of some 30 cm as opposed to 13 cm for the left side (Figs. 1 and 2). After 4 years the patient himself asked to be operated on, as he had now completed his life's work of bringing up his children. Amputation was performed above the growth and some 10 cm below the hip joint (Fig. 3). Histological examination confirmed the earlier diagnosis. About 1 month later, a prosthesis was fitted above the knee, with a pelvic belt and the patient learned to walk unaided. He was examined 30 months after his discharge, and it was learned that he had returned to his work on a fulltime basis, and that he uses the prosthesis throughout the entire day. No sign of metastases was found on subsequent check-up examinations.

Case 2

A 45-year-old clerk, married and the father of three children. Two years before his hospitalization, swelling appeared in the popliteal region of the left knee. The swelling continued to grow and limited the patient more and more in his walking. A biopsy examination was undertaken, and this revealed a malignant tumour of the synovial sarcoma variety. The leg was then amputated above the knee. There were no complications after the operation, and the patient was soon fitted with a prosthesis of the vacuum type, and on his release was completely independent. On the last follow-up, 36 months after the amputation, the patient was still independent, showed no signs of metastases and worked full time as a clerk.

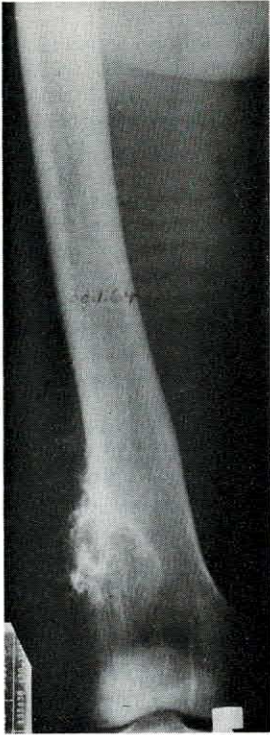


Fig. 1. AP view of right femur. Chondrosarcoma in the distal femur with marked soft tissue swelling. Calcifications within the soft tissue mass. 30.1.1964.

Case 3

A 74-year-old pensioner, married, and the father of two children. This patient has suffered from diabetes for the past 27 years, and also from intermittent claudication, stemming from peripheral vascular disturbances. Seven years before his last hospitalization, a sensitive growth, about the size of an olive, developed on the left calf. Histology did not reveal malignancy, although the tumour had grown rapidly within healthy cell tissue. The tumour continued to grow, however, within the next 13 months and resection was performed. This time the histological examination revealed a malignant tumour of the angiosarcoma type. After the removal of tumour, the patient was treated with a series of deep X-rays and for 3 years there was no recidive. One year before he was hospitalised, i.e. some 6 years after the process began, the tumour began again to develop rapidly, and it became necessary to amputate the left leg below the knee. The operation wound began to discharge as a result of vascular disturbances of the same leg, and the wound healed only after a fistula was excised.

After this, the patient was fitted with a standard prosthesis with a pelvic belt. On release he was independent and he remained independent for his ordinary day to day needs up to the last follow-up visit 26 months after the amputation. There were no signs of metastases.

Case 4

A 75-year-old widower and pensioner, and father of two married children. Seven years before the last hospitalization, the patient had been under treatment because of scattered skin growths, principally on the soles of both feet, but also in other places including his hips, thighs and trunk. Biopsy performed during one of his hospitalizations, revealed sarcoma of the Kaposi type. He was treated by a series of deep X-rays on the soles of the feet, but suppurating sores developed in the radiated areas and spread along the right hip. It then became necessary to amputate below the knee, quite far from the ulcers. The patient was fitted with a patellatendon-bearing (PTB) prosthesis, and was independent on discharge. He remained independent in his day to day activities when he was checked again at his last follow-up examination, 60 months after the operation.

Case 5

A 52-year-old construction worker, married and father of five children. Some 2 years before the last hospitalization he began to suffer increasing pain in the dorsal aspect of the right foot. X-ray examination revealed a circular osteolytic process in the cuboid bone. Biopsy disclosed chondrosarcoma. The patient refused to undergo amputation, and for lack of alternatives was treated by

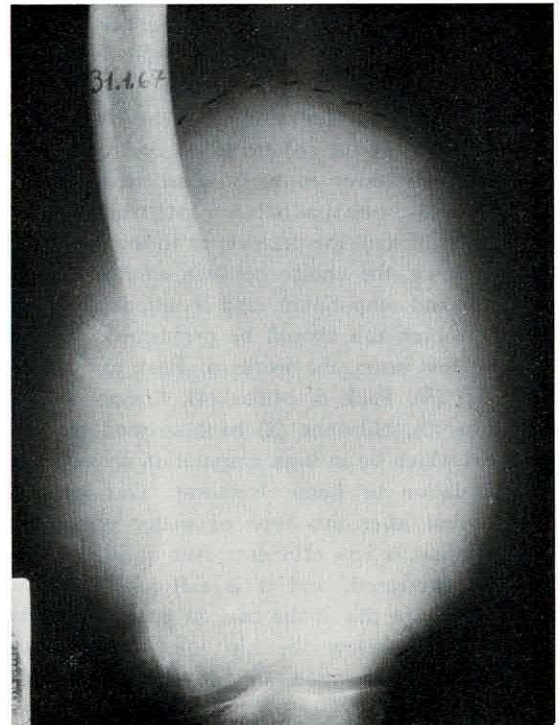


Fig. 2. AP view of right femur. The original site of the tumour appears destroyed. The soft tissue swelling and the calcifications within it had increased markedly. 31.1.1967.

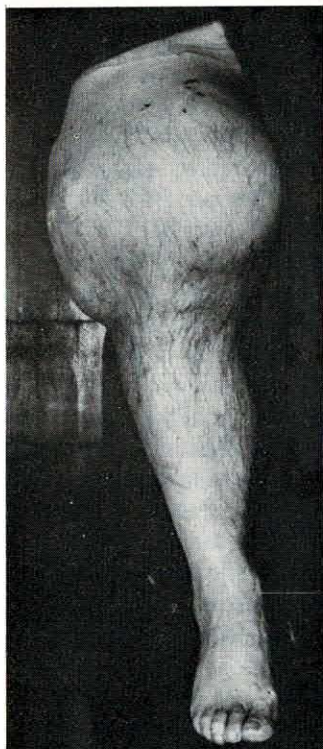


Fig. 3. After amputation of the right leg. A tumorous swelling in the distal two third of the right thigh.

a series of deep X-rays. He continued, however, to suffer from severe pain. About 1 year later, he was hospitalized again, because of swelling, with fistula in the biopsy region, accompanied by most severe pain. Amputation was carried out below the knee and revealed chondrosarcoma which had invaded part of the metatarsal bones. The patient was fitted with a prosthesis of the PTB type, and when discharged he was completely independent. He returned to work as a construction worker, on a full-time basis, but in a job suited to his condition. He still remained in this job 1 year after the operation, at the time of the last follow-up examination.

Case 6

A 46-year-old agricultural labourer and father of six. Seven years before his last hospitalization a painless white lump appeared on his right hip. Biopsy was not performed until 2 years after the appearance of the lump; it revealed a malignant tumour of the fibrosarcoma variety. In view of the patient's opposition, only a local operation was performed, together with deep X-ray treatment.

For 4 years no recidive was observed in the region of the operation. Five months before his last hospitalization, he received a blow in this region and the wound bled very severely. A necrotic sore developed which spread very fast and penetrated very deeply. It was clear that recidive was present. The leg was amputated above the knee, and the patient was fitted with a prosthesis. On his discharge he was independent and he continued to work at some agricultural jobs. He died from metastases 2 years after the operation.

Case 7

A 44-year-old accountant, married and father of two children. It is known from the case history that from his childhood the patient had a pale brown macula on the skin of the dorsal aspect of his foot. This macula did not change for many years. Two years before his hospitalization, the colour of the macula changed to black and, by degree, ulceration appeared in the plantar and ankle regions. At the same time enlarged lymph glands were palpated in the inguinal region. A chest X-ray revealed a finding which was suspected of being metastases, in the left mediastinum. Histological examination of the biopsy revealed a tumour of the malignant melanoma variety. The leg was amputated above the knee despite the existence of metastases, as the patient was confined to bed because of ulcerations. After the operation, the patient was discharged with a standard prosthesis. He was entirely independent and even returned to his work for some time. He used the prosthesis almost up to the time of his death. He died from metastases 30 months after the operation.

Case 8

A 48-year-old housewife and mother of three children. A month before her last hospitalisation she complained of pain in the region of the right thigh. Within a month she was hospitalised as an emergency case as a result of

Table I. Patients who underwent amputation as a result of malignant tumour and are still alive

Case no.	Name	Age	Sex	Type of tumour	Side	Time elapsed between clinical appearance & amputation (months)	Level of amputation	Time between amputation & last examination (months)	Time between clinical appearance & last examination (months)
1	S. A.	55	♂	Chondrosarcoma	R	48	a.k.	29	77
2	S. T.	45	♂	Synovial sarcoma	L	24	a.k.	36	60
3	I. F.	74	♂	Angiosarcoma	L	84	a.k.	26	110
4	A. B.	75	♂	Kaposi sarcoma	R	84	b.k.	60	144
5	O. S.	52	♂	Chondrosarcoma	R	24	b.k.	12	36

Table II. *Patients who underwent amputation as a result of malignant tumor and died at home after rehabilitation therapy*

Case no.	Name	Age	Sex	Type of tumour	Side	Time elapsed between clinical appearance & amputation (months)	Level of amputation	Time between amputation & death (months)	Time between clinical appearance & death (months)
6	E. J.	43	♂	Fibrosarcoma	R	84	a.k.	24	108
7	H. K.	44	♂	Melanosarcoma	R	24	a.k.	30	54
8	T. T.	48	♀	Chondrosarcoma	L	4	a.k.	6	10
9	L. A.	47	♀	Leiomyosarcoma	R	12	a.k.	9	21
10	I. G.	28	♂	Fibrosarcoma	R	7	a.k.	12	19

a pathological supra-condylary fracture of the left femur. A biopsy revealed a malignant growth of the chondrosarcoma variety. For 3 months the patient refused to undergo amputation, and for lack of an alternative was treated with cobalt rays. The tumour continued to spread along the femur in an upward direction and penetrated the soft cell tissues. In this condition the patient agreed to amputation of the leg, which was performed on the upper third of the thigh. A prosthesis was fitted, and the patient was independent on discharge. She preserved her independence until she died from metastases some 6 months later.

Case 9

A 47-year-old housewife and mother of two children. Some 10 months before she was hospitalized, a small painless growth, the size of a bean, appeared on the dorsal aspect of the right foot at the base of the second and third toes in the subcutaneous cell tissues. The growth did not change its shape and only after a few months did it continue to grow. Ten months after the appearance of the growth a biopsy was performed, which indicated a malignant tumour of the leiomyosarcoma type. The right leg was amputated above the knee and at the same time extensive resection of the inguinal region was performed. The histo-pathological examination of the glands did not reveal pathology. A prosthesis was fitted, and on discharge the patient was independent. She continued to perform her normal household tasks until 1 month before her death from metastases of the lungs.

Case 10

A 28-year-old unmarried clerk. Seven months before he was hospitalized, he complained of pain in the right knee, particularly when walking. X-rays revealed an osteolytic process in the inner right lateral condyle. The biopsy disclosed a malignant tumour of the fibrosarcoma, purely differentiated type. The leg was amputated at the middle third of the thigh, and shortly after this the patient was fitted with a prosthesis. He was completely independent on discharge. He returned to his job and remained at work almost until his death from metastases one year after amputation.

DISCUSSION

It is difficult to compare the rehabilitation results in follow-ups of amputees after malignant tumours, since very few works have been published in this field. Similarly, comparison between the different studies is difficult, as the case material (i.e. histo-pathological diagnosis of each tumour) differs in each study. In the group of ten patients presented here, there are from the histo-pathological point of view seven different types of growths: three patients with chondrosarcoma, two with fibrosarcoma and five other patients each of whom was stricken by a different type of growth (Tables I and II).

Only five of the ten patients in this series were still alive at the time of the last follow-up. The average age of the whole group was about 51 years, but the average age of those who died was 42 years, and of those who are still alive is 60 years. There were 8 men and 2 women patients, 5 of the men are still alive. The length of time which elapsed between the appearance of the first clinical symptoms and the death of the 5 patients (see Table II), varied between 10 and 108 months, with an average of 42 months. On the other hand, in the group still alive the length of time which elapsed between the appearance of the first clinical symptoms and up to the time of the last follow-up, varied between 36 and 144 months, with an average of 85 months (see Table I).

There is, of course, no possibility of drawing conclusions as to the life expectancy and surgical success in regard to these patients on the basis of this series. As mentioned in the case reports, the region of the amputation was in each case very close above the damaged region, and not one of

these patients underwent a radical operation, such as disarticulation or hemipelvectomy. It is worthwhile here to quote Pack. Pack (3) warns against criticism of the effectiveness of the radical operation on the basis that it is performed more as a palliative than as full curative treatment of the illness. In his words: "... one should not be critical in evaluating the curability achieved by these operations. Many of the amputations were done with the original and sole intent of palliation. Their value, therefore, cannot be measured by their rate of cure alone. By definition, palliation does not mean that the patient should live longer and suffer more, but rather that the remaining months and years of life should be spent in comfortable living with lessened disability..." We would concur with this approach, and as regards comfortable living, it is worth emphasising that each of the patients in this series was fitted with a prosthesis, and each of them used it until just before the death, or up to the time of the last follow-up.

There is no need to dwell on the well-known subject of the difficulties with which we are faced when having to fit a prosthesis to amputees after disarticulation or hemipelvectomy; even if one is successful in fitting the prosthesis, it is seldom truly useful. It is, on the other hand, very easy to fit a prosthesis when the amputation is lower and there is then no question as to its usefulness.

The authors who recommend high amputation base their operation instructions on two main factors:

(a) If the tumour is very high on the limb, and even penetrates to the hip area, the major operation is unavoidable.

(b) The possibility of attaining a complete cure of the tumour by a major operation. In regard to this indication there would appear to be room for doubt. There is no assurance whatever as to the prolongation of life, whereas the chance of the patient for full rehabilitation after a radical operation are in grave doubt.

The common ground of the 10 patients in this series is that the tumour disturbed their locomotor activity; as long as it did not disturb them they refused to agree to an operation. The amputation itself was performed very close to and just above the site of the tumour, in healthy cell tissue. The operation scar healed without complications and without recidive (if we discount case 3 where the

vascular disease caused delayed healing of the operation sore). As a result of this it was possible to fit vacuum or standard prostheses within a short time, to the 8 patients with amputations above the knee, and patellar-tendon-bearing type prosthesis to the remaining two.

With the aid of the prostheses, the patients were quickly rehabilitated and became independent in their everyday living; even including patient 7 who was already suffering from metastases before the amputation. The 5 patients who died, continued to use their prostheses up to a short time before their death. The 5 patients who are still alive and under supervision are leading "normal lives"; the three patients who are of work age are still working in their jobs and the two patients aged 74 and 75 enjoy independent lives.

The question of disarticulation was raised in regard to case 1 in view of the height of the tumour—as may be seen on the photograph. However, it was finally decided to attempt a lower amputation on the border of the growth, in order that a stump would be left for the fitting of a prosthesis.

CONCLUSION

There is no criterion for life expectancy in patients who suffer from malignant tumours in the lower limbs, nor is it clear whether the amputation of the leg as a palliative treatment is better than other methods of treatment, and there is no proof that radical amputation of the leg in tumours below the hip joints is really better and more of a safeguard than normal amputation through healthy cell tissues close above the growth.

Rehabilitation of the patient is frequently the main object of the treatment; thus, in many cases conservative amputation which allows for use of a conventional prosthesis is the type of treatment indicated.

SUMMARY

This study covers 10 cases of amputees who underwent amputation—because of malignant tumours—above the growth and through normal tissues. All of them were rehabilitated and were able to use conventional prostheses. Five patients are still alive and independent, and the other five also enjoyed normal lives until a short time before death.

REFERENCES

1. Freed, M. M. & Chrette, E. E.: Rehabilitation after amputation of the lower extremity for malignancy. *Arch Phys Med and Rehab* 45: 564, 1964.
2. Nilsson, U.: Radical amputation for malignant tumours of the extremities. *Acta Chir Scand* 129: 150, 1965.
3. Pack, G. T.: Major exarticulation for malignant neoplasms of the extremities. *J Bone Joint Surg* 38 A: 249, 1956.
4. Pack, G. T. & Miller, T. R.: Exarticulation of the innominate bone and corresponding lower extremity for primary and metastatic cancer. *J Bone Joint Surg* 46 A: 91, 1964.
5. Phelan, J. T., Grace, J. T. & Moore, G. E.: Hemipelvectomy for management of soft tissue tumours of the lower extremity. *Amer J Surg* 107: 1964.
6. Troup, J. B. & Bickel, W. H.: Malignant disease of the extremities treated by exarticulation. *J Bone Joint Surg* 42 A: 1041, 1960.

Key words: Amputees, neoplasm, orthopaedics, prosthesis, rehabilitation

Address for reprints:

Dr Th. Najenson, Med. Director, Loewenstein Hospital
Tel-Aviv University Medical School
Raanana, Israel