

CASE REPORT

CONTRA-LESIONAL SOMATOSENSORY CORTEX ACTIVITY AND SOMATOSENSORY RECOVERY IN TWO STROKE PATIENTS

Sung Ho Jang, MD

From the Department of Physical Medicine and Rehabilitation, College of Medicine, Yeungnam University, Daemyungdong, Namku, Taegu, Republic of Korea

Objective: We describe here 2 patients after stroke who showed activation of the contra-lesional somatosensory cortex without activation of the ipsi-lesional somatosensory cortex during proprioceptive input on the affected hand.

Case description: One patient with intracerebral haemorrhage (a 52-year-old man), 1 patient with middle cerebral artery infarct (a 54-year-old man), and 8 control subjects were recruited. The subscale for kinaesthetic sensation (full mark: 24) of the Nottingham Sensory Assessment improved from 2 points (patient 1 and 2; onset) to 8 points (patient 1) and 12 points (patient 2) at 6 months after onset. Functional magnetic resonance imaging was conducted at 6 months after onset using a 1.5-T Philips MR scanner. Passive movements were performed at the metacarpophalangeal joint.

Results: On functional magnetic resonance imaging the contra-lesional (left) primary somatosensory cortex and posterior parietal cortex were activated during passive movements of either hand, which was not observed in control subjects.

Conclusion: The activation of only the contra-lesional somatosensory cortex during passive hand movements in these patients suggests the involvement of this area in somatosensory processing for passive movements after stroke. This area appeared to contribute to recovery of proprioceptive function of the affected hands after stroke.

Key words: functional MRI; stroke; somatosensory recovery; intracerebral haemorrhage; proprioception.

J Rehabil Med 2011; 43: 268–270

Correspondence address: Sung Ho Jang, Department of Physical Medicine and Rehabilitation, College of Medicine, Yeungnam University 317-1, Daemyungdong, Namku, Taegu, 705-717, Republic of Korea. E-mail: strokerehab@hanmail.net, belado@med.yu.ac.kr

Submitted July 12, 2010; accepted October 21, 2010

INTRODUCTION

Somatosensory feedback is necessary for the execution of exact movements; therefore, somatosensory function is important for patients after stroke, because its dysfunction can lead to functional impairment (1–3). In addition, the incidence of somatosensory dysfunction is high in patients after stroke, at up to 65% (4).

Because it can provide a basis for the establishment of scientific rehabilitation strategies, detailed information on

the recovery mechanism of impaired function is necessary for stroke rehabilitation. Several mechanisms have been suggested for somatosensory recovery following stroke. These include recovery of damaged somatosensory pathways; peri-lesional reorganization; contribution of the unaffected somatosensory cortex, secondary somatosensory cortex, or thalamus (5–13). A few studies have reported on the contribution of the unaffected somatosensory cortex in patients after stroke (9, 10, 13); however, little is known about this recovery mechanism.

We describe here 2 patients after stroke who showed activation of the contra-lesional somatosensory cortex without activation of the ipsi-lesional somatosensory cortex during a proprioceptive input on the affected hand.

METHODS

Two patients and 8 right-handed control subjects (8 men, mean age 38 years, age range 27–52 years) with no history of neurological disease participated in this study. All subjects provided signed, informed consent prior to the commencement of the study, and our institutional review board approved the study protocol.

Patient 1 was a 52-year-old, right-handed man who underwent Cosman-Roberts-Wells (CRW)-guided stereotactic drainage of a spontaneous haematoma in the right frontoparietal lobe in the department of neurosurgery at a university hospital. T2-weighted magnetic resonance (MR) images, which were taken at 6 months after onset, showed an encephalomalactic lesion of the right corona radiata and basal ganglia (Fig. 1A). Patient 2 was a 54-year-old, right-handed man who underwent conservative management for a right middle cerebral artery territory (MCA) infarct. T2-weighted MR (6 months after onset) revealed an encephalomalactic lesion in the left MCA territory. The motor weakness of the affected extremities in patient 1 and 2 was severe; therefore, these patients could walk on even ground with non-functional hands. The subscale for kinaesthetic sensation (full mark: 24) of the Nottingham Sensory Assessment (NSA) was used for determination of somatosensory function. The reliability and validity of the NSA are well-established (14). At 6 months after onset, the kinaesthetic sensation score improved from 2 points (patient 1 and 2; onset) to 8 points (patient 1) and 12 points (patient 2).

Functional magnetic resonance imaging

Blood oxygenation level-dependent (BOLD) functional magnetic resonance imaging (fMRI) measurement, which employs the Echo Planar Imaging (EPI) technique, was performed using a 1.5-T Philips Gyroscan Intera (Hoffman-LaRoche, Ltd, Best, the Netherlands) with a standard head coil. EPI BOLD images were acquired over the same 20 axial sections, producing a total of 1200 images for each subject. Imaging parameters consisted of repetition time/echo time ratio = 2 s/60 ms, field of view = 210 mm, matrix size = 64 × 64, and slice thickness = 5 mm. Subjects were examined

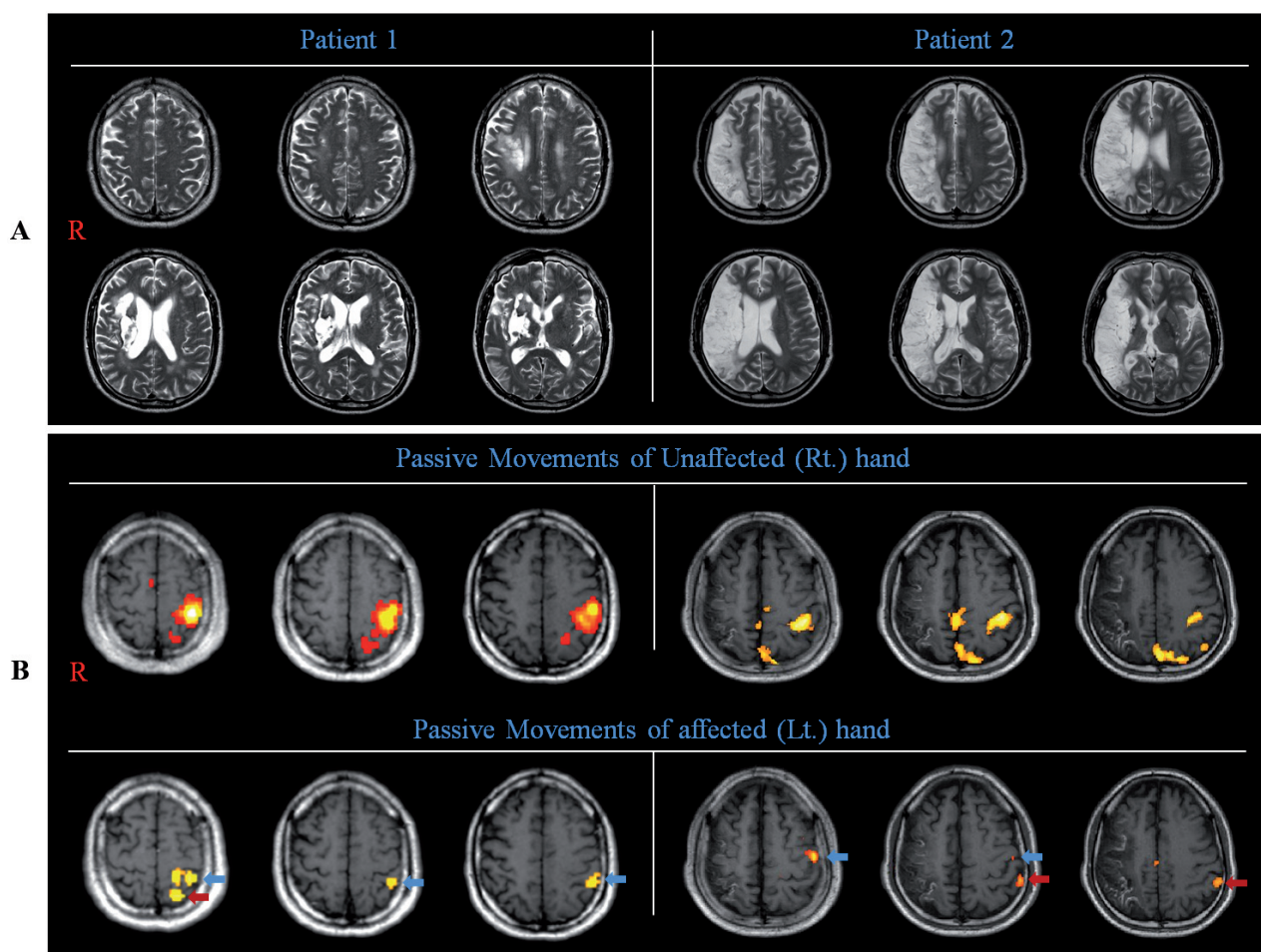


Fig. 1. (A) T2-weighted images show a leukomalactic lesion in the right coronal radiata and basal ganglia (patient 1) and a right middle cerebral artery territory infarct (patient 2). (B) Results of functional magnetic resonance imaging. The left primary sensorimotor cortex (blue arrow) and posterior parietal cortex (red arrow) were found to be activated during passive movement of either hand.

while in a supine position with eyes closed, and were firmly secured with the forearm pronated. For proprioceptive input, a specially equipped apparatus was used to limit flexion to more than 80° at the metacarpophalangeal joint. Passive movements (flexion-extension) were performed at the metacarpophalangeal joint using a block paradigm (20 s control, 20 s stimulation: 3 cycles) with a frequency of 1 Hz. fMRI was conducted at 6 months after onset.

Data processing

All functional images were realigned, co-registered, normalized, smoothed, and statistically analysed using SPM-2 software (Wellcome Department of Cognitive Neurology, London, UK). Differences in brain activation between the 3 tasks were compared by random-effect group analysis. Results were thresholded at uncorrected $p < 0.001$, and were reported for clusters larger than 5 voxels. Regions of interest included cortical regions known for their contribution to somatosensory processing: the primary sensori-motor cortex, SM1 (Brodmann's area (BA) 4, 1, 2, 3) and posterior parietal cortex (PPC) (BA 5, 7, 39, 40) (5, 7, 8, 13).

RESULTS

The fMRI results for both patients showed activation of the contra-lesional (left) SM1 and PPC during passive movement of either hand (Fig. 1B). By contrast, single subject analysis in

control subjects revealed the contralateral SM1 activation during passive movement of all hands, with additional activation in the ipsilateral SM1 by 1 hand movement (7.3%). As for the PPC, the contralateral PPC was found to be activated during passive movement by 14 (87.5%) of 16 hands, and the bilateral PPC was observed during passive movement of 1 hand (7.3%).

DISCUSSION

We describe here 2 patients who showed activation of the contra-lesional somatosensory cortex by a proprioceptive input on the affected side. In terms of kinaesthetic sensation of the NSA at stroke onset, these patients showed a severe deficit, and then showed partial recovery over a period of 6 months. This indicates that some portion of the cortical area was responsible for proprioceptive recovery of the affected side. However, on fMRI, only the contra-lesional (left) somatosensory cortex (primary somatosensory cortex, posterior parietal cortex) was activated during a proprioceptive input on the affected (left) hand. However, there were no control subjects to demonstrate activation of only the ipsilateral somatosensory cortex without activation of the contralateral somatosensory cortex. Therefore,

in these patients, the activated contra-lesional somatosensory cortex appeared to be responsible for proprioceptive function of the affected hand. This area appeared to contribute to recovery of proprioceptive function of the affected hands.

A few studies have demonstrated the contribution of the contra-lesional somatosensory cortex to somatosensory recovery after brain injury (9, 10, 13). Using positron emission tomography, Weder et al. (13) reported on 5 chronic patients with thalamic or basal ganglia infarct who showed activation of the bilateral sensorimotor cortex by performance of the somatosensory discrimination task with the affected hand (13). Subsequently, using magnetoencephalography, Rossini et al. (9, 10) demonstrated that the contra-lesional hemisphere, along with the ipsi-lesional hemisphere, contributed to somatosensory recovery in patients after stroke (9, 10). However, to the best of our knowledge, this is the first study to demonstrate the unique contribution of the contra-lesional somatosensory cortex.

In terms of motor function, the contribution of the contra-lesional cortex in recovery following stroke has been well demonstrated (15). In terms of motor recovery, poor motor function is a clinical characteristic of recovery by the contra-lesional cortex (15). Likewise, in the current study, patients showed poor somatosensory function, as much as below half that of normal adults (patient 1: 33%, patient 2: 50%). We think that this poor somatosensory function is associated with recovery mechanisms, such as motor recovery mechanisms; this result was compatible with the results of Weder's study (13).

In conclusion, we describe here 2 patients after stroke who showed activation of only the contra-lesional somatosensory cortex, resulting from a proprioceptive input on the affected hand. In terms of somatosensory recovery and rehabilitation of patients after stroke, this observation has important implications. However, because it is a case report, this study is limited. Another limitation of this study is the fact that we could not present fMRI data from the patient at an early stage. Further complementary studies involving larger case numbers and using follow-up fMRI study are warranted.

ACKNOWLEDGEMENT

This work was supported by National Research Foundation of Korea Grant funded by the Korean Government (KRF-2008-314-E00173).

REFERENCES

1. Binkofski F, Seitz RJ, Arnold S, Classen J, Benecke R, Freund HJ. Thalamic metabolism and corticospinal tract integrity determine motor recovery in stroke. *Ann Neurol* 1996; 39: 460–470.
2. Cheung VC, d'Avella A, Tresch MC, Bizzi E. Central and sensory contributions to the activation and organization of muscle synergies during natural motor behaviors. *J Neurosci* 2005; 25: 6419–6434.
3. Van Buskirk C, Webster D. Prognostic value of sensory defect in rehabilitation of hemiplegics. *Neurology* 1955; 5: 407–411.
4. Kim JS. Sensory abnormality. In: Bogousslavsky J, Caplan L, editors. *Stroke syndromes*. New York: Cambridge University Press; 2001, p. 34–47.
5. Cramer SC, Moore CI, Finklestein SP, Rosen BR. A pilot study of somatotopic mapping after cortical infarct. *Stroke* 2000; 31: 668–671.
6. Dechaumont-Palacin S, Marque P, De Boissezon X, Castel-Lacanal E, Carel C, Berry I, et al. Neural correlates of proprioceptive integration in the contralesional hemisphere of very impaired patients shortly after a subcortical stroke: an fMRI study. *Neurorehabil Neural Repair* 2008; 22: 154–165.
7. Forss N, Hietanen M, Salonen O, Hari R. Modified activation of somatosensory cortical network in patients with right-hemisphere stroke. *Brain* 1999; 122: 1889–1899.
8. Jang SH, Ahn SH, Lee J, Cho YW, Son SM. Cortical reorganization of sensori-motor function in a patient with cortical infarct. *NeuroRehabilitation* 2010; 26: 163–166.
9. Rossini PM, Tecchio F, Pizzella V, Lupoi D, Cassetta E, Pasqualetti P. Interhemispheric differences of sensory hand areas after monohemispheric stroke: MEG/MRI integrative study. *Neuroimage* 2001; 14: 474–485.
10. Rossini PM, Tecchio F, Pizzella V, Lupoi D, Cassetta E, Pasqualetti P, et al. On the reorganization of sensory hand areas after monohemispheric lesion: a functional (MEG)/anatomical (MRI) integrative study. *Brain Res* 1998; 782: 153–166.
11. Staines WR, Black SE, Graham SJ, McIlroy WE. Somatosensory gating and recovery from stroke involving the thalamus. *Stroke* 2002; 33: 2642–2651.
12. Thiel A, Aleksic B, Klein J, Rudolf J, Heiss WD. Changes in proprioceptive systems activity during recovery from post-stroke hemiparesis. *J Rehabil Med* 2007; 39: 520–525.
13. Weder B, Knorr U, Herzog H, Nebeling B, Kleinschmidt A, Huang Y, et al. Tactile exploration of shape after subcortical ischaemic infarction studied with PET. *Brain* 1994; 117: 593–605.
14. Lincoln NB, Jackson JM, Adams SA. Reliability and revision of the Nottingham Sensory Assessment for Stroke Patients. *Physiotherapy* 1998; 84: 358–365.
15. Jang SH. A review of the ipsilateral motor pathway as a recovery mechanism in patients with stroke. *NeuroRehabilitation* 2009; 24: 315–320.