

ORIGINAL REPORT

PHANTOM LIMB PAIN RELIEF BY CONTRALATERAL MYOFASCIAL INJECTION WITH LOCAL ANAESTHETIC IN A PLACEBO-CONTROLLED STUDY: PRELIMINARY RESULTS

Roberto Casale, MD¹, Francesco Ceccherelli, MD², Alaa Abd Elaziz Mohamed Labeeb, MD, PhD^{1,3} and Gabriele E. M. Biella, MD, PhD⁴

From the ¹Department of Clinical Neurophysiology and Pain Rehabilitation Unit, "Salvatore Maugeri" Foundation, IRCCS Montescano, Pavia, ²Department of Pharmacology and Anesthesiology, Anesthesiology Unit, University of Padova, Padova, Italy, ³Department of Physical Medicine, Rheumatology and Rehabilitation Unit, Menoufyia University, Menoufyia, Egypt and ⁴Institute of Bioimaging & Molecular Physiology, IBFM, National Research Council, Segrate, Milan, Italy

Objective: To ascertain the existence of contralateral painful muscle areas mirroring phantom pain and to evaluate the short-term effects of anaesthetic vs saline, injected contralaterally to control phantom and phantom limb pain.

Design: Double-blinded cross-over study.

Setting: Inpatients; rehabilitation institute.

Participants: Eight lower limb amputees with phantom limb pain in the past 6 months.

Interventions: Either 1 ml of 0.25% bupivacaine or 0.9% saline injected alternately in each point with a 28-gauge needle, with 72 h between injections.

Main outcome measure: Phantom sensation modification and the intensity of phantom limb pain (visual analogue scale) before and after injections.

Results: Although present, painful muscle areas in the healthy limb do not mirror the topographical distribution of phantom limb pain. Sixty minutes after the injection, a statistically significant greater relief of phantom limb pain was observed after using local anaesthetic than when using saline injection ($p=0.003$). Bupivacaine consistently reduced/abolished the phantom sensation in 6 out of 8 patients. These effects on phantom sensation were not observed after saline injections.

Conclusion: Contralateral injections of 1 ml 0.25% bupivacaine in myofascial hyperalgesic areas attenuated phantom limb pain and affected phantom limb sensation. The clinical importance of this treatment method requires further investigation.

Key words: phantom limb pain, contralateral treatment, bupivacaine, mirror pain.

J Rehabil Med 2009; 41: 418–422

Correspondence address: Roberto Casale, Department of Clinical Neurophysiology & Pain Rehabilitation Unit, "Salvatore Maugeri" Foundation – IRCCS, Scientific Institute of Montescano, Via per Montescano, 32, IT-27040, Montescano (PV), Italy. E-mail: roberto.casale@fsm.it

Submitted January 17, 2008; accepted December 18, 2008

INTRODUCTION

Phantom limb pain is an excruciating condition expressed in a very complex anatomic-functional background (1) occurring

in 50–80% of amputees (2). Despite these figures, there are neither recognized standard guidelines nor pharmacological or non-pharmacological clear-cut procedures to treat pain in those pathological conditions (3–5). Whilst the pharmacological interventions span a wide range of drug associations, the non-pharmacological or local modalities used for treating phantom limb pain range from invasive procedures such as spinal surgery (6) to less invasive treatments such as electrotherapy (7, 8), acupuncture (9) and the use of local anaesthetics (10, 11).

In addition to the perception of a painful phantom limb, a number of perceptual and clinical anomalies have been ascertained. Contralateral painful muscle areas in the healthy limb related to the areas of pain felt in the phantom limb have been observed (11). Synchronia, i.e. simultaneous sensation in both limbs after unilateral stimulus application, may also be present (12).

Interestingly, among the local modality treatments, traditional acupuncture stimulates points distant from painful areas such as contralateral acupuncture points (13). These sparse clinical observations suggested that treatment of these painful areas in the healthy limb might influence the phantom limb pain or sensation. As far as we know, there are only a few case reports dealing with contralateral locally injected anaesthetics (14, 15).

The aim of this study was to ascertain the existence of contralateral painful muscle areas mirroring the painful areas of the phantom and to evaluate, in a double-blinded cross-over study, the short-term effects of anaesthetic vs saline injected contralaterally in the control of phantom and phantom limb pain.

MATERIALS AND METHODS

The study protocol was approved by our ethics committee and detailed information was provided to the patients related to the aim and procedures of the study. Eight lower limb amputees affected by phantom limb pain over the last 6 months gave their consent and were then enrolled in the study. Limb amputations were performed between 9 and 15 months before the patients entered the study. Demographic features of the study group are shown in Table I. The aetiology of amputation was traumatic (3 cases) or surgical (5 cases; ischaemia).

Table I. Demographic data for the 8 patients

Age, years, mean (standard deviation)	70.1 (7.7)
Sex, male/female	6/2
Level of amputation	Above the knee
Side of amputation, left/right	5/3
Duration of phantom limb pain	More than 6 months

Although intravenous injection of this small volume of local anaesthetic would not lead to central nervous system (CNS) toxic signs, intra-arterial rapid injection of this minute volume on the other hand has the potential to induce CNS toxicity. Patients were therefore also instructed to indicate immediately to the physician any abnormal sensation occurring during injections. Moreover, during injections heart rate, pO₂ (digit oximetry, Nonin PureSAT, Nonin Medical Inc. Plymouth, MN, USA) and blood pressure (Riva-Rocci manual sphygmomanometer) were monitored continuously.

Exclusion criteria in the selection of patients were the presence of stump pain, non-healed surgical wound or ulcers of the stump and known allergy to local anaesthetics. Moreover, further exclusion criteria were the concomitant presence of clinical as well as electromyographical signs of polyneuropathy (motor and/or sensory nerves reduction in conduction velocity and compound potentials amplitude in the residual limb) as possible source of sensory alterations that could interfere with the study.

Clinical assessment

Patients were requested to draw their phantom limb on paper and to mark the painful sites within it. Then, on the corresponding topographical areas of the healthy limb, painful hyperalgesic muscle areas were located by palpation (16). To facilitate the identification of these muscle painful areas on the healthy limb, patients were also asked to indicate the presence of these muscle painful areas. The muscle sites eliciting a hyperalgesic response to palpation were reported on the same anatomical map and also marked on the skin of the patients (Fig. 1).

The same physician who performed the basal clinical examination, blinded to the treatment, visited the patients collecting the number of painful muscle areas present within 1 h of the injection. The intensity of the phantom limb pain was evaluated before and after treatment by means of visual analogue scale (VAS) from 0 (no pain) to 10 (worst pain ever experienced).

The effects on the phantom sensation after the treatments were also recorded as: present without any change, absent or reduced.

Treatments

Saline or local anaesthetic (bupivacaine 2.5 mg/ml) solutions were prepared in a separate room by a nurse, who filled syringes of the same size (10 ml). An independent physician, blinded as to the contents of the syringe, performed the injection with a 28-gauge needle to all the marked points, injecting 1 ml of the given solution. Aspiration on the syringe was used prior to injection in an attempt to minimize the likelihood of intravascular administration (17).

Randomization and statistical analysis

Both saline and local anaesthetic were administered to all subjects with a crossover design (Fig. 2). At least 72 h were allowed between the injections. Before the first and second treatment period the homogeneity of the clinical conditions between groups was tested using a

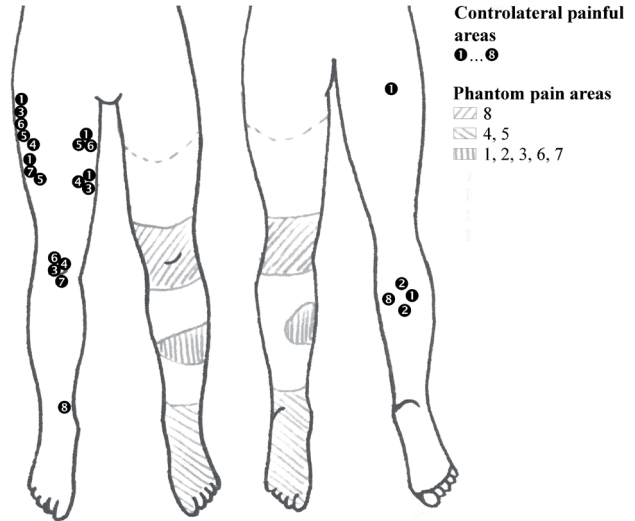


Fig. 1. Painful muscle areas and the corresponding phantom limb pain regions. For the sake of clarity, phantom limb pain and contralateral painful muscle areas are represented irrespective of the real side of amputation: on the left limb of the figure is represented the amputated limb and on the right side of the figure the contralateral limb (for the real side of amputation see the demographic features of the sample in Table I).

t-test for unpaired data. Statistical analysis of the 2-period crossover experiment was performed using a general linear model with the following sequence (saline/anaesthetic, S/A; anaesthetic/saline, A/S) as between-subject factor, and period (period 1, period 2) as repeated measure factor. Therefore, treatment effect was assessed by testing for the interaction between sequence and period factors. Descriptive statistics are reported as mean ± standard deviation (SD). A p-value <0.05 was considered statistically significant.

RESULTS

The design of the crossover experiment is shown in Fig. 2; detailed results are reported in Tables II and III. There was no significant difference in the clinical condition between treatment groups, either before the first injection (VAS score: 7.6 (SD 1) vs 7.7 (SD 0.6), p=0.9) or the second injection (VAS score: 8 (SD 1) vs 7.6 (SD 0.3), p=0.45) excluding any carry-over effect due to the cross-over design (Table II).

The effect of treatment in pain reduction, calculated as the difference in VAS score between the first hour after treatment and baseline, was greater after local anaesthetic (mean effect across groups -5.3 (SD 1.4) than after saline use (mean effect across groups -1.5 (SD 1.3) (Table III).

The general linear model analysis showed a highly significant interaction between sequence and period (p=0.003), thus providing evidence of a different response to the anaesthetic compared with saline (Fig. 3).

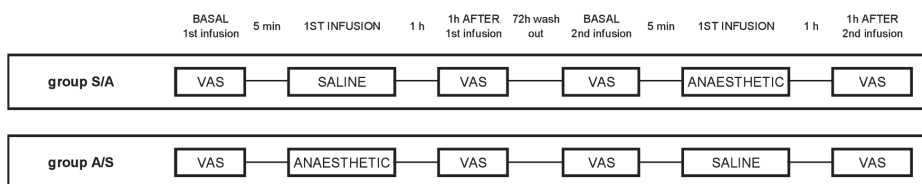


Fig. 2. Cross-over study design. S/A: sequence saline/anaesthetic; A/S: sequence anaesthetic/saline; VAS: visual analogue scale.

Table II. Intensity of pain (visual analogue scale) referred by patients before and 1 h after 1st and 2nd treatment in the 2 randomization groups

Case No.	Group	Age, years	Baseline 1 st infusion	1 h after 1 st infusion	Baseline 2 nd infusion	1 h after 2 nd infusion
1	s/a	63	8	5	8.5	3
2	s/a	70	8.8	8.2	9.1	2.1
3	s/a	64	6.5	3.2	6.7	3
7	s/a	71	7.2	6.2	7.7	0
s/a group (mean (SD))		69.3 (7.8)	7.6 (1)	5.9 (2.2)	7.8 (1.2)	2.7 (0.4)
4	a/s	60	7.5	2.6	7.8	6.5
5	a/s	80	7	2.5	7.2	7
6	a/s	81	8.2	4.1	7.7	7.7
8	a/s	72	8.1	3.4	7.6	5.3
a/s group (mean (SD))		71 (8.6)	7.6 (0.3)	6.4 (1)	7.9 (0.3)	2.5 (1.8)

s/a: sequence saline/anaesthetic; a/s: sequence anaesthetic/saline; SD: standard deviation.

Mirror displacements in healthy limbs

We observed topographical discrepancies between the healthy and the affected limbs. The distribution of the phantom and phantom limb pain were confined to distal areas of limbs. The most affected parts in the healthy limbs were the proximal latero-medial part of the thigh and the anterior compartment (tibialis anterior) of the calf, while the areas of major phantom limb pain representation were essentially related to the foot and the ankle (Fig. 1)

Phantom sensation

Bupivacaine consistently reduced/abolished the phantom sensation in 6 out of 8 patients. These effects were not observed after saline injections.

Side-effects

No clinical signs of cardiovascular or respiratory effects were recorded. No subjective reactions were reported. In particular, although local anaesthetics often produce a stinging sensation when locally injected, none of the patients reported this or mentioned the pain provoked by the use of needles.

DISCUSSION

The effects of drugs on CNS circuits after having undergone a complex rearrangement after amputation are unpredictable, making any pharmacological approach to these patients highly unsuccessful (3–5). Moreover, these drugs are often used on

the basis of their efficacy in other forms of neuropathic pain and they do not take into account the profound changes of the anatomo-functional substrates of the involved peripheral and central circuits in amputees (18–22).

In this work we present data from an unusual therapeutic approach stemming from observations of the involvement of the contralateral healthy side in the maintenance of phantom limb pain. Our data show the results from experimental injections of bupivacaine and saline in the mirroring areas of the contralateral limb of phantom painful limbs in 8 amputees. The results reveal significant pain reduction in the painful phantom limb 1 h after the local injection of bupivacaine and slight pain reduction with saline. It is also worth noting that bupivacaine also induces changes in the phantom sensation, while saline did not affect it. This result could suggest new potential therapeutic approaches to pain treatment in phantom painful limbs after an overall discouraging background (3, 5, 23, 24).

Phantom sensation and phantom pain are felt on a non-existent part of a limb. Pain treatments on the amputated limb are therefore applicable only to the stump and to the residual limb. This orientated the clinicians to administer any potential therapeutic applications of physical therapeutic modalities on the contralateral healthy limb. Additional and supporting advice came from the common findings of hyperalgesic muscle areas in the contralateral healthy limb (12) and of simultaneous cutaneous sensations on the limb evoked by contralateral limb stimulations (14).

In our patients a topographical discrepancy between the healthy and the affected side was present, with prevalent dis-

Table III. Effect of the two infusions on intensity of pain (visual analogue scale)

Case No.	Group	Age, years	Baseline saline	1 h after saline	Baseline bupivacaine	1 h after bupivacaine
1	s/a	63	8	5	8.5	3
2	s/a	70	8.8	8.2	9.1	2.1
3	s/a	64	6.5	3.2	6.7	3
4	a/s	60	7.8	6.5	7.5	2.6
5	a/s	80	7.2	7	7	2.5
6	a/s	81	7.7	7.7	8.2	4.1
7	s/a	71	7.2	6.2	7.7	0
8	a/s	72	7.6	5.3	8.1	3.4
Mean (standard deviation)		70.1 (7.7)	7.6 (0.7)	6.1 (1.6)	7.9 (0.8)	2.6 (1.2)

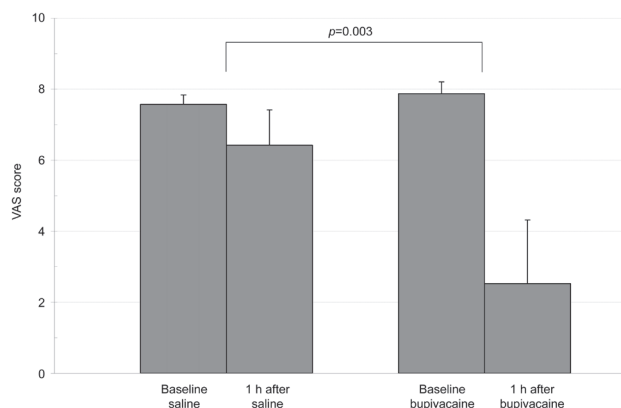


Fig. 3. Effect of saline and bupivacaine treatment on the intensity of the phantom limb pain (visual analogue scale (VAS)).

tribution of the phantom and phantom limb pain to distal areas of limbs (25). The most affected parts of the healthy limbs were the proximal latero-medial part of the thigh and the anterior compartment (tibialis anterior) of the calf, while the areas of major phantom limb pain representation were essentially related to the foot and the ankle (25) (Fig. 1). Despite this substantial mismatch between phantom limb pain localization and the location of myofascial hyperalgesic areas in healthy lower limbs, bupivacaine injection in these areas was able to reduce the phantom limb pain in all of the patients and to induce modification in the phantom perception in 6 of them. It is worth mentioning that, as described by other authors (26), saline injection was also able partially to reduce pain, yet did not affect the phantom except in one case, with a transient telescopic sensation.

The mechanism of phantom limb pain relief from contralateral injection of local anaesthetic has no clear explanation. Contralateral influences have been sparsely reported in other therapeutic contexts. Namely, effective contralateral physical treatments such as transcutaneous electrical nerve stimulation (8) and acupuncture (9, 27) showed some effects on pain from the injured side, presumably either by spinal gating or by opioidergic modulation (9, 27). However, the use of local anaesthetic differs from the above treatments by abating contralateral input and not by modulating it (28, 29). The anatomo-functional findings endorse the hypothesis of a potential central origin of these reciprocal responses. However, the elucidation of mechanisms supporting these results shows contradictory interpretation. As for one model, transitory input suppression from the contralateral healthy side could produce a paradoxical balancing of the overall input weighed on both sides by mimicking the lack of input of the injured side. Dynamic equalization of the 2 sides could reduce the sensory effects of unbalanced inputs. Results obtained from neural networks support this model: in balanced networks, where the slightest change of the excitatory input provoke huge changes from asynchronous to synchronous discharging mode (30). Experimental results obtained on animal models of chronic pain also advocate this hypothesis. At the spinal level of chronic constriction injury animal

models, the unbalanced inputs from the injured regions seem to unveil or unmask normally silenced contralateral inputs. These segmental contralateral signals appear to play a major role in the maintenance of local circuit hyperactivity and hyper-responsiveness (31). Modulating these inputs (e.g. by local injection of lidocaine on the afferent nerves of the contralateral limb) provokes spontaneous and evoked activity reduction of spinal neurons of the injured circuits (29, 31). It is obvious that also supraspinal changes must be taken into account. Thalamic and cortical reorganization could facilitate contralateral transfers, but no actual specific modelling is currently available from literature (32).

The potential systemic or secondary effect of bupivacaine can be ruled out by the very diluted plasmatic levels achieved after the injection (28). Additionally, no systemic reaction was observed supporting the anaesthetic systemic diffusion. Moreover, phantom limb pain does not seem to be completely controlled by a local peripheral blockade (33).

Altered connectivity seems to be a dynamic marker in amputees. Other surprising anomalies, such as synchiria and dysynchiria (with touch or pain evoked in the injured limb by light stimuli on healthy limb), are often present, supporting the hypothesis of potential unmasking of mutual contralateral connections (31). The dynamic properties induced by the bilateral sensorimotor image of lateralized inputs seem to be the consequence of strong developmental anatomical design where robust bilateral interactions between the developing neural systems on each side are important for achieving connectivity balance between the 2 sides of the neuraxis (34).

The fast pain relief obtained in the patients, as shown in our data, would match the speed of segmental signal transition between the 2 sides of the system. These characteristics could explain many of the data reported here and elsewhere, even if obvious questions remain; for instance, the strength, the distribution level of the mutual connections and the role they play in the clinical stage.

REFERENCES

1. Flor H, Nikolajsen L, Jensen TS. Phantom limb pain: a case of maladaptive CNS plasticity? *Nature Rev* 2006; 7: 873–881.
2. Nikolajsen L, Jensen TS. Phantom limb. In: McMahon SB, Koltzenburg M, editors. *Wall and Melzack's textbook of pain*. Edinburgh: Elsevier Churchill Livingstone; 2006, p. 961–971.
3. Sherman RA, Sherman CJ, Gall NG. A survey of current phantom limb pain treatment in the United States. *Pain* 1980; 8: 85–99.
4. Chahine L, Kanazi G. Phantom limb syndrome: a review. *Middle East J Anesthesiol* 2007; 19: 345–355.
5. Casale R, Alaa L, Mallick M, Ring H. Phantom limb related phenomena and their rehabilitation after lower limb amputation. *Eur J Phys Rehabil Med* 2009; Feb 26 [Epub ahead of print].
6. Sakas DE, Panourias IG, Simpson BA. An introduction to neural networks surgery, a field of neuromodulation which is based on advances in neural networks science and digitised brain imaging. *Acta Neurochir Suppl* 2007; 97: 3–13.
7. Miles J, Lipton S. Phantom limb pain treated by electrical stimulation. *Pain* 1978; 5: 373–382.
8. Carabelli RA, Kellerman WC. Phantom limb pain: relief by application of TENS to contralateral extremity. *Arch Phys Med Rehabil* 1985; 66: 466–467.

9. Monga TN, Jaksic T. Acupuncture in phantom limb pain. *Arch Phys Med Rehabil* 1981; 62: 229–231.
10. Lierz P, Schroegendorfer K, Choi S, Felleiter P, Kress HG. Continuous blockade of both brachial plexus with ropivacaine in phantom pain: a case report. *Pain* 1998; 78: 135–137.
11. Gross D. Contralateral local anaesthesia in the treatment of postamputation pain. In: Siegfried J, Zimmermann M, editors. *Phantom and stump pain*. Berlin: Springer-Verlag; 1981, p. 107–109.
12. Ramachandran VS, Rogers-Ramachandran D, Cobb S. Touching the phantom limb. *Nature* 1995; 377: 489–490.
13. Chapman RC, Chang Gunn C. Acupuncture. In: Bonica JJ, editor. *The management of pain, II Ed*. Philadelphia: Lea & Febiger; 1990, p. 1805–1821.
14. Gross D. Contralateral local anaesthesia in the treatment of phantom limb and stump pain. *Pain* 1982; 13: 313–320.
15. Flöter T. Pain management by contralateral local anaesthesia. *Acupunct Electrother Res* 1983; 8: 139–142.
16. Travell J. Myofascial trigger points: a clinical view. In: Bonica JJ, Albe-Fessard D, editors. *Advances in pain research and therapy*. New York: Raven Press; 1976, p. 919–926.
17. Bonica JJ, Buckley M. Regional analgesia with local anaesthetics. Basic consideration. In: Bonica JJ, editor. *The Management of pain, II Edition*. Philadelphia: Lea & Febiger; 1990, p. 1883–1896.
18. Florence SL, Taub HB, Kaas JH. Large-scale sprouting of cortical connections after peripheral injury in adult macaque monkeys. *Science* 1998; 282: 1117–1121.
19. Devor M, Wall PD. Reorganization of spinal cord sensory map after peripheral nerve injury. *Nature* 1978; 276: 75–76.
20. Moore KA, Kohno T, Karchewski LA, Scholz J, Baba H, Woolf CJ. Partial peripheral nerve injury promotes a selective loss of GABAergic inhibition in the superficial dorsal horn of the spinal cord. *J Neurosci* 2002; 22: 6724–6731.
21. Coull JA, Beggs S, Boudreau D, Boivin D, Tsuda M, Inoue K, et al. BDNF from microglia causes the shift in neuronal anion gradient underlying neuropathic pain. *Nature* 2005; 438: 1017–1021.
22. Torsney C, MacDermott AB. Disinhibition opens the gate to pathological pain signaling in superficial neurokinin 1 receptor-expressing neurons in rat spinal cord. *J Neurosci* 2006; 26: 1833–1843.
23. Halbert J, Crotty M, Cameron ID. Evidence for the optimal management of acute and chronic phantom pain: a systematic review. *Clin J Pain* 2002; 18: 84–92.
24. Flor H. Phantom-limb pain: characteristics, causes, and treatment. *Lancet Neurol* 2002; 1: 182–189.
25. Loeser JD. Pain after amputation: phantom limb and stump pain. In: Bonica JJ, editor. *The management of pain*. Philadelphia: Lea & Febiger; 1990, p. 244–256.
26. Frost FA, Jessen B, Siggaard-Andersen J. A control, double-blind comparison of mepivacaine injection versus saline injection for myofascial pain. *Lancet* 1980; 1: 499–500.
27. Bradbrook D. Acupuncture treatment of phantom limb pain and phantom limb sensation in amputees. *Acupunct Med* 2004; 22: 93–97.
28. Golembiewski J. Local anesthetics. *J Perianesth Nurs* 2007; 22: 285–288.
29. Bileviciute-Ljungar I, Biella G, Bellomi P, Sotgiu ML. Contralateral treatment with lidocaine reduces spinal neuronal activity in mononeuropathic rat. *Neurosci Lett* 2001; 311: 157–160.
30. Hertz AJ. Neurons, Networks and cognition: an introduction to neural modelling. In: van Hemmen L, Cowan JD, Domany E, editors. *Models of neural networks IV*. Berlin: Springer Verlag; 2002, p. 1–46.
31. Sotgiu ML, Biella GE. Spinal neuron sensitization facilitates contralateral input in rats with peripheral mononeuropathy. *Neurosci Lett* 1998; 241: 127–130.
32. Werhahn KJ, Mortensen J, Kaelin-Lang A, Boroojerdi B, Cohen Leonardo G. Cortical excitability changes induced by deafferentation of the contralateral hemisphere. *Brain* 2002; 6: 1402–1413.
33. Schley M, Topfner S, Wiech K, Schaller HE, Konrad CJ, Schmelz M, et al. Continuous brachial plexus blockade in combination with the NMDA receptor antagonist memantine prevents phantom pain in acute traumatic upper limb amputees. *Eur J Pain* 2007; 11: 299–308.
34. Friel KM, Martin JH. Bilateral activity-dependent interactions in the developing corticospinal system. *J Neurosci* 2007; 27: 11083–11090.