

## CASE REPORT

# SIGNIFICANT RECOVERY OF MOTOR FUNCTION IN A PATIENT WITH COMPLETE T7 PARAPLEGIA RECEIVING ETANERCEPT\*

Mickaël Dinomais, MD<sup>1,3</sup>, Laura Stana, MD<sup>1,3</sup>, Guy Egon, MD<sup>5</sup>, Isabelle Richard, MD, PhD<sup>1,3</sup> and Philippe Menei, MD, PhD<sup>2,4</sup>

From the <sup>1</sup>Department of Physical Medicine and Rehabilitation and <sup>2</sup>Service of Neurosurgery, Faculty of Medicine, University of Angers, <sup>3</sup>Department of Physical Medicine and Rehabilitation, CRRRF Angers, Adulte, <sup>4</sup>INSERM, U646, Angers and <sup>5</sup>Rehabilitation Center of l'Arche, Le Mans, France

**Objective:** To report an unusual case of significant motor recovery in a patient with T7 complete paraplegia treated with etanercept for ankylosing spondylitis.

**Design:** Case report.

**Results:** During the first year sensory-motor recovery occurred, and the American Spinal Injury Association Impairment Scale (AIS) improved from A to D.

**Conclusion:** Initial spinal cord injury is a direct consequence of the trauma. It triggers a series of molecular and cellular reactions leading to “secondary damage”. Tumour necrosis factor  $\alpha$  is a key inflammatory mediator that is increasingly expressed after spinal cord injury. Etanercept is a recombinant dimer of human tumour necrosis factor  $\alpha$  receptor protein that inhibits tumour necrosis factor  $\alpha$  activity. It has shown an immunomodulatory effect in mice after traumatic spinal cord injury. It significantly reduced the post-traumatic spinal cord inflammation and the perilesional area. In this case, a reduction in the secondary damage, due to etanercept treatment could explain the significant motor recovery, which is unusual since 80% of AIS A lesions remain complete.

**Key words:** spinal cord injury, etanercept, neurological recovery, TNF- $\alpha$ .

J Rehabil Med 2009; 41: 286–288

*Correspondence address:* Isabelle Richard, Département de médecine physique et réadaptation adulte, CHU-CRRRF, 3 rue des capucins, BP 40329, 49103 Angers cedex 02, France. E-mail: [isabelle.richard@univ-angers.fr](mailto:isabelle.richard@univ-angers.fr)

Submitted June 17, 2008; accepted October 31, 2008

## INTRODUCTION

Improved understanding of the physiological mechanisms underlying spinal cord injury (SCI) has led in the past decade (1) to a number of hypotheses regarding the possible therapeutic role of neuroprotective agents (2). The initial mechanical trauma

causes the death of a number of neurones, which, to-date, cannot be regenerated, and triggers a cascade of reactions at cellular and molecular levels known as secondary injury. These secondary events cause massive cell death and contribute significantly to the overall permanent neurological impairments, but may be influenced by early pharmacological intervention. One of the key factors of secondary damage is local inflammatory response in the damaged spinal cord. Tumour necrosis factor (TNF)- $\alpha$  is one of the key inflammation mediators and is increasingly expressed in the first hours following SCI (3). Etanercept is a recombinant dimer of human TNF- $\alpha$  receptor proteins. It inhibits TNF- $\alpha$  activity by competitive binding to the receptor. A recent study (4) in an experimental model of SCI demonstrated that etanercept reduced the post-traumatic inflammatory reaction as well as the motor dysfunction associated with SCI, suggesting that etanercept could be among the potential candidate drugs to reduce secondary SCI damage. This drug is currently used in ankylosing spondylitis and has been shown to improve symptoms in this condition (5). There are, to our knowledge, no findings supporting the effects of etanercept in SCI in humans. The aim of this case report is to document the motor recovery observed in a patient with complete T7 paraplegia who happened to be receiving etanercept for spondylarthritis.

## CASE REPORT

A 41-year-old woman had been treated with etanercept since 2004 (50 mg weekly, followed by 25 mg weekly since the summer of 2006) for ankylosing spondylitis diagnosed in 1992. She was injured in a traffic accident in September 2006 and referred to a level 1 trauma centre.

Clinical examination at 2 h post-injury revealed T10 Impairment Scale (AIS) A paraplegia. Emergency nuclear magnetic resonance (NMR) examination revealed a T6–T7 fracture with anterior displacement of the body of T6 and a fracture dislocation of the spine (Fig. 1a and b). Vertebral ankylosis was significant with a bamboo spine. Surgery was performed 5 h after injury, combining T6–T7–T8 laminectomy, vertebral osteosynthesis, and incomplete reduction of the displacement (Fig. 2).

The last intake of etanercept was on the day of the accident, and the drug was then discontinued.

\*This paper was presented as a poster on the 16<sup>th</sup> European Congress of Physical and Rehabilitation Medicine, on June 3–6, 2008 in Brugge, Belgium and the paper has also been published as an abstract in J Rehabil Med 2008; 40 Suppl 47: 255–256.

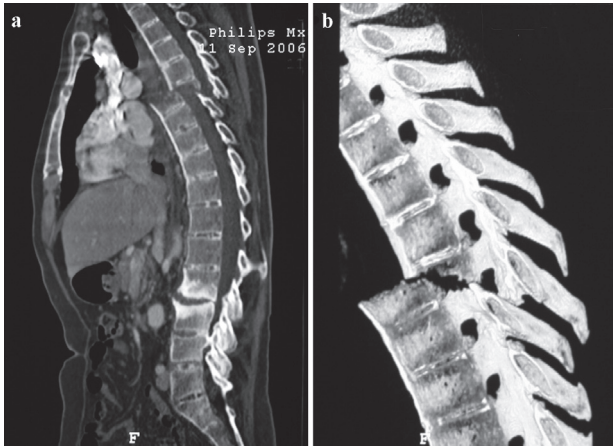


Fig. 1. Initial sagittal nuclear magnetic resonance of dorso-lumbar spine.

Neurological examination on day one showed partial sensory recovery (T7 AIS B Paraplegia). Neurological status was unchanged at 15 days' follow-up (American Spinal Injury Association (ASIA) score: motor 50/100, touch 72/112, prick 70/112, AIS B).

Postoperative evolution was marked by local infection, requiring surgical revision at 6 weeks and antibiotics (cloxacillin 3 g/day; levofloxacin 500 mg/day for 3 weeks) with favourable outcome.

The patient was referred to a neurological rehabilitation centre on day 18. Sensorimotor recovery occurred during the following year. At 6 months the ASIA scores had improved to a motor score of 78/100 and a sensory score of 84/112 for touch and 79/112 for prick. The patient was classified AIS D, and walked 30 m in 6 min with a walker.

At one year post-trauma, the ASIA motor score was 89/100, and ASIA sensory score was 84/112 for touch and 79/112 for prick. The patient walked 50 m in 6 min with a single crutch, and could climb the stairs. Magnetic resonance imaging (MRI) revealed incomplete reduction and the persistence of an important "step off" sign (Fig. 3).

DISCUSSION

Changes in AIS classification and/or changes in ASIA motor and sensory scores are used internationally to document recovery after SCI. A recent review (6) of the spontaneous recovery observed after SCI has demonstrated that neurological status at one year is mainly dependent on the initial grading of the patient. Almost 80% of the initial AIS A patients remain AIS A, 10% improve to AIS B and about 10% to AIS C.

The remarkable recovery of our patient from AIS A to AIS D appears to be highly unusual. It occurred despite incomplete reduction of the initial fracture, in part due to the surgical limitations caused by the bamboo spine. This raises the question of a possible contribution of the pre-existing etanercept treatment to the final result.

Several experimental studies have shown the key role of TNF-α in the secondary injury occurring after a SCI, and inhibition of TNF-α could be a possible therapeutic target. Genovese et al. (7) showed that TNF-α and interleukin-1β pro-inflammatory cytokines play an important role in the production of nitric oxide (NO) by the induction of nitric oxide synthetase (iNOS). NO is a highly reactive free radical and high levels of NO are known to be neurotoxic. The key role of iNOS in the development of the secondary damage leading to apoptotic cell death (7, 8) has been documented. Injection of

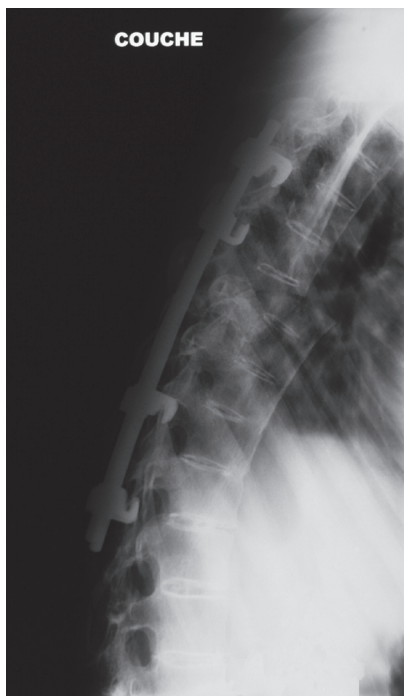


Fig. 2. Radiography of dorso-lumbar spine after surgery.

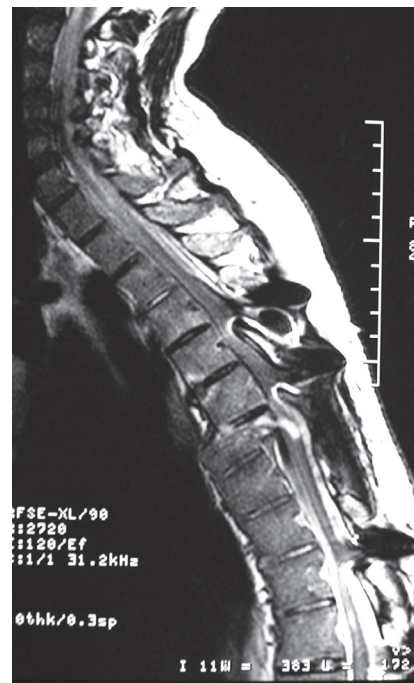

Fig. 3. Sagittal T2 magnetic resonance imaging of dorso-lumbar spine at one year post-trauma.

interleukin 10, a potent anti-inflammatory cytokine, reduces TNF- $\alpha$  production in the spinal cord and improves functional recovery after SCI (9).

Etanercept inhibits the activity of TNF- $\alpha$  by competitive binding with its cell surface receptor. In an animal model of SCI, etanercept (5 mg/kg) given 1 h before the SCI reduced the activity of the TNF- $\alpha$  and improved the functional prognosis of the animal (4). Significant decrease in the degree of spinal cord inflammation, apoptosis and tissue injury was also observed. iNOS concentration levels and the expression of TNF- $\alpha$  were notably decreased after SCI.

The effects of etanercept alone have been compared with the effects of a combination of dexamethasone and etanercept in an animal model (10). Etanercept was administered at a dose of 1.25 mg/kg 1 h after SCI. The inhibition of TNF- $\alpha$ , decrease in inflammation and improvement in neurological status were significant in the group treated with the combination, and not in the group treated with etanercept alone. This could be due to the dosage of etanercept or to the timing of the administration. Such results show that secondary damage should be considered as a cascade of reactions that are both redundant and complex. Synergistic blocking of several of the mechanisms may be necessary to achieve significant clinical results. In our patient, etanercept had been administered for several months before the SCI.

Dosage may also play an important role. Indeed animal studies have shown that inflammation can also have a protective effect and that cell death and functional impairment are greater after SCI in transgenic mice lacking TNF- $\alpha$  receptors and insensitive to endogenous TNF- $\alpha$  (11).

Significant recovery occurred in this patient despite the persistence of major spinal compression. Animal experiments have shown that significant neurological function can be obtained with 1.4–12% of the axons (1), thus suggesting that even the salvage of a small number of axons may be of clinical benefit. It stresses the importance of limiting the secondary injury occurring in acute SCI.

Several other drugs have been screened in animal models and tested in humans with the aim of limiting secondary damage. Clinical trials have been conducted in patients with SCI with opioid antagonists (naloxone) (12), N-methyl-D-aspartate receptor antagonists (gacyclidine), gangliosides (GM-1) (13) and corticoids (methylprednisolone) (12, 14), but these trials have shown no clinical benefit. The National Acute Spinal Cord Injury Study (NASCIS) studies have evaluated the effects of methylprednisolone in acute SCI and have shown no effect on the functional outcome at one year. The methodology of these studies has been a subject of debate (15). One study (13) evaluated the effects of ganglioside M1 vs placebo in 797 patients treated with methylprednisolone and found no significant differences in ASIA score or Bzenel classification at one year.

Etanercept is immuno-suppressive and may have played a role in the occurrence of post-operative infection in our patient.

In conclusion, this case report documents functional recovery in a patient with SCI with initial complete paraplegia, treated by etanercept prior to injury. This drug was shown to reduce post-traumatic inflammation in the spinal cord and could be a potential candidate for clinical trials.

## REFERENCES

1. Kwon BK, Tetzlaff W, Grauer JN, Beiner J, Vaccaro AR. Pathophysiology and pharmacologic treatment of acute spinal cord injury. *Spine J* 2004; 4: 451–464.
2. Amar AP, Levy ML. Pathogenesis and pharmacological strategies for mitigating secondary damage in acute spinal cord injury. *Neurosurg* 1999; 44: 1027–1040.
3. Harrington JF, Messir AA, Levine A, Szymdinger-Chodobska J, Chodobski A. Shedding of tumor necrosis factor type 1 receptor after experimental spinal cord injury. *J Neurotrauma* 2005; 22: 919–928.
4. Genovese T, Mazzon E, Crisafulli C, Di Paola R, Muia C, Bramanti P, Cuzzocrea S. Immunomodulatory effects of etanercept in an experimental model of spinal cord injury. *J Pharmacol Exp Ther* 2006; 316: 1006–1016.
5. Braun J, Sieper J. Ankylosing spondylitis. *Lancet* 2007; 369: 1379–1390.
6. Fawcett JW, Curt A, Steeves JD, Coleman WP, Tuszynski MH, Lammertse D, et al. Guidelines for the conduct of clinical trials for spinal cord injury as developed by the ICCP panel: spontaneous recovery after spinal cord injury and statistical power needed for therapeutic clinical trials. *Spinal Cord* 2007; 45: 190–205.
7. Genovese T, Mazzon E, Mariotto S, Menegazzi, Cardali S, Conti A, et al. Modulation of nitric oxide homeostasis in a mouse model of spinal cord injury. *J Neurosurg Spine* 2006; 4: 145–153.
8. Marsala J, Orendacova J, Lukacova N, Vanicky I. Traumatic injury of the spinal cord and nitric oxide. *Prog Brain Res* 2007; 161: 171–183.
9. Bethea JR, Nagashima H, Acosta MC, Briceno C, Gomez F, Marcillo AE, et al. Systemically administered interleukin-10 reduces tumor necrosis-alpha production and significantly improves functional recovery following traumatic spinal cord injury in rats. *J Neurotrauma* 1999; 16: 3251–3260.
10. Genovese T, Mazzon E, Crisafulli C, Esposito E, Di Paola R, Muia C, et al. Combination of dexamethasone and etanercept reduces secondary damage in experimental spinal cord trauma. *Neuroscience* 2007; 150: 168–181.
11. Kim GM, Xu J, Xu J, Song SK, Yan P, Ku G, et al. Tumor necrosis factor receptor deletion reduces nuclear factor-kappaB activation, cellular inhibitor of apoptosis protein 2 expression, and functional recovery after traumatic spinal cord injury. *J Neurosci* 2001; 21: 6617–6625.
12. Bracken MB, Shepard MJ, Collins WF, Holford TR, Young W, Baskin DS, et al. A randomized, controlled trial of methylprednisolone or naloxone in the treatment of acute spinal-cord injury. Results of the Second National Acute Spinal Cord Injury Study. *N Engl J Med* 1990; 322: 1405–1411.
13. Geisler FH, Coleman WP, Grieco G, Poonian D. The Sygen multicenter acute spinal cord injury study. *Spine* 2001; 26 Suppl 24: S87–S98.
14. Bracken MB, Shepard MJ, Holford TR, Leo-Summers L, Aldrich EF, Fazl M, et al. Methylprednisolone or tirilazad mesylate administration after acute spinal cord injury: 1 year-follow up. Results of the third National Acute Spinal Cord Injury randomized controlled trial. *J Neurosurg* 1998; 89: 699–706.
15. Hurlbert RJ. Methylprednisolone for acute spinal cord injury: an inappropriate standard of care. *J Neurosurg* 2000; 93 Suppl 1: 1–7.