

Münchhausen's Syndrome with Congenital Generalized Epidermolysis Bullosa Simplex

Sir,

Münchhausen's syndrome (MS) consists of voluntary simulation of factitious illness, associated with mythomania and a tendency to migrate from hospital to hospital (1-3). The many cases (4-6) have rarely been described by dermatologists because cutaneous lesions, frequent in pathomimia, are uncommon in MS or often undiagnosed as MS (7-11). Patients with the classic form provoke full factitious symptoms (1, 2) but MS may also be caused by exacerbating pre-existing illnesses (1, 8). We here present a new case of MS, occurring in a patient exacerbating a congenital epidermolysis bullosa simplex, Koebner subtype (EBK).

CASE REPORT

A 34-year-old unmarried man was admitted to the department of Dermatology in Strasbourg in 1991 because of generalized blisters due to EBK. For 6 months, he had been hospitalized in Mulhouse twice, following the appearance of generalized blisters after he had been operated on disembowelment. On admission, the patient was covered with bandages like a mummy and claimed to consume much bromazepam and many tablets of a mixture of paracetamol-codeine. There

were numerous generalized flaccid blisters, sparing his face and the frictional areas such as elbows, knees, palms and soles (Fig. 1). There was neither atrophic scarring, nor milia, nor dyschromia. Hair, teeth, nails or mucous membranes were not affected and Nikolsky's sign was negative. Examination revealed an abdominal median scar. His past cutaneous medical history, based on his mother's and grandmother's testimonies, revealed that his father and his uncle had had a chronic bullous disease, which he told us to be EBK. At birth, he was covered with blisters and was hospitalized in Paris. During childhood, blisters occurred during sport and trauma. He was hospitalized in Bordeaux both in 1971 and in 1973, and in Montpellier in 1979, where the diagnosis of EBK was confirmed. From that time on, he worked as a labourer but he only experienced blisters on his soles when he had been walking for a long time.

We performed skin biopsies on blisters for light microscopy. In one specimen, the cleavage was located in the stratum spinosum, and the roof of the blister was composed of necrotic epidermis. In another blister, cleavage occurred beneath the stratum corneum, as observed in traumatic blisters. We took a biopsy specimen after attempting to induce a blister by rubbing. Electron microscopy revealed no dermis and basal lamina changes. The cleavage resulted from a disruption at the basal part of the basal keratinocytes. The floor of the blister included the basal plasma membrane, hemidesmosomes and some cytoplasmic constituents, and was surrounded by basal to lower

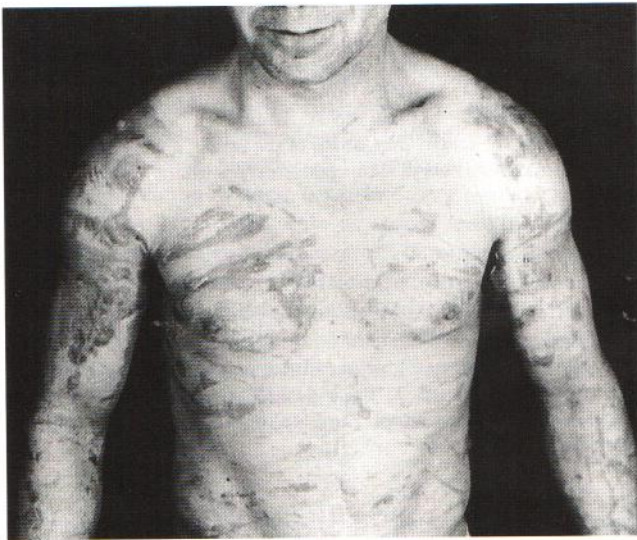


Fig. 1. The patient on admission. Numerous blisters on the trunk, reproducing his bandages. "Mona Lisa's smile".

spinous cell cytolysis. According to the heredity and the past history of the patient, and to the ultrastructural aspect, the diagnosis was consistent with EBK. However, clinical data was conflicting since there were no blisters on frictional areas, and the patient was uninjured between 1979 and 1991. Though he rapidly recovered during hospitalization, he relapsed after leaving, exhibiting new geometrical lesions. Moreover, he suddenly had urinary bleeding but exhaustive exploration did not show any urogenital changes.

We suspected he suffered from MS, provoking self-induced aggravation of his EBK. We re-questioned him, discovering a long medical history authenticated by medical reports from different hospitals (Fig. 2). He had undergone laparotomy twice in 1979; after ingestion of scissors and screws while he was incarcerated in Carcassonne, and in March in Pau as he had ingested a spoon, where he was caught attempting to pull out his drip and undo his abdominal stitches. In June, he ingested sword blades in Montpellier: he was operated on and blisters appeared around the abdominal scar which became infected and disjointed. In 1982, surgery in his right knee in Colmar was followed by suppuration. In October, he was operated in Morteau for jawbone fracture, and he would himself tear off the external fixator with pincers. In 1991, disembowelment was cured in Mulhouse, followed by fever and the rise of blisters. He also reported hospitalizations for gastric ulcer, jawbone and thighbone fractures and alcoholic

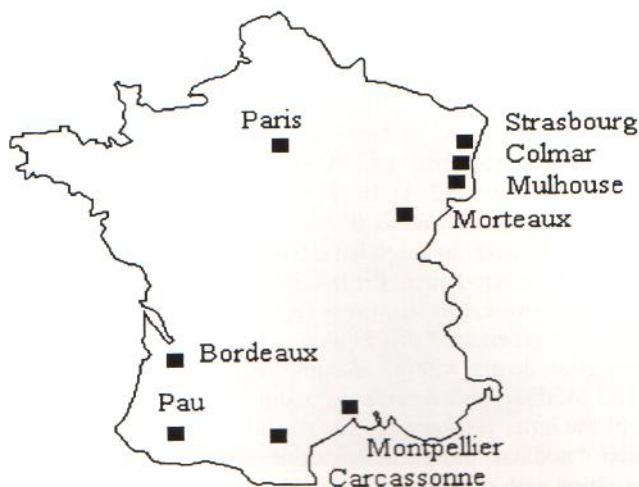


Fig. 2. The "Tour de France" of known hospitalizations.

coma in the 70's, jawbone fracture in 1986, and 3 operations on the right knee.

As the patient asked us how and why his blisters occurred, we proposed that he be recorded by video for 24 h, but he demanded to leave the hospital after some minutes. He came back 1 month later, exhibiting a copy of the medical report which emphasized the paradoxical lack of palmar and solar blisters, and a voluminous palmar blister. One year later, he had surgery for an unexplained 6-cm bladder stone in Mulhouse.

DISCUSSION

MS most often arises in young adults, being more common in males than in females and in the medically related professions. Physical trouble during childhood or adolescence, leading to extended treatment or hospitalization, could provoke a grudge against the medical profession (1, 2, 8), but MS also could be sustained by cerebral dysfunction (3). In most cases, the patients are "hospital addicted" and simulation of illness is the centre of their lives, not compatible with normal social and familial ties (1, 2, 8). In some temporary cases, they may continue to have a normal life with more or less frequent fits (5). Patients display considerable medical knowledge and use colourful details. They may influence doctors and suggest a diagnosis to them (1, 2, 6, 8). Their potential for seduction provokes compassion, but they also exasperate everyone by a "time-consuming, obscene, obstinate and obstreperous attitude" (2). They often complain of unbearable pain, claim to use a lot of analgesics or to be drug-addicts but resist discharge in spite of drugs being withdrawn (1, 3, 6, 8, 11). They do not often expect visitors during hospitalizations. If the investigations prove to be negative or suspicion occurs, new symptoms will begin. MS differs from malingering, hysteria and schizophrenia (1, 2, 4, 8) and the patients are often considered as having borderline, psychopathic or even a criminal comportment (8, 10). They are conscious of self-inflicted lesions, but secondary gains are not evident, and their only goal seems to be holding the practitioner in check (1, 2, 8). In any circumstances, we observed the smile of our patient, like that of Mona Lisa, stamped with some mystery and perhaps a touch of amusement regarding his symptoms (Fig. 1) and medical restlessness about himself.

The diagnosis of MS is usually hard to confirm, and it was more difficult in this case of self-inflicted aggravation of EBK. We were alerted by the atypical clinical course, the dramatic past medical history, and by the mythomania, though poorly expressed at the start, of this sufferer described as "pathetic, engaging, but also annoying" by the nursing staff. Most often regarded as incurable, MS may lead to severe mutilations or even death by self-inflicted lesions, explorations, operations and medical treatments (1, 2, 4, 6, 8, 10, 11). Practically, the patients should be referred to a psychiatrist but they refuse all treatment and leave the practitioner as soon as their stratagem has been discerned (1, 2, 4, 7, 8, 9, 11). Registers and even tattoos have been considered (4), but this will never prevent self-mutilations and it is a danger to confound a medical emergency. This remarkable syndrome remains a challenge to the medical profession.

REFERENCES

1. Asher R. Münchhausen's syndrome. *Lancet* 1951; 10: 339-341.
2. Chapman JS. Peregrinating problem patients-Münchhausen's syndrome. *JAMA* 1957; 165: 927-933.

3. Lawrie S, Goodwin G, Masterton G. Münchausen's syndrome and organic brain disorder. *Br J Psychiatry* 1993; 162: 545-549.
4. Savard G, Andermann F, Teitelbaum J, Lehmann H. Epileptic Münchausen's syndrome: a form of pseudoseizures distinct from hysteria and malingering. *Neurology* 1988; 38: 1628-1629.
5. Higgins PM. Temporary Münchausen syndrome. *Br J Psychiatry* 1990; 157: 613-616.
6. Churchill DR, De Cock KM, Miller RF. Feigned HIV infection/AIDS: malingering and Münchausen's syndrome. *Genitourin Med* 1994; 70: 314-316.
7. Lyell A. Cutaneous artifactual disease. A review, amplified by personal experience. *J Am Acad Dermatol* 1979; 1: 391-407.
8. American Psychiatric Association. Diagnostic and statistical manual of mental disorders (DSM-IV). APA, Edition 4, Washington, DC, 1994.
9. Fays-Bouchon N. Syndrome de Münchhausen à révélation dermatologique. *Nouv Dermatol* 1991; 10: 566-571.
10. Parent DJ, Krafft T, Noel JC, Askenasi R, Goldschmidt D, Heenen M, Linkowski P. Cutaneous Münchausen syndrome with presentation simulating pyoderma gangrenosum. *J Am Acad Dermatol* 1994; 31: 1072-1074.
11. Puig L, Pérez M, Llauro A, Esquiús J, Moreno A, Ma de Moragas J. Facticial dermatosis of the breast: a possible dermatologic manifestation of Munchausen's syndrome. *Cutis* 1989; 44: 292-294.

Accepted July 15, 1996.

C-J. Le Coz¹, B-J. Cribier^{1*}, N. Boehm², B. Schubert³, E. Heid¹ and E-M. Grosshans¹

¹Department of Dermatology and ²Institute of Histology, University Hospital of Strasbourg, 1, Place de l'Hôpital, F-67091 Strasbourg Cedex, and ³Department of Dermatology, Emile Muller Hospital, Mulhouse, France.