

LETTERS TO THE EDITOR

Widespread Cutaneous Cryptococcosis Occurring in an Immunocompromised Patient Treated with High Doses of Fluconazole for Oro-pharyngeal Candidosis

Sir,

Cryptococcosis affects immunocompromised patients suffering from lymphomas, leukoses, sarcoidosis, carcinomas, acquired immunodeficiency syndrome (AIDS), autoimmune collagen disorders, or after visceral transplants and long-term treatment with systemic steroids. The respiratory tract is the usual portal of entry. Systemic involvement mainly affects the central nervous system (chronic meningitis or tumour-like lesions). Skin involvement affects 10 subjects out of 100 and it can sometimes be the first symptom. The clinical patterns are: acneiform papules or pustules, turning into warty or vegetating crusted plaques, subcutaneous erythema nodosum-like swellings and solitary nodulo-papular lesions (1). Molluscum contagiosum-like lesions are described in patients with AIDS. The diagnosis of cryptococcosis is histopathologic (spherical and capsulated organism) and cultural (white, small colonies growing at 37°C). The most chosen treatment is amphotericin B, but new, better tolerated drugs, such as itraconazole and fluconazole (2, 3) have recently been used, generally with good results.

CASE REPORT

A 33-year-old male, country resident, former drug consumer, affected with AIDS (and treated with AZT for 4 years) and with severe oropharyngeal candidosis (treated with oral fluconazole at a dose of 200 mg/day for 3 months) was admitted to our hospital for severe weight loss, asthenia and fever (37.5°-38°). He was given intravenous fluconazole at a dose of 400 mg/day and intravenous ceftazidime 2 g/day. Two days later, umbilicated papules occurred in an eruptive pattern on his face, mouth and trunk. These lesions had a nodular, cystic, necrotic or ulcerative evolution (Fig. 1).

The histopathologic pattern highlighted capsulated organisms, clustered in lobulated masses, widely lying on the derma. The diagnosis of widespread cutaneous cryptococcosis was formulated on the basis of the cultivation of a skin specimen, and the patient received 800/mg/day of intravenous fluconazole. After 1 week, no improvement was seen, so intravenous amphotericin B, at a dose of 1 mg/kg/day, was given for 20 days. The treatment led to the complete healing of both the cutaneous and the systemic symptoms.

DISCUSSION

Subjects suffering from AIDS may have molluscum contagiosum-like lesions caused by secondary dissemination, without any other symptoms. These findings generally suggest that the health status is highly compromised and that the prognosis is poor. Most of the cases reported in the literature occurred in the same skin areas and with the same lesional characteristics as in our subject, but it is uncommon to find molluscum contagiosum-like papules as diffuse and numerous as those in our patient (4). The use of amphotericin B, quickly effective, suggests that this drug does not have to be abandoned by physicians.

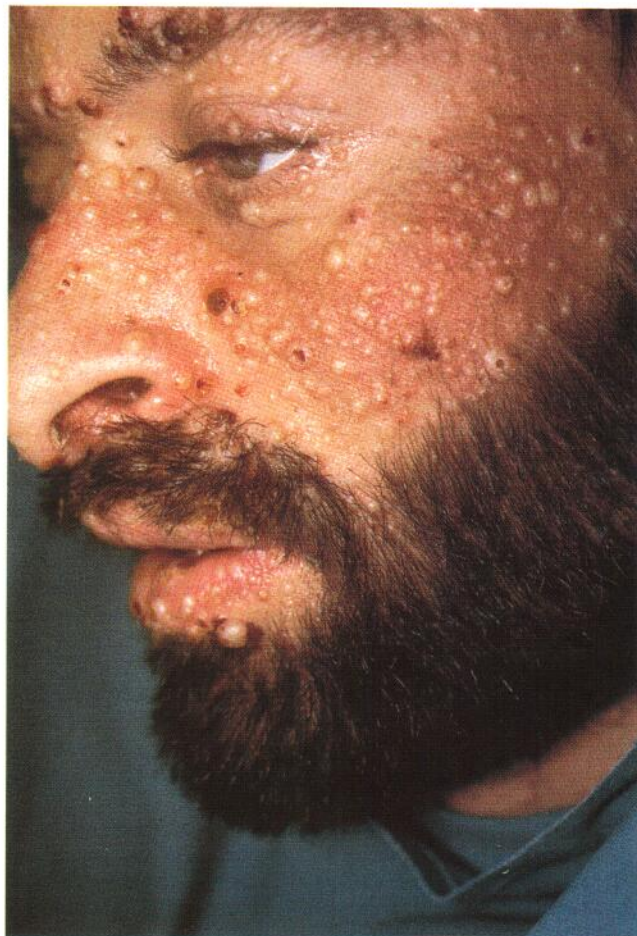


Fig. 1. Diffuse eruption of molluscum-like papules on the face.

REFERENCES

1. Dimino-Emme L, Gurevitch AW. Cutaneous manifestations of disseminated cryptococcosis. *J Am Acad Dermatol* 1995; 32: 844-850.
2. Cooper CM, Gordon DL, Reid C, Philpot CR. Cutaneous cryptococcosis: recurrence following oral fluconazole treatment. *Austr J Dermatol* 1992; 33: 93-96.
3. Feldman SR, Fleischer AB Jr, Resnick SD. Fluconazole treatment of cutaneous cryptococcosis. *Arch Dermatol* 1992; 128: 1045-1046.
4. Sulica RL, Kelly J, Berberian BJ, Glaun R. Cutaneous cryptococcosis with molluscum contagiosum coinfection in a patient with acquired immunodeficiency syndrome. *Cutis* 1994; 53: 88-90.

Accepted March 10, 1997.

Franco Alessandrini¹, Francesco Allegrini², Urbano Baldari¹ and Claudio Cancellieri²

Departments of ¹Dermatology and ²Infectious Diseases, GB Morgagni Hospital, Piazza Solieri 1, I-47100 Forlì, Italy.