

LETTERS TO THE EDITOR

Urticaria-like Follicular Mucinosis in a Young Female Patient

Sir,

Urticaria-like follicular mucinosis (FM) is a rare skin disorder, consisting of pruritic papules and plaques which are of a transient, urticarial nature, not accompanied by alopecia (1-3). To our knowledge, out of 14 patients only one woman has been reported (3).

CASE REPORT

A 28-year-old woman (nurse apprentice) presented with a history of pruritic skin lesions. The lesions developed in a continuous pattern, without clear exacerbations or remissions, and each lesion had a duration of about 1 week. There was no relation to insect bites, season, sunlight, temperature, food or menstrual cycle. The patient had no pets. Her atopy history was negative, as was her general medical history. She used an oral contraceptive medicine since 9 years, and sporadically acetylsalicylic acid, of which no provocative influence could be noticed. No other medication was used.

On examination, she showed about fifteen nummular and linear pruritic urticarial plaques on the face, upper part of the trunk and upper arms (Fig. 1). The lesions healed without atrophy or alopecia. Before these lesions appeared, there was a period of 1 year in which pruritic papules had been seen, partly excoriated, on the upper half of the body and sporadically on the legs. There were no signs of scabies.

The skin symptoms were not responsive to loratidine, cetirizine or mebhydrolyne, or to topical triamcinolon acetonide. No improvement was noticed after administration of a 4-week course of minocycline 100 mg twice daily, a 4-week course of doxycycline 100 mg twice daily in combination with nicotinamide 500 mg three times daily, a 2-week course of dapsone 100 mg per day, or 12 weeks of pentoxifylline 400 mg three times daily. Hydroxychloroquine was attempted but was stopped on account of gastro-intestinal side-effects. Currently, the patient uses betamethasone if needed every day 0.5 mg, which has been successful in healing the pruritic papules and plaques.

Histopathological examination of a 5 mm punch biopsy of an urticarial plaque showed a normal epidermis and a mixed inflammatory infiltrate in the upper half of the dermis. This infiltrate consisted of lymphocytes, histiocytes and numerous eosinophils. The localisation of the infiltrate was interstitial and perivascular, and there was pronounced infiltration around and in the pilo-sebaceous glands (Fig. 2). This infiltration was accompanied by the deposition of

moderate amounts of mucinous material, as demonstrated by positive Alcian blue staining in the sebaceous gland (Fig. 2). Direct immunofluorescence examination was negative for IgA, IgG, IgM or complement. Histopathological examination of a pruritic papule showed essentially the same abnormalities.

The following laboratory examinations were made and the results were found to be normal: ESR, haemoglobin, eosinophilic granulocytes, differential blood count, renal and liver function tests, protein fractions, cryoglobulin, antinuclear antibodies (ANA, anti-ds-DNA, ENA, SS-A), IgM rheumatoid factor, complement factors C3 and C4, TPHA, anti-streptolysine, HBsAg, anti-HBs; urine analysis (protein, glucose, microscopy); fecal analysis on worm eggs and cysts; porphyrins of serum urine and stool; bacterial cultures of pharynx, nose and urine; X-ray examination of thorax and sinus; skin prick tests on inhalation and food allergens. Epicutaneous allergy testing revealed a positive test for colophonium.

DISCUSSION

The histopathological findings in our patient were characteristic of FM (4). Striking features in our patient were the large numbers of eosinophils infiltrating the hair follicle and the marked involvement of the sebaceous glands.

Emmerson has recognized two common clinical forms of FM, namely the infiltrated plaque form, which is characterized by prominent follicular openings and usually results in hair loss, and a form with grouped follicular papules, which may resemble prurigo and occurs on the trunk and proximal parts of the limbs as well as on the face and scalp.

The pruritic papules that at first had been present in our patient therefore may be diagnosed as the prurigo form of FM. However, the histopathologically identical but clinically different pruritic urticaria-like erythematous plaques that occurred later on in our patient were strikingly different from both the prurigo form of FM and the classic infiltrated plaque form. They were similar to the lesions first described by Enjolras et al. (1) as urticaria-like FM. Urticaria-like FM has been described in middle-aged men, especially in seborrhoeic

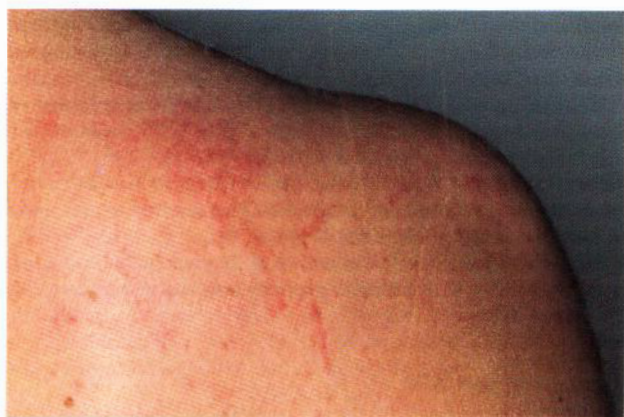

Fig. 1. A nummular and some linear pruritic urticarial plaques on the right shoulder.

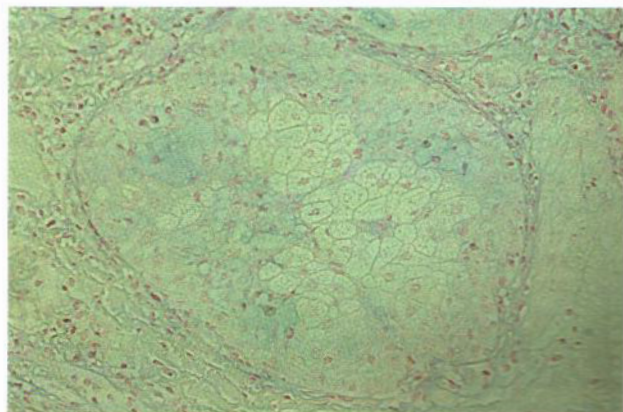


Fig. 2. Infiltration around and in a pilo-sebaceous gland, accompanied by the deposition of moderate amounts of Alcian blue positive mucinous material in the sebaceous gland. This infiltrate consisted of lymphocytes, histiocytes and numerous eosinophils.

areas (1–3). In these reports pruritic papules and plaques are of a transient, urticarial nature, not accompanied by alopecia (2, 3). Out of 14 patients only one woman has been reported (3). The histopathological features are the same as in classic FM (1–3). The sebaceous gland infiltrate consists of lymphohistiocytes and mast cells and is in some patients rich in eosinophils (1). We therefore propose this case to be urticaria-like FM in a woman. As reported previously, urticaria-like FM may be unresponsive to therapy and has a benign course (1–3).

REFERENCES

1. Enjolras O, Guillemette J, Hewit J. Dermatose ortiée folliculaire (mucinoïde folliculaire ortiée). *Ann Dermatol Venereol (Paris)* 1980; 107: 491–495.

2. Crovato F, Nazzari G, Nunzi E, Rebora A. Urticaria-like follicular mucinosis. *Dermatologica* 1985; 170: 133–135.
3. Dommergues C, Rybojad M, Menanteau Y, et al. Cas pour diagnostic. *Rev Eur Dermatol MST* 1989; 1: 431–433.
4. Emmerson RW. Follicular mucinosis. A study of 47 patients. *Br J Dermatol* 1969; 81: 395–413.

Accepted December 19, 1996.

R.A. Tupker¹, J.B. van der Meer¹, A.D. Groote², A. Hartman³, J.D. Elema⁴, M.C.J.M. de Jong¹ and T.M. Starink⁵, ¹Department of Dermatology, University Hospital, P.O. Box 30001, NL-9700 RB Groningen, Departments of ²Pathology and ³Dermatology, Martini Hospital, Groningen, ⁴Department of Pathology, University Hospital, Groningen and ⁵Department of Dermatology, Free University Hospital, Amsterdam, The Netherlands.