

Topical Calcitriol (1,25-Dihydroxyvitamin D₃) Treatment of Psoriasis: An Immunohistological Evaluation

J. REICHRATH^{1,2}, A. PEREZ¹, S. M. MÜLLER², T. C. CHEN¹, A. KERBER², F. A. BAHMER² and M. F. HOLICK¹

¹Vitamin D, Skin, and Bone Research Laboratory, Endocrinology Department of Medicine, Boston University Medical Center, Boston, MA, USA and ²Department of Dermatology, University of the Saarland, Homburg, Germany

The potent calcitropic hormone calcitriol (1,25-dihydroxyvitamin D₃, 1,25(OH)₂D₃) has been shown to be very effective and safe in the topical treatment of psoriasis. In vitro, 1,25(OH)₂D₃ inhibits proliferation and stimulates differentiation of human keratinocytes. Increasing evidence suggests an immunoregulatory function of this potent steroid hormone.

To further characterize the biological effects of topical calcitriol treatment in psoriasis, we have analyzed immunohistochemically the expression of markers for epidermal proliferation (proliferating cell nuclear antigen=PCNA) and differentiation (transglutaminase K, involucrin, cytokeratin 16), as well as inflammation (CD1a, 55 kDa TNF-receptor, NAP-1/IL-8) in calcitriol-treated psoriatic skin in situ. Our findings strongly support the hypothesis that calcitriol modulates keratinocyte proliferation/differentiation as well as inflammation in human skin in vivo. The immunoreactivity of markers for epidermal proliferation and differentiation, as well as of CD1a and NAP-1/IL-8, changed after 8 weeks of calcitriol treatment almost completely to the pattern characteristic for non-lesional psoriatic skin, while a large number of 55 kDa TNF-receptor positive cells could be found in the dermal compartment. **Key words:** calcitriol treatment; immunohistochemistry.

(Accepted November 1, 1996.)

Acta Derm Venereol (Stockh) 1997; 77: 268–272.

M. F. Holick, Ph.D., M.D., Boston University Medical Center, 80 East Concord Street, Room M-1013, Boston, MA 02118, USA.

Vitamin D is produced by UVB action in the skin, which is also a target organ for the physiologically most active vitamin D metabolite 1,25-dihydroxyvitamin D₃ (1,25(OH)₂D₃, calcitriol) (1). Recently, calcitriol and analogues have been shown to be very effective and safe in the topical treatment of psoriasis (2–4), although the exact mechanisms of action that are responsible for this efficacy are unknown.

1,25(OH)₂D₃ exerts at least part of its pleiotropic biological effects via binding to a nuclear vitamin D receptor (VDR), which is expressed in many cell types, including keratinocytes (5–7). In keratinocytes and other cell types, calcitriol increases rapidly and significantly free cytosolic calcium levels (8, 9). 1,25(OH)₂D₃ also blocks the proliferation and promotes the differentiation of human epidermal keratinocytes in vitro (10, 11). Furthermore, this potent hormone acts on the immune system (12, 13). Many cell types involved in immunologic reactions, such as Langerhans' cells, monocytes/macrophages, and activated T- and B-lymphocytes, have been shown to contain VDR (6).

To further characterize the effects of topical calcitriol treatment in psoriasis, we have analyzed immunohistochemically the expression of markers for proliferation, differentiation and

inflammation in lesional psoriatic skin after treatment with calcitriol ointment (15 µg/g vaseline) as compared to vehicle treatment (vaseline) in situ.

MATERIALS AND METHODS

Skin biopsies

After informed consent, punch biopsies (4 mm) were taken under local anaesthesia from the arms or trunk of 5 psoriatic patients (3 males, 2 females, mean age 37.2 years). These patients had not received topical or systemic treatment for at least 3 weeks. Before and during treatment, routine laboratory investigations, including parameters of calcium and phosphorus metabolism, were assessed. Two biopsies, one from a lesional area that had been treated with vehicle alone (vaseline) and the other from a corresponding lesional area that had been treated topically for 8 weeks with calcitriol (15 µg/g in vaseline, single application daily at night), were taken from each patient. Normal human skin was obtained from the arms or trunk of 6 volunteers (4 males, 2 females, mean age 38.4 years, no history of skin disease) with informed consent. Biopsies were immediately snap frozen in liquid nitrogen, embedded in Tissue Tek OCT compound (Miles scientific, Naperville, IL, U.S.A.) and stored at –70°C.

Primary antibodies

To analyze epidermal proliferation, we used a monoclonal antibody against proliferating cell nuclear antigen (PCNA, clone PC 10, Dakopatts, Copenhagen, Denmark). PCNA is synthesized during the S-phase and not expressed during the G₀ phase of the cell cycle. Association of PCNA expression with cell proliferation was demonstrated previously using immunohistochemical techniques (14). Epidermal differentiation was assessed by MoAbs against transglutaminase K (Paesel+Lorei, Frankfurt, Germany), involucrin (Paesel+Lorei, Frankfurt, Germany), and cytokeratin 16 (clone KS 8.12, Sigma, München, Germany). Clone KS 8.12 recognizes keratins 13, 15 and 16, but only cytokeratin 16 is present in suprabasal cell layers of hyperproliferative epidermis (15, 16). Cytokeratin 16 is present in non-keratinizing squamous epithelia but is absent in normal epidermis (15–17). Expression of involucrin and transglutaminase K reflects the suprabasal differentiation; both markers are present in normal human skin in the upper spinous layer and the granular layer (18, 19). Epidermal and dermal inflammation was analyzed by monoclonal antibodies against CD1a (Langerhans' cells, dendritic cells), neutrophil-activating peptide-1/interleukin-8 (NAP-1/IL-8) and 55 kDa TNF-rpt. MoAb 52E8 against NAP-1/IL-8 was a gift from Dr. M. Sticherling (Universitäts-Hautklinik Kiel, Germany); MoAb htr-9 against the 55 kDa TNF-rpt. was a gift from Dr. Brockhaus (Hoffmann La Roche, Basel, Switzerland). Expression of NAP-1/IL-8, 55 kDa TNF-rpt., and CD1a in normal and psoriatic human skin was analyzed as previously described (6, 20, 21).

Immunohistochemical staining procedure

Cryostat sections (7 µm) were fixed in 4% paraformaldehyde or acetone, and after intermediate washing steps (PBS, 10 min, RT) they were incubated with the respective primary antibodies, primary antibody-specific biotin-labelled IgG and streptavidin-peroxidase-complexes. After a final washing, the sections were treated with

3,3-diaminobenzidine, dehydrated and mounted with Entelan (Merck 7961, Darmstadt, Germany).

Quantification procedures

Microscopic analysis of markers for inflammation, proliferation and differentiation was assessed by two independent observers (JR, SM), blinded to the status of the specimens. The density scores of cells immunostained with MoAbs directed against CD1a, 55kD TNF-rpt. and PCNA were semiquantitatively enumerated by expressing the number of positively stained epidermal cells per microscopic field on a 6-point scale: 0=no cells/microscopic field labelled with corresponding antibody, 1=occasional cells/microscopic field labelled, 2=few cells/microscopic field labelled, 3=moderate number of cells/microscopic field labelled, 4=large number of cells/microscopic field labelled, 5=very large number of cells/microscopic field labelled. Involucrin, transglutaminase K, NAP-1/IL-8, and cytokeratin 16 expression was rated semiquantitatively on a 5-point scale as following: 0=no staining, 1=1–25%, 2=26–50%, 3=51–75% and 4=76–100% staining of epidermal area, respectively.

RESULTS

Clinical evaluation

Psoriatic lesions that were treated topically with calcitriol ointment (15 µg/g) showed a clinically dramatic improvement in all patients, as compared to corresponding lesional skin areas that were treated with the vehicle alone or to lesional skin before treatment. Whereas the lesion treated with vaseline showed only a modest decrease in scaling (~7%), erythema (~4%) and plaque thickness (~3%), the lesion treated daily with calcitriol ointment showed marked improvement in scaling (90 to 100%), erythema (85 to 100%) and plaque thickness (75 to 100%), as previously described (3).

Histological evaluation

Biopsies taken from vehicle-treated psoriatic plaques revealed typical histological features of lesional psoriatic skin: focal parakeratosis, psoriasiform epidermal hyperplasia, hypogranulosis, dermal papillary oedema, teleangiectasia and an intra-corneal neutrophilic infiltrate. In the upper dermal compartment (perivascular papillary loop) and the lower dermal compartment (perivascular superficial plexus and reticular dermis), very strong accumulations of lymphocytic infiltrations could be observed. In contrast, skin biopsies of psoriatic lesions treated with topical calcitriol, showed orthokeratosis, a marked reduction in epidermal thickness, a prominent granular layer with only sporadic polymorphonuclear granulocytes, and minimal perivascular lymphocytic infiltration in the upper and lower dermal compartments.

Immunohistological evaluation

Our immunohistological results demonstrate that calcitriol strongly affects proliferation and differentiation of epidermal keratinocytes in lesional psoriatic skin *in vivo*.

Transglutaminase K. In vehicle-treated psoriatic skin, immunoreactivity for transglutaminase K was observed consistently in the horny layer, the granular layer and the upper spinous layer. After 8 weeks of calcitriol treatment immunoreactivity of MoAb against transglutaminase K was markedly decreased. Epidermal immunoreactivity was found as a small band below the stratum corneum and was comparable with the staining

pattern of transglutaminase K in normal human skin (Fig. 1; data of semiquantitative evaluation are shown in Fig. 2).

Cytokeratin 16. Immunoreactivity for MoAb against cytokeratin 16 was consistently detected in all cell layers of the viable epidermis in vehicle-treated psoriatic skin. In contrast, cytokeratin 16 immunoreactivity in calcitriol-treated psoriatic skin was exclusively found in cells of the epidermal basal layer. This staining pattern was comparable to cytokeratin 16 immunoreactivity in normal human skin (data of semiquantitative analysis are shown in Fig. 2).

Involucrin. Involucrin immunoreactivity was detected in vehicle-treated psoriatic skin in all suprabasal epidermal cell layers, predominantly in upper layers. In contrast, labelling of MoAb against involucrin was found in calcitriol-treated psoriatic skin and normal human skin consistently in a small band immediately below the stratum corneum (data of semiquantitative analysis are shown in Fig. 2).

NAP-1/IL-8. Cytoplasmic immunoreactivity for NAP-1/IL-8 was detected in suprabasal epidermal cell layers of vehicle-treated psoriatic skin. Staining was pronounced in upper layers, and focally no or very weak NAP-1/IL-8 immunoreactivity was found in suprapapillary epidermal compartments (Fig. 1). In contrast, epidermal cells in suprabasal cell layers of calcitriol-treated lesional psoriatic or normal human skin revealed consistently and homogeneously strong cytoplasmic NAP-1/IL-8 immunoreactivity. (Fig. 1; data of semiquantitative analysis are shown in Fig. 2).

PCNA. In vehicle-treated psoriatic skin, a large number of PCNA-positive nuclei (Fig. 1) was shown in all viable epidermal cell layers, predominantly in lower epidermal layers. After topical calcitriol treatment, a marked decrease in PCNA-positive epidermal cells was shown. This staining pattern corresponds almost completely to the pattern characteristic for normal human skin. (Fig. 1; data of semiquantitative evaluation are shown in Fig. 3).

CD1a. After topical treatment with vehicle alone, the number of CD1a-positive cells in the epidermis was reduced as compared to calcitriol-treated lesional psoriatic or normal human skin (data of semiquantitative evaluation are shown in Fig. 3).

55 kD TNF-rpt. In vehicle-treated psoriatic skin, a large number of 55 kD TNF-rpt.-positive cells was found both in epidermal and dermal compartments. After 8 weeks of topical calcitriol treatment, a marked reduction in the number of 55 kD TNF-rpt.-positive cells in the epidermal compartment was shown, while a large number of 55 kD TNF-rpt.-positive cells remained in the upper and lower dermal compartments (data of semiquantitative analysis are shown in Fig. 3).

DISCUSSION

This study demonstrates strong evidence that topical calcitriol treatment modulates proliferation and differentiation of epidermal keratinocytes as well as inflammation in lesional psoriatic skin *in vivo*. Gerritsen et al. (22) have recently analyzed immunohistochemically the effects of treatment with 3 µg/g calcitriol in white petrolatum after 1, 4, and 8 weeks of treatment in lesional psoriatic skin. Using additional markers, we have now analyzed the effects of topical treatment with 15 µg/g calcitriol after 8 weeks of treatment in lesional psoriatic skin. Gerritsen et al. (22), using Ki-67, filaggrin, and involucrin as markers, suggested that the normalization of epidermal keratinization in psoriatic skin treated with calcitriol (3 µg/g)

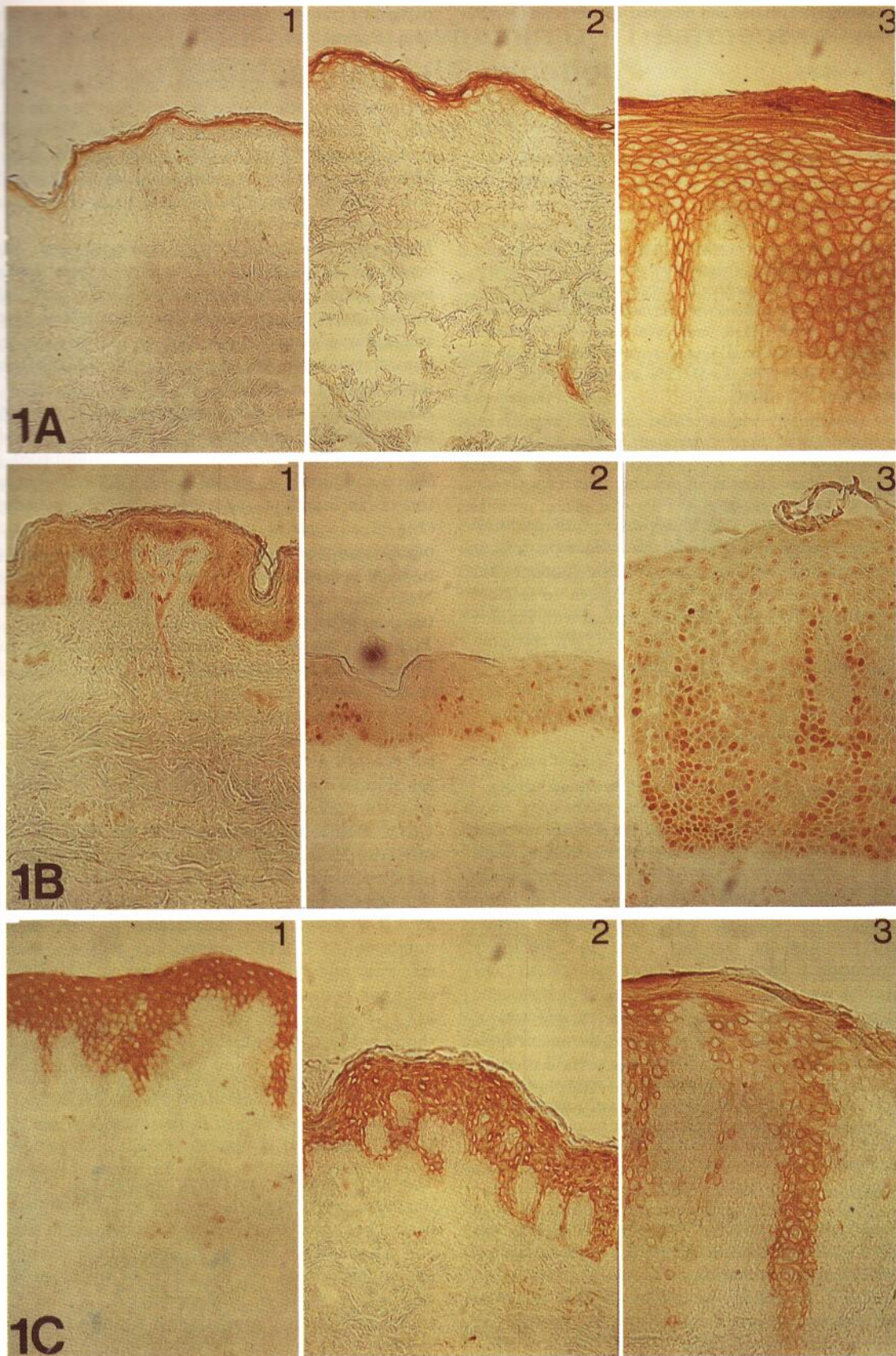


Fig. 1. Immunohistochemical demonstration of the expression of markers for differentiation, proliferation, and inflammation in corresponding lesional psoriatic skin areas after 8 weeks of topical treatment with calcitriol (15 µg/g in vaseline) or the vehicle alone. MoAbs against transglutaminase K (A), PCNA (B), and NAP-1/IL-8 (C) are shown (1 = normal human skin, 2 = calcitriol-treated, 3 = vehicle-treated). Original magnification × 200.

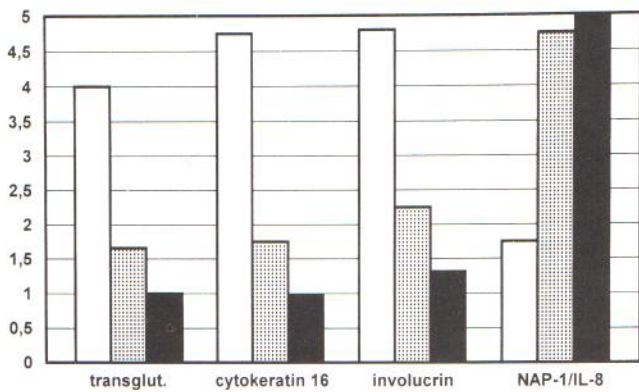


Fig. 2. Semiquantitative analysis of markers for differentiation (transglutaminase K, cytokeatin 16, involucrin) and inflammation (NAP-1/IL-8). Abscissa shows means of stained epidermal area on a 5-point scale, as described in Methods: 0=no staining; 1=1–25%; 2=26–50%; 3=51–75% and 4=76–100%. □: vehicle-treated; ▨: calcitriol-treated; ■: normal skin.

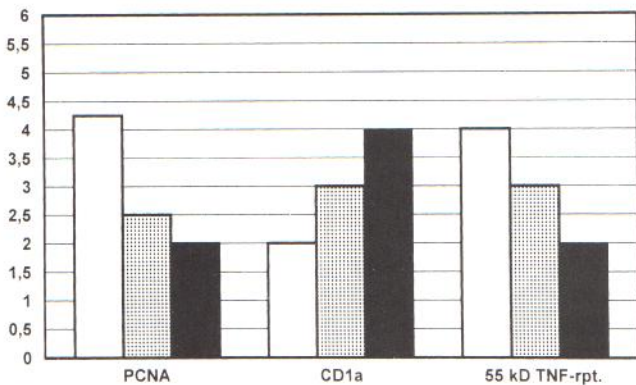


Fig. 3. Semi-quantitative analysis of CD1a, PCNA and 55 kD TNF-rpt. Abscissa shows means from density scores of immunostained cells that were semiquantitatively estimated by expressing the number of positively stained epidermal cells on a 6-point scale as described in Methods. □: vehicle-treated; ▨: calcitriol-treated; ■: normal skin.

follows reduction of epidermal proliferation. Our immunohistochemical analysis, using PCNA, transglutaminase K, involucrin, and cytokeatin 16 as markers, confirms the dramatic effects of topical calcitriol treatment on proliferation and differentiation in lesional psoriatic skin *in vivo*. However, it is not known whether there are additional effects of calcitriol which might have directly or indirectly affected these changes. Increasing evidence suggests an immunomodulating function of calcitriol (12, 13), and recent work has emphasized the importance of immunologic mechanisms involving release of cytokines by activated T cells, macrophages and keratinocytes in the pathogenesis of psoriasis (23, 24). We analyzed the expression of NAP-1/IL-8 and 55 kDa TNF-receptors, for these cytokines and corresponding receptors are suggested to be involved in the pathogenesis of psoriasis (21, 23, 24). IL-1 induced IL-8 expression was recently shown to be regulated by calcitriol in human epidermal keratinocytes at the mRNA and protein level *in vitro* (25). In the myeloid cell line U 937, calcitriol has been shown to increase TNF α gene expression (26).

Our results indicate that topical calcitriol treatment might enhance immunosuppressive and anti-inflammatory pathways

in lesional psoriatic skin. Other groups recently demonstrated modulation of proliferation, differentiation, and inflammation in lesional psoriatic skin during topical treatment with the vitamin D analogue calcipotriol (MC 903) (27–29).

Under our experimental conditions, the effects on inflammation seemed to be stronger in the epidermal as compared to the dermal compartment. After 8 weeks of topical calcitriol treatment, the immunoreactivity for NAP-1/IL-8 changed in the epidermis almost completely, to the pattern characteristic for non-lesional psoriatic or normal human skin. A marked reduction in the number of 55 kDa TNF-rpt.-positive cells and a marked increase in the number of CD1a-positive cells were found in the epidermal compartment of calcitriol treated lesional psoriatic skin. Langerhans' cells were recently shown to be immunoreactive for VDR (6). It would be interesting to know whether the function and differentiation of Langerhans' cells are modulated by calcitriol, as recently shown for monocytes and macrophages (13).

The staining pattern of MoAb against 55 kDa TNF-receptor in the dermal compartment did not change to the pattern characteristic for non-lesional psoriatic or normal human skin. One reason for the less pronounced effects of topical calcitriol-treatment on the number of 55 kDa TNF-rpt.-positive cells in the dermal, as compared to the epidermal compartment, may be that the bioavailability of this potent hormone in the dermal compartment is markedly reduced as compared to the epidermal compartment.

In conclusion, our results strongly support the hypothesis that topical calcitriol treatment affects epidermal proliferation and differentiation *in vivo*. We analyzed the expression of PCNA, transglutaminase K and cytokeatin 16 in psoriatic skin treated with calcitriol (15 μ g/g). This potent seco-steroid hormone revealed strong effects on the expression of NAP-1/IL-8 and CD1a, indicating an immunoregulatory function. But the effects on dermal inflammation were less pronounced. After 8 weeks of topical calcitriol treatment, a large number of 55 kDa TNF-rpt.-positive inflammatory cells was still found in the dermal compartment, indicating that dermal lymphocytes are not the primary target cells for topical calcitriol treatment. This may be due to a reduced bioavailability of calcitriol along with topical treatment in the dermal compartment as compared to the epidermis.

ACKNOWLEDGEMENT

This work was supported in part by a grant from the Deutsche Forschungsgemeinschaft (Re/1–1) and by NIH grants # M01 RR 00533 and AR 36963.

REFERENCES

- Holick MF, Chen ML, Kong XF, Sanan DK. Clinical uses for calcitropic hormones 1, 25-dihydroxyvitamin D₃ and parathyroid-hormone related peptide in dermatology: a new perspective. *J Invest Dermatol* 1996; 1: 1–9.
- Bourke JF, Berth-Jones J, Iqbal SJ, Hutchinson PE. High-dose topical calcipotriol in the treatment of extensive psoriasis vulgaris. *Br J Dermatol* 1993; 129: 74–76.
- Perez A, Chen TC, Turner A, Raab R, Bhawan J, Poche P, et al. Efficacy and safety of topical calcitriol (1,25-dihydroxyvitamin D₃) for the treatment of psoriasis. *Br J Dermatol* 1996; 134: 238–246.
- Kragballe K, Beck HI, Sogaard H. Improvement of psoriasis by

- a topical vitamin D analogue (MC 903) in a double blind study. *Br J Dermatol* 1988; 119: 223–230.
5. Stumpf WE, Sar M, Reid FA, Tanaka Y, De Luca HF. Target cells for 1,25-dihydroxyvitamin D₃ in intestinal tract, stomach, kidney, skin, pituitary and parathyroid. *Science* 1979; 206: 1189–1190.
 6. Milde P, Hauser U, Simon T, Mall G, Ernst V, Haussler MR, et al. Expression of 1,25-dihydroxyvitamin D₃ receptors in normal and psoriatic skin. *J Invest Dermatol* 1991; 97: 230–239.
 7. Baker AR, Mc Donnell DP, Hughes M, Crisp TM, Mangelsdorf DJ, Haussler MR, et al. Cloning and expression of full-length cDNA encoding human vitamin D receptor. *Proc Natl Acad Sci USA* 1988; 85: 3294–3298.
 8. MacLaughlin JA, Cantley LC, Holick MF. 1,25(OH)₂D₃ increases calcium and phosphatidylinositol metabolism in differentiating cultured human keratinocytes. *J Nutr Biochem* 1990; 1: 81–87.
 9. Bittiner B, Bleehen SS, Mac Neil S. 1,25(OH)₂ vitamin D₃ increases intra-cellular calcium in human keratinocytes. *Br J Dermatol* 1991; 124: 12230–12235.
 10. Matsumoto K, Azuma Y, Kiyoki M, Okumura H, Hashimoto K, Yoshikawa K. Involvement of endogeneously produced 1,25-dihydroxyvitamin D₃ in the growth and differentiation of human keratinocytes. *Acta Biochem Biophys* 1991; 1092: 311–318.
 11. Smith EL, Walworth NC, Holick MF. Effect of 1,25-dihydroxyvitamin D₃ on the morphologic and biochemical differentiation of cultured human epidermal keratinocytes grown in serum-free conditions. *J Invest Dermatol* 1986; 86: 709–714.
 12. Rigby WFC. The immunobiology of vitamin D. *Immunol Today* 1988; 9: 54–58.
 13. Texerau M, Viac J. Vitamin D, immune system and skin. *Eur J Dermatol* 1992; 2: 258–264.
 14. Hall PA, Levison DA, Woods AL, Yu CC-W, Kellock DB, Watkins JA, et al. Proliferating cell nuclear antigen (PCNA) immunolocalization in paraffin sections: an index of cell proliferation with evidence of deregulated expressions in some neoplasms. *J Pathol* 1990; 162: 285–294.
 15. Huszar M, Gigi-Leitner O, Moll R, Franke WW, Geiger B. Monoclonal antibodies to various acidic (type I) cytokeratins of stratified epithelia. Selective markers for stratification and squamous cell carcinomas. *Differentiation* 1986; 31: 141–153.
 16. Kallionen M, Koivukangas V, Jarvinen M, Oikarinen A. Expression of cyto-keratins in regenerating human epidermis. *Br J Dermatol* 1995; 133: 830–835.
 17. Gigi-Leitner I, Geiger B, Levy R, Czernobilsky B. Cytokeratin expression in squamous metaplasia of the human uterine cervix. *Differentiation* 1986; 31: 191–205.
 18. Kanitakis J, Zambruno G, Viac J, Thivolet J. Involucrin expression in keratinization disorders of the skin—a preliminary study. *Br J Dermatol* 1987; 117: 479–486.
 19. Schroeder WT, Thacher SM, Stewart-Galetka S, Annabelle M, Chema D, Siciliano MJ, et al. Type I keratinocyte transglutaminase: expression in human skin and psoriasis. *J Invest Dermatol* 1992; 99: 27–34.
 20. Reichrath J, Müller SM, Kerber A, Baum HP, Bahmer FA. Biological effects of topical calcipotriol (MC 903) treatment in psoriatic skin. *J Am Acad Dermatol* 1997; 86: 19–28.
 21. Sticherling M, Bornscheuer E, Schröder JM, Christophers E. Localisation of neutrophil-activating-peptide-1/IL-8 immunoreactivity in normal and psoriatic skin. *J Invest Dermatol* 1991; 96: 26–30.
 22. Gerritsen MJP, Rulo HFC, Van Vlijmen-Willems I, Van Erp PEJ, Van de Kerkhof PCM. Topical treatment of psoriatic plaques with 1,25-dihydroxy-vitamin D₃: a cell biological study. *Br J Dermatol* 1993; 128: 666–673.
 23. Gottlieb AB. Immunologic mechanisms in psoriasis. *J Am Acad Dermatol* 1988; 18: 1376–1380.
 24. Valdimarsson H, Baker BS, Jonsdottir I, Fry L. Psoriasis: a disease of abnormal keratinocyte proliferation induced by T-lymphocytes. *Immunol Today* 1988; 7: 256–259.
 25. Larsen CG, Kristensen M, Paludan K, Deleuran B, Thomsen MK, Zacharia EC, et al. 1,25(OH)₂D₃ is a potent regulator of interleukin-1 induced interleukin-8 expression and production. *Biochem Biophys Res Commun* 1991; 176: 1020–1026.
 26. Bhalla AK, Paavohenen T, Williams MM, Delves PJ, Lydyard PM. Regulation of interleukin-1 and tumor necrosis factor gene expression in myelomonocytic cell lines by 1,25-dihydroxyvitamin D₃. *Immunology* 1991; 72: 61–66.
 27. De Jong EMGJ, Van de Kerkhof PCM. Simultaneous assessment of inflammation and epidermal proliferation in psoriatic plaques during long term treatment with vitamin D analogue MC 903: modulations and interrelations. *Br J Dermatol* 1991; 124: 221–229.
 28. De Mare S, De Jong EMGJ, Van de Kerkhof PCM. DNA content and Ks 8.12 binding of the psoriatic lesion during treatment with the vitamin D₃ analogue MC 903 and betamethasone. *Br J Dermatol* 1990; 123: 291–295.
 29. Berth-Jones J, Fletcher A, Hutchinson PE. Epidermal cytokeratin and immunocyte response during treatment of psoriasis with calcipotriol and betamethasone valerate. *Br J Dermatol* 1992; 126: 356–361.