

Cutaneous Infection due to *Mycobacterium abscessus*

A Case Report

M. T. E. VOGELS¹, V. C. G. TJAN-HEIJNEN², J. A. C. ALKEMADE³, L. V. A. M. BEEX² and H. L. MUYTJENS¹

Departments of ¹Medical Microbiology, ²Endocrinology, and ³Dermatology, University Hospital Nijmegen, The Netherlands

Erythematous nodular and ulcerating skin lesions occurred in a 56-year-old woman treated with chemotherapy and glucocorticosteroids for metastatic breast cancer. Subsequent culture yielded *Mycobacterium abscessus*, a facultative pathogen which exists as a saprophyte in the environment and rarely produces clinical disease in humans. This organism is usually relatively resistant to antituberculous as well as a number of other antimicrobial agents. On the basis of in vitro susceptibility results, treatment with clarithromycin and clofazimine was installed and resolution of the lesions initiated.

This report emphasizes once again that one should investigate any new or unusual skin lesions in immunocompromised patients by histology and culture of biopsies, including cultures for acid-fast organisms. **Key word: immunocompromised patient.**

(Accepted October 17, 1996.)

Acta Derm Venereol (Stockh) 1997; 77: 222–224.

M. T. E. Vogels, Dept. of Medical Microbiology, P.O. Box 9101, 6500 HB Nijmegen, The Netherlands.

Nontuberculous (atypical or environmental) mycobacteria have long remained in the shadow of *M. tuberculosis*, *M. bovis* and *M. leprae*. But partially because of growing numbers of immunocompromised patients, these facultative pathogens are now enjoying increased interest.

M. abscessus is widespread in soil, dust and water and may be found as a contaminant of clinical specimens or transiently colonizing body surfaces and secretions (1–4). It is much less fastidious than most other clinically important mycobacteria.

The spectrum of human disease, which is usually opportunistic, varies widely, and ranges from posttraumatic local cutaneous lesions to osteomyelitis, pulmonary nodules, endocarditis, postsurgical sepsis and disseminated illness (3–6). Cutaneous infections are the most frequently encountered lesions. They occur primarily as abscesses, which usually result from trauma, such as with injections, following surgery, or after accidental injury (3–5, 7, 8). *M. abscessus* cutaneous infection without a history of preceding trauma developed in the immunocompromised patient described here. Diagnostic and therapeutic considerations are discussed.

CASE REPORT

In our patient, at the age of 51 years, breast cancer was diagnosed, which was treated surgically followed by radiotherapy and adjuvant therapy with 5-fluorouracil and tamoxifen. During the next 4 years, metastases in mediastinal lymph nodes, liver, and bones were diagnosed and treated with radiotherapy, tamoxifen and exemestane. Five years after her primary tumour, a cerebellar metastasis was diagnosed, for which she received radiotherapy and dexamethasone in dosages up to 14 mg/day for 4 months. In addition and in view of progressive mediastinal disease, a first course of chemotherapy with cyclophosphamide, methotrexate and 5-fluorouracil was given during this period.

Shortly after this course she was admitted because of increasing fatigue, loss of muscle strength and dyspnoea, which rendered her bedridden. Her treatment at this point still included dexamethasone 1.5 mg/day. On physical examination, she had central adipositas, striae and several hematomas. There was no adenopathy. Multiple tender erythematous nodules on both upper legs and buttocks were observed, which had developed during the previous weeks.

During her 7-week hospital stay she received a second and third course of chemotherapy, in a reduced dosage because of development of profound pancytopenia. One week after her admission, the patient developed a period of fever which lasted 1 month, for which no clear explanation was found.

Results of routine laboratory examinations on admission included an ESR 27 mm/hr, hemoglobin of 8.2 mmol/l, and leukocytes $0.8 \times 10^9/l$, with a normal distribution.

Chest radiographs showed left hilar enlargement due to metastasis, some pleural effusion on the left and no infiltration or cavitation. Differential diagnosis of the skin lesions included paraneoplastic panniculitis, erythema nodosum, metastatic or infectious disease. Biopsy of the skin lesions showed a lobular granulocytic-monocytic inflammatory infiltrate with local necrosis but without granulomas, vasculitis or signs of malignancy. Under the presumptive diagnosis of paraneoplastic panniculitis (9), treatment with prednisone (40–60 mg/d) was given. However, the number of lesions increased.

After a short dismissal (on prednisone 20 mg/d), the patient was readmitted, and more generalized skin lesions were observed, some ulcerating (Fig. 1). A new and deeper skin biopsy revealed essentially the same histology as previously, but in addition some histiocytary cells and some polynuclear giant cells of the Langerhans' type. A Ziehl Neelsen stain was performed and numerous acid-fast bacilli were seen in the necrotic areas (Fig. 2). Cultures were taken. The pulmonary X-ray was unchanged as compared to 2 months earlier. Puncture of the pleura fluid yielded a normal cytology, and a Ziehl Neelsen stain was negative. Urine culture for mycobacteria was negative. Examination of the eyes revealed no abnormalities. She was initially treated with isoniazide (300 mg/day), rifampicin (600 mg/day), pyrazinamide (2 g/day), pyridoxine (20 mg/day) and ethambutol (2 g/day) for several weeks, and therapy with glucocorticosteroids was discontinued, but the skin lesions progressed. Routine bacteriologic and fungal cultures revealed no superinfection. Cultures for mycobacteria were positive after 1 week. Successive determination yielded *M. abscessus*, which was not sensitive in vitro to any tuberculostatic drug or to amikacin, ciprofloxacin and erythromycin, but which was sensitive to clarithromycin and clofazimine. Therefore, tuberculostatic therapy was stopped and oral therapy with clarithromycin (500 mg bid) and clofazimine (200 mg/48 h) was started.

Her lesions regressed over the subsequent month, and cultures for mycobacteria taken 2 weeks after the start of therapy were negative.

At this point, deterioration of her clinical condition, with complete bedridden hospitalization, made the patient express her wish to withdraw all medical therapy, and shortly afterwards she died. Although postmortem investigation was not allowed, her death was not considered due to direct complications of the *M. abscessus* infection, in view of the low virulence of this *Mycobacterium* and the response of the skin lesions to therapy.

DISCUSSION

Nowadays, serious infections with normally apathogenic microorganisms represent an increasing problem, because host

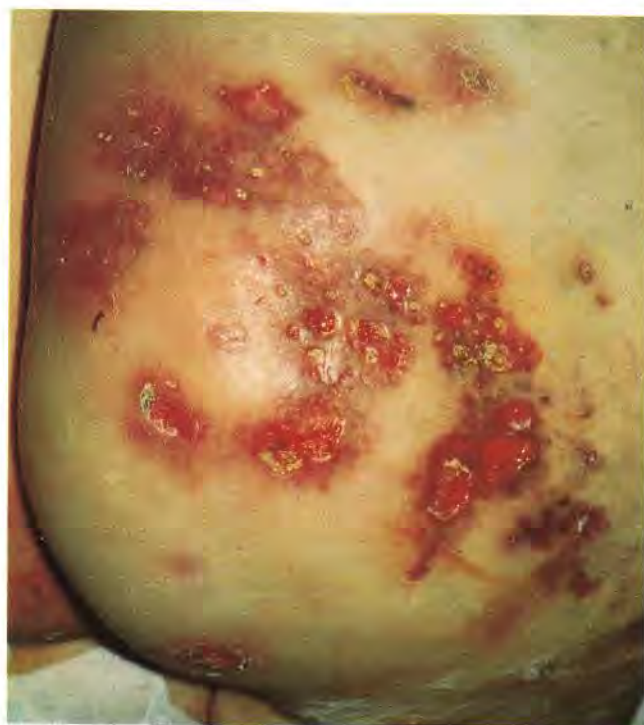


Fig. 1. Extensive ulcerating lesions on nates.

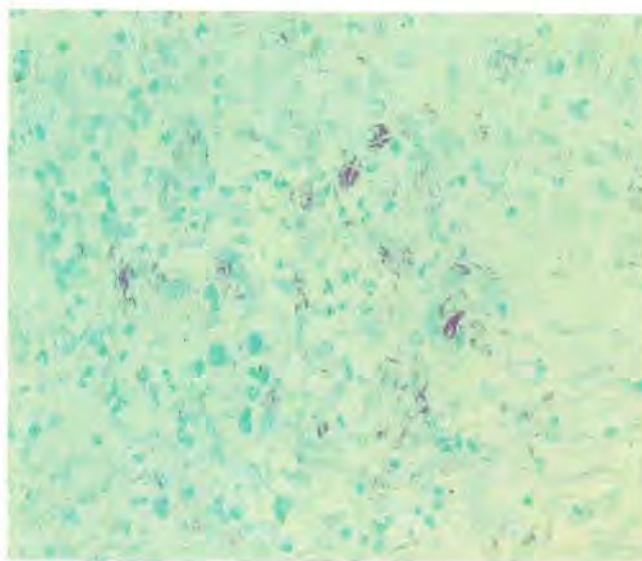


Fig. 2. Ziehl Neelsen stain of biopsy with numerous acid-fast bacilli.

defenses are compromised in a growing number of patients (e.g. due to cancer chemotherapy, immunosuppressive therapy and AIDS). Cutaneous lesions in this type of patient should alert the clinician not only to the possibility of noninfectious causes, such as malignancy, but also to the possibility of infection by opportunistic micro-organisms, including atypical mycobacteria.

In immunocompromised patients, skin lesions due to *M. abscessus* can occur without a history of trauma, and generally present as persisting subcutaneous, sometimes tender nodules that may progress to ulcers, yielding purulent material. Regional lymphadenopathy and general symptoms like fever

and fatigue sometimes occur (6, 8). The period of fever in our patient may be explained by the cutaneous infection. There is no evidence for person-to-person spread of atypical mycobacteria, although wound isolation is advised in cutaneous disease (1, 5, 10).

Diagnosis involves histologic examination and culture for acid-fast micro-organisms of biopsy specimens.

Histology may show a broad spectrum of possible inflammatory responses (4, 5, 8). Characteristic tuberculoid granulomas sometimes occur, but more often there is a dimorphic inflammatory response showing both acute inflammation and chronic inflammation with foreign body giant cells and/or Langerhans' cells. Necrosis is usually present, but it is rarely caseous. Results of Ziehl Neelsen staining are usually, but not always, positive (5). When acid-fast stains are not performed or when the result is negative, the lesions may easily be misdiagnosed as erythema nodosum or as noninfectious panniculitis (8, 9), as initially occurred in our patient.

Definitive diagnosis depends on culture of the mycobacteria. Unfortunately, it is often delayed, not only because of the lack of familiarity with the atypical mycobacteria and the usually aspecific histology, but also because of the often slow initial growth on initial isolation (2 to 30 days). It is crucial to aseptically obtain cutaneous biopsy specimens, preferably not only from ulcers but also from intact subcutaneous lesions. Tuberculin PPD skin tests are usually negative in *M. abscessus* infections (7, 8, 11); therefore, specific antigens should be used (11, 12).

Additional diagnostics to evaluate generalization include cultures of blood, urine and sputum, although *M. abscessus* may colonize respiratory secretions without a role in disease (1, 10).

Antimicrobial therapy and/or surgery is sometimes necessary in immunocompetent patients and is usually indicated in immunosuppressed patients (10). Surgical debridement may yield good results but is difficult to realize in the case of extensive lesions (5, 7, 8). Antimicrobial therapy is often difficult, since *M. abscessus* is usually resistant in vitro against all tuberculostatics. The micro-organism may be susceptible to agents commonly used for pyogenic bacterial infections, especially for clarithromycin, amikacin, cefoxitin and imipenem (1, 3, 6, 13, 14). There are some studies reporting the efficacy of clofazimine on *M. abscessus* (15, 16). Selection of agents should be guided by results of in vitro susceptibility tests.

Although monotherapy with clarithromycin has been described to produce good results without the development of resistance (6, 14, 17), in mycobacterial infections, single-drug therapy should be avoided to reduce the emergence of drug resistance (5, 13, 14). Though 2–4 weeks of therapy is usually sufficient to resolve cutaneous lesions, 3 months' therapy is probably required to reduce relapse rates (1, 3, 4).

In conclusion, delay of diagnosis of disease due to atypical mycobacteria often occurs. The case reported in this study illustrates this. Greater knowledge of the clinical picture and risk factors, like immunosuppression, is necessary.

Since atypical mycobacteria are ubiquitous, and the numbers of immunocompromised patients are rising, it is very likely that in the future infections by these pathogens will be encountered even more often.

REFERENCES

- Horowitz EA, Sanders WE. Other mycobacterium species. In: Mandell GL, Bennett JE, Dolin R, eds. Principles and practice of infectious diseases. 4th edn. 1995: 2265–2273.
- Wolinski E. Nontuberculous mycobacteria and associated diseases. *Am Rev Respir Dis* 1979; 119: 107–159.
- Wallace RJ Jr, O'Brien R, Glassroth J, et al. Diagnosis and treatment of disease caused by nontuberculous mycobacteria. *Am Rev Resp Dis* 1990; 142: 940–953.
- Woods GL, Washington JA II. Mycobacteria other than *Mycobacterium tuberculosis*: review of microbiologic and clinical aspects. *Rev Infect Dis* 1987; 9: 275–294.
- Wallace RJ, Jr, Swenson JM, Silcox VA, Good RC, Tschen JA, Stone MS. Spectrum of disease due to rapidly growing mycobacteria. *Rev Infect Dis* 1983; 5: 657–679.
- Ingram CW, Tanner DC, Durack DT, Kernodle GW, Jr, Corey GR. Disseminated infection with rapidly growing mycobacteria. *Clin Infect Dis* 1993; 16: 463–471.
- Borghans JGA, Stanford JL. *Mycobacterium chelonae* in abscesses after injection of Diphtheria-Pertussis-Tetanus-Polio vaccine. *Am Rev Resp Dis* 1973; 107: 1–8.
- Beyt BE, Jr, Ortbals DW, Santa Cruz DJ, Kobayashi GS, Eisen AZ, Medoff G. Cutaneous mycobacteriosis: analysis of 34 cases with a new classification of the disease. *Medicine* 1980; 60: 95–109.
- Winkelman RK, Grado GL, Quimby SR, Connolly SM. Pseudosclerodermatous panniculitis after irradiation: an unusual complication of megavoltage treatment of breast carcinoma. *Mayo Clin Proc* 1993; 68: 122–127.
- Brown TH. The rapidly growing mycobacteria – *Mycobacterium fortuitum* and *Mycobacterium chelonae*. *Infection Control* 1985; 6: 283–288.
- Ward JM. *M. fortuitum* and *M. chelonae*-fast growing mycobacteria. A review with a case report. *Br J Dermatol* 1975; 92: 453–459.
- Hoffman PC, Fraser DW, Hinson PL. Delayed hypersensitivity reactions in patients with *Mycobacterium chelonae* and *Mycobacterium fortuitum* infections. *Am Rev Resp Dis* 1978; 117: 527–531.
- Carpenter JL, Troxell M, Wallace RJ, Jr. Disseminated disease due to *Mycobacterium chelonae* treated with Amikacin and Cefoxitin. Absence of killing with either agent and possible role of granulocytes in clinical response. *Arch Intern Med* 1984; 144: 2063–2065.
- Brown BA, Wallace RJ, Jr, Onyi GO, De Rosas V, Wallace RJ III. Activities of four macrolides, including Clarithromycin, against *Mycobacterium fortuitum*, *Mycobacterium chelonae*, and *M. chelonae*-like organisms. *Antimicrob Agents Chemother* 1992; 36: 180–184.
- Cooper JF, Lichtenstein MJ, Graham BS, Schaffner W. *Mycobacterium chelonae*: a cause of nodular skin lesions with a proclivity for renal transplant recipients. *Am J Med* 1989; 86: 173–177.
- Ausina V, Condom MJ, Mirelis B, Luquin M, Coll P, Prats G. In vitro activity of clofazimine against rapidly growing nonchromogenic mycobacteria. *Antimicrob Agents Chemother* 1986; 29: 951–952.
- Wallace RJ, Tanner D, Brennan PJ, Brown BA. Clinical trial of clarithromycin for cutaneous (disseminated) infection due to *Mycobacterium chelonae*. *Ann Intern Med* 1993; 119: 482–486.