

Histopathological Findings, Viral DNA Distribution and Lymphocytic Immunophenotypes in Vesicular and Papular Types of Herpes Zoster

JONG YUK YI, TAE YOON KIM, JAE HONG SHIM, BAIK KEE CHO and CHUNG WON KIM

Department of Dermatology, Catholic University Medical College, Seoul, Korea

The characteristic rash of herpes zoster begins as erythematous macules and papules, progressing to vesicles within 12–24 h. Patients with persistent papules without vesicular change are occasionally found. Our aim was to elucidate differences in vesicular and papular types of herpes zoster.

Biopsy specimens from 21 patients were examined by an *in situ* hybridization method to observe viral distribution, and lymphocytic immunophenotypes were evaluated immunohistochemically.

There were no differences in cell-mediated immunity or immunophenotypes in lymphocytic infiltrates between vesicular and papular types of herpes zoster. DNA of varicella-zoster virus was detected in the epidermis and hair follicles in the vesicular type but was found only in the pilosebaceous unit in the papular type. This indicates that the appearance of clinical types of herpes zoster depends on the infected site of varicella-zoster virus in the tissue. **Key words:** distribution of DNA; varicella-zoster virus.

(Accepted November 9, 1996.)

Acta Derm Venereol (Stockh) 1997; 77: 194–197.

J. Y. Yi, Department of Dermatology, UijongBu St. Mary's Hospital, Catholic University Medical College, 65–1 KumOh-dong, UijongBu-city, KyungGi-do 480–130, Korea.

The characteristic rash of herpes zoster begins as erythematous macules and papules within the affected dermatome. These lesions progress to vesicles within 12–24 h, to pustules in 3–4 days, and to crusts in 7–10 days. Occasionally patients are found who have persistent papules without vesicular change. We have been unable to find any report on the papular type of herpes zoster to this date.

The mechanisms regulating the reactivation of latent varicella-zoster virus (VZV) are not well understood. It is hypothesized that cell-mediated immunity (CMI) normally suppresses VZV activity and maintains viral latency. A decline in VZV-specific CMI is associated with reactivation of the latent virus (1). This association is supported by the increased incidence of herpes zoster among individuals with CMI defects, including the elderly and persons with organ transplants, internal malignancy and HIV infection. It may be assumed that the difference in clinical features of herpes zoster may be due to the difference in immune response of host to virus.

To demonstrate differences between vesicular and papular types of herpes zoster, we compared CMI to several recall antigens, histopathological findings, viral distribution and immunophenotypes of lymphocytic infiltrate.

MATERIALS AND METHODS

Clinical specimens

Twenty-one patients with clinical and histopathological evidence of herpes zoster were included in this study. Thirteen of the patients (4 men and 9 women; age range 18–79 years) showed typical grouped vesicles (vesicular type of herpes zoster) and the other 8 patients (3 men and 5 women; age range 32–66 years) showed only persistent grouped papules (Fig. 1). They had not experienced such lesions earlier. The papular lesions of the patients enrolled in this study did not show vesicular change at follow-up 1 week later. The duration of papular lesions was 3 to 7 days at biopsy. Skin biopsies were obtained from lesions distributed in the area without terminal hair, embedded in O.C.T. compound (Miles laboratories, Naperville, IL), snap-frozen in liquid nitrogen and stored at -70°C until use.

Evaluation of CMI

A Multitest[®] CMI kit (Merieux Institute, Miami, Florida), consisting of seven recall antigens, was used as means of assessing CMI (Table I). Application was made on the volar surface of one forearm and test sites were evaluated 48 h after administration. A reaction was considered positive when the average diameter of an induration in two measurements appeared 2 mm or greater at any of the seven test sites. Measurements of the width and length of the induration were made

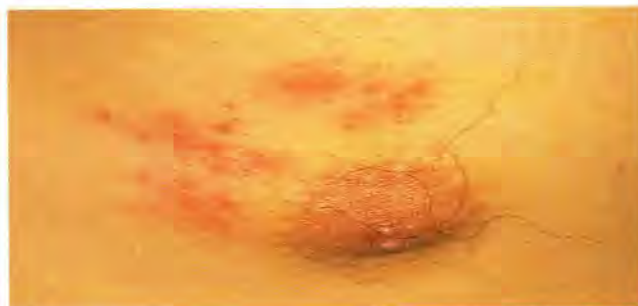

Fig. 1. Clinical features of the papular type of herpes zoster.

Table I. Test antigens employed in Multitest CMI[®]

1	<i>Tetanus toxoid</i>	550,000 Merieux units/ml
2	<i>Diphtheria toxoid</i>	1,100,000 Merieux units/ml
3	<i>Streptococcus antigen (group C)</i>	2,000 Merieux units/ml
4	<i>Old tuberculin</i>	300,000 IU/ml
5 ^a	<i>Glycerin control solution</i>	70% w/v
6	<i>Candida antigen (albicans)</i>	2,000 Merieux units/ml
7	<i>Trichophyton antigen (mentagrophytes)</i>	150 Merieux units/ml
8	<i>Proteus antigen (mirabilis)</i>	150 Merieux units/ml

^a Control.

at right angles to each other. The score was expressed as the sum of average diameters of all positive reactions.

Histopathological and immunohistochemical examinations

Serial 5- μ m sections were placed on microslides coated with poly-L-lysine (Sigma Chemical, St. Louis, MO) and fixed in chilled acetone for 10 min. Some sections of each specimen were stained with hematoxylin and eosin. For the immunohistological analysis, the sections were incubated with mouse monoclonal antibodies (CD3 1:200, CD4 1:50, CD8 1:50, CD25 1:25 and CD45RO prediluted). The samples were processed for staining with an immunoperoxidase technique (Histostain-SP[®] Kit, Zymed Laboratories, San Francisco, Calif.), with 3-amino-9-ethyl carbazole as the chromogen, counterstained with hematoxylin and wet-mounted with Aquamount (Lerner Laboratories, Pittsburgh).

In situ hybridization

To see the localization of VZV DNA in the tissue, in situ hybridization method was used with Ultra Dig system (Kreatech Biotechnology, Amsterdam, Netherlands). Five- μ m sections were placed on slides coated with 3-aminopropyl-triethoxysilane (Sigma) and fixed in 4% paraformaldehyde in phosphate-buffered saline (PBS) for 20 min. Slides were transferred to PBS for 5 min and incubated with pepsin in 0.01N HCl for 10 min. Sections were then dehydrated in graded ethanol and air-dried. Prehybridization and hybridization were performed in a buffer containing 50% deionized formamide, 2X SSC (1X SSC=0.15 M sodium citrate, 15 mM sodium chloride), 10% dextran sulfate, 10% Denhardt's solution, 0.5% Tween-20, 250 μ g/ml salmon sperm carrier DNA. For prehybridization 10 μ l of hybridization buffer was applied to the sections prior to adding coverslips. The slides were incubated at 37°C for 30 min. The coverslips were removed in Tris-buffered saline (TBS: 0.1 M Tris-HCl, 0.15 M NaCl, pH 7.5) and the sections were washed in two changes of TBS for 3 min, followed by dehydration in graded ethanol and air-drying. For hybridization, 10 μ l of hybridization buffer including 1 μ g/ml positive probe or negative control probe was applied, and the sections were covered with coverslips. The slides were placed on a hot plate (90°C) for 2 min and incubated for 4 h at 37°C. After hybridization, the coverslips were removed in 2 \times SSC and sections were washed in three changes of 1 \times SSC/50% formamide for 10 min each. The slides were rinsed in TBS. Anti-digoxigenin antibody coupled to alkaline phosphatase (Boehringer Mannheim Biochemicals, Mannheim, Germany) was added and the slides were incubated for 1 h, followed by addition of Stable Fast Red TR/Stable Naphthol Phosphate (Research Genetics, Huntsville, Alabama). VZV DNA and vector DNA probes labelled with digoxigenin were purchased from Kreatech Biotechnology. We performed in situ hybridization with this probe in the lesions of herpes simplex to see a possible crossreactivity to herpes simplex virus. It was not found to have crossreactivity to herpes simplex virus.

Quantification of immunostaining

Slides stained with monoclonal antibodies were evaluated by counting the cells in four high-power fields (objective \times 40) with an ocular grid (1 \times 1 cm) in the dermis. Positive and negative cells were counted, and the results were expressed as mean percentage per field.

Statistical analysis

Unpaired *t*-test was used to compare all data between vesicular and papular types. Results with a difference of $P < 0.05$ were considered statistically significant. Summary data was expressed as means \pm S.D.

RESULTS

CMI

The scores of Multitest CMI examination were 7.7 ± 3.8 mm in the vesicular type and 8.5 ± 4.1 mm in the papular type, but the differences were not statistically significant.

Histopathological features

Epidermal vesicles, including ballooned cells and multinucleate giant cells, were present in all 13 cases of the vesicular type. In four cases of vesicular type, in which a hair follicle was connected or thought to be connected to an epidermal vesicle, necrotic epithelium without vesicle formation in the middle or lower portion of the hair follicle was observed. Epithelial cells of follicular infundibulum were involved in the formation of epidermal vesicles with keratinocytes. Necrosis of pilosebaceous units without formation of epidermal vesicles and ballooned and/or multinucleate giant cells in the necrotic area were found in 7 cases of the papular type (Fig. 2). In one case of the papular type, no pilosebaceous unit was in the sections. Spongiotic changes, with minute vesicular formation, were observed in the hair follicles in one case of the papular type.

Distribution of VZV DNA

VZV DNA was observed in intravesicular and perivesicular areas of epidermis in all 13 cases of the vesicular type (Fig. 3).

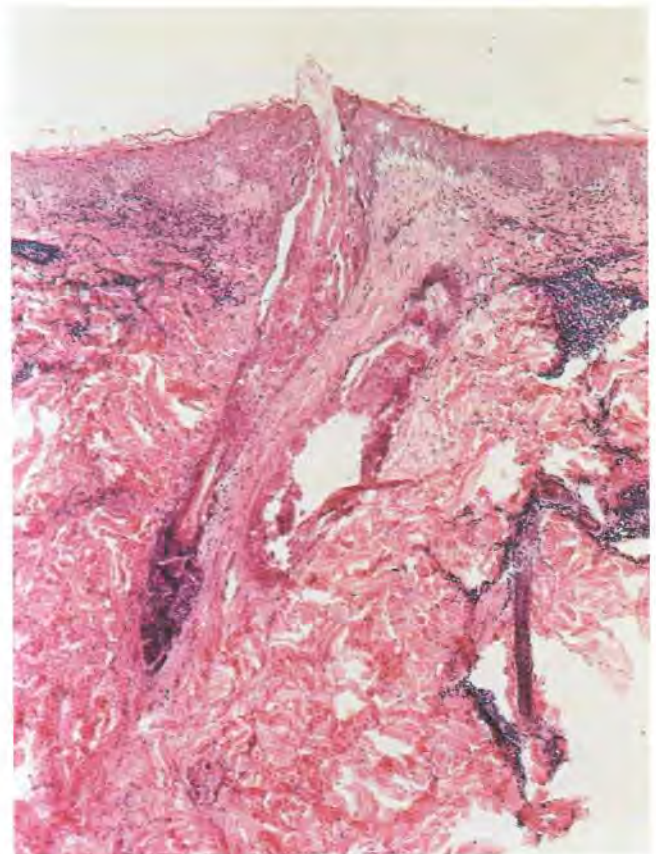


Fig. 2. A specimen of the papular type showing necrosis of pilosebaceous unit without the formation of epidermal vesicle (H & E, \times 40).

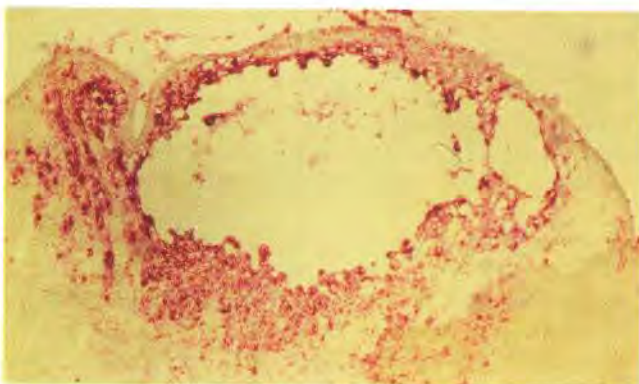


Fig. 3. In situ hybridization with VZV DNA probe in the vesicular type of herpes zoster. VZV DNA is revealed within and around the vesicle in the epidermis ($\times 100$).

Follicular epithelial cells also had VZV DNA in all 4 cases of the vesicular type in which a hair follicle was found in the section. VZV DNA was also found in cells in the dermis beneath the epidermal vesicle in 5 cases. In the papular type, VZV DNA was detected in follicular epithelium or pilosebaceous unit in 7 cases. It was, however, not detected in epidermal cells not associated with hair follicles (Fig. 4). VZV DNA was not detected in the one case of the papular type in which a pilosebaceous unit was not found. In one case of the papular type, it was found in the perifollicular area of the dermis. In

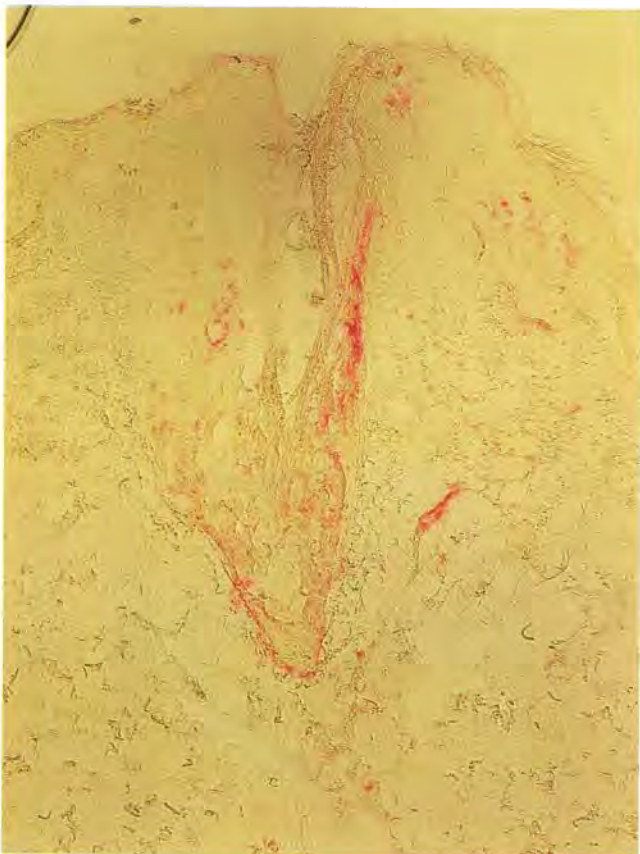

Fig. 4. In situ hybridization with VZV DNA probe in the papular type of herpes zoster. VZV DNA is found in the infundibulum of the hair follicle without spongiosis ($\times 100$).

sections hybridized with vector DNA as negative control in both types, positive cells were not found in any portion of the specimen. VZV DNA probe could not detect any positive cells in the lesion of herpes simplex.

Immunophenotypes of lymphocytes in cellular infiltrate

T-lymphocytes were the major cellular component of the inflammatory infiltrate in both types. Most of the T-cells were CD45RO-positive "memory" T-cell subpopulation in both types. The mean percentages of cells positive for CD3, CD4, CD8, CD25 and CD45RO did not differ between the two types. The CD4/CD8 ratio was 1.3:1 in both types.

DISCUSSION

Individuals with CMI defects have an increased incidence of herpes zoster. CMI to several recall antigens was decreased in the vesicular and papular types of herpes zoster. The scores of Multitest CMI were markedly decreased by 7.7 mm in the vesicular type, and by 8.5 mm in the papular type, compared to 16 mm as average score in Korean normal adults, which had been established in our laboratory (2). It should be considered that fenoprofen administered to patients during examination may have influenced the results. But our decreased results are thought to be meaningful, since the average score in patients who did not receive any drug had been 9 mm in our previous experiment (2). However, the difference was not significant between vesicular and papular types.

VZV DNA was detected in keratinocytes or both keratinocytes and epithelial cells of the hair follicles connected to epidermal vesicles in the vesicular type of herpes zoster. Histological evidence of adnexal involvement has been reported in 42% of the cases of infection with VZV (3). In a recent report, VZV antigens were detected not only in the cells around and within the vesicles in the epidermis, but also in follicular epithelium around necrosis in the vesicular lesions of herpes zoster (4). These findings suggest that viral replication of VZV in herpes zoster spreads from the lower part of the epidermis to the hair follicle in the vesicular type of lesion. Another possible explanation of the involvement of hair follicles in the vesicular type is that sensory nerves in the epidermis and the hair follicles can simultaneously be infected with VZV from dorsal root ganglions. In one patient not enrolled in this study, grouped vesicles and persistent papules appeared simultaneously. VZV DNA was detected in the cells around and within the vesicles of the epidermis of the vesicular lesion, but only in the follicular epithelium in the papular lesion.

VZV DNA was found in follicular epithelium without involvement of keratinocytes of the papular type. Involvement of follicular epithelium is known to occur as a form of viral folliculitis (5, 6). In a previous report of two cases of herpetic sycosis infected with herpes simplex virus (6), the clinical picture consisted of characteristic papulovesicles. Biopsies showed intraepidermal vesicles containing multinucleate viral giant cells and balloon cells, which extended into the adjacent follicular epithelium to the level of infundibulum. The authors demonstrated the extension of the viral infection to the epithelial cells of the external root sheath of the hair follicle. In another report, 2 cases of herpes virus folliculitis (7) showed only involvement of the pilosebaceous unit, without surface

change. So, it is possible that a pilosebaceous unit can only be involved with VZV in the papular type of lesion.

In both types, cells possessing VZV DNA were detected in the dermis. Histiocytes, fibroblasts, vascular endothelial cells and the perineurium of cutaneous nerves in the dermis can also be infected by VZV (4, 8). Infection of VZV in the dermis was thought to come from keratinocytes or follicular epithelium, since cells possessing VZV DNA in the dermis were only found either beneath the involved epidermis in the vesicular type or around the involved hair follicle in the papular type.

In cases showing follicular epithelium involved by VZV, vesicular changes were observed in only the superficial part of hair follicles. Involved follicular epithelium in other parts of hair follicles showed totally necrotic changes. In the papular type, tiny microscopic vesicles were found only in the superficial part of hair follicles, and compact necrosis or spongiosis was observed in other parts of hair follicles. Muraki et al. (4) suggested that the reactions of follicular epithelium to VZV infection differ from those of keratinocytes.

There were no differences in the components of phenotypes of lymphocytes infiltrated in lesions between the vesicular and papular types. Most of them were memory T-lymphocytes. The CD4/CD8 ratio was about 1:1 in both types. Higher CD4/CD8 ratios have been found in atopic dermatitis, allergic contact dermatitis and alopecia areata. Cytotoxic T-cell immune reactions are potentially effective against intracellular viruses (9). It is therefore possible that these reactions contribute to a decreased CD4/CD8 ratio in herpes zoster.

Consequently, our study indicates that the appearance of clinical types of herpes zoster depends on the infected site of VZV in the tissue.

REFERENCES

1. Arvin AM. Cell-mediated immunity to varicella-zoster virus. *J Infect Dis* 1992; 166 (Suppl. 1): s35-s41.
2. Park CW, Choi SW, Kim HO, Kim CW. In vivo delayed hypersensitivity to the recall antigens in different dermatoses. *Korean Journal of Dermatology* 1985; 23: 441-446.
3. McSorley J, Shapiro L, Brownstein MH, Itsu KC. Herpes simplex and varicella-zoster: comparative histopathology of 77 cases. *Int J Dermatol* 1974; 13: 69-75.
4. Muraki R, Baba T, Iwasaki T, Sata T, Kurata T. Immunohistochemical study of skin lesions in herpes zoster. *Virchows Archiv Pathol Anat* 1992; 420: 71-76.
5. Ackerman AB, ed. *Histologic diagnosis of inflammatory skin diseases*. Philadelphia: Lea & Febiger, 1978: 544.
6. Izumi AK, Kim R, Arnold H Jr. Herpetic sycosis. *Arch Dermatol* 1972; 106: 372-374.
7. Sexton M. Occult herpes virus folliculitis clinically simulating pseudolymphoma. *Am J Dermatopathol* 1991; 13: 234-240.
8. Aoyama Y, Kurata T, Kurata K, Hondo R, Ogiwara H. Demonstration of viral antigens in herpes simplex and varicella-zoster infections. *Recent Adv Reticuloendothel Syst Res* 1974; 14: 90-104.
9. Roitt I, Brostoff J, Male D, eds. *Immunology*. London: Mosby-Year Book Europe Ltd, 1993; 15.1-15.8.