

## Notalgia Paresthetica, Macular Posterior Pigmentary Incontinence, Macular Amyloidosis and Pruritus

Sir,

In the most careful long-term study of the relationship among these entities to date, Westermark et al. (1) conclude with a preference "to look at notalgia paresthetica, macular posterior pigmentary incontinence (MPPI) and macular amyloidosis as three related but frequently overlapping conditions." I agree entirely but would quibble with the Venn diagram in Fig. 3. Their diagram correctly indicates that notalgia paresthetica, pigmentary incontinence and macular amyloidosis may exist separately or together. But, at least insofar as it may pertain to the special case of these disorders occurring jointly or separately in the scapular or mid-scapular areas, I believe it fails to convey the primary importance of notalgia paresthetica and the most likely chain of events. In my reflections on this subject (2, 3), I have come to the provisional conclusion that the relationship may be depicted more accurately in the figure I present here (Fig. 1). According to this scheme, notalgia paresthetica (viewed as a localized sensory neuropathy) leads to itching and/or paresthesias; rubbing and scratching (bold arrow) lead to secondary changes such as pigmentary incontinence and/or lichen simplex chronicus in a few (but not many) patients; and further rubbing and scratching (perhaps in combination with a genetic diathesis) lead to macular amyloidosis in a smaller number of patients. The dashed arrow suggests the possibility that, in an even smaller group of patients, rubbing and scratching may lead to macular amyloidosis without an apparent intermediary stage. Most patients with notalgia paresthetica have only sensory symptoms, some achieve hyperpigmentation, and only a few (to borrow Shakespeare's phrase) have macular amyloidosis thrust upon them. Curiously, lichen simplex chronicus almost never occurs, and is mild when it does.

Macular amyloidosis, pigmentary incontinence, other sensory neuropathies, and other localized causes of pruritus may occur in other areas of the body for similar or different reasons (reflected by the non-overlapping portions of the macular amyloidosis and MPPI circles in Westermark et al.'s Venn diagram). An instructive analogy may be the atopic "dirty neck," where pigmentary incontinence accounts for a pattern of rippled hyperpigmentation similar to that seen in macular amyloidosis and where amyloid-like material may sometimes be detected by electron microscopy but not by light microscopy (4). In other words, rubbing and scratching may lead to pigmentary and other secondary changes anywhere on the skin, and in some — perhaps quantitatively, anatomically, or genetically determined circumstances — to the deposition of variably detectable amounts of keratin-derived amyloid. Neither MPPI nor macular amyloidosis should be regarded as *equivalent* to notalgia paresthetica (5), but in the special case of the scapular and mid-scapular areas, they may be regarded as a manifestation or consequence of it.

### REFERENCES

1. Westermark P, Ridderström E, Vahlquist A. Macular posterior pigmentary incontinence: its relation to macular amyloidosis and

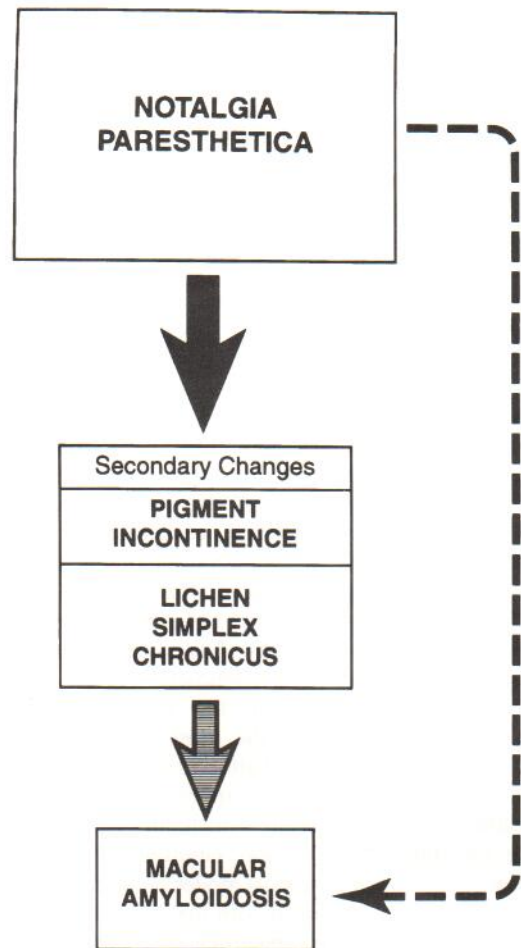


Fig. 1. Schematic pathway from notalgia paresthetica to pigmentary incontinence and macular amyloidosis (see text).

- notalgia paresthetica. *Acta Derm Venereol* (Stockh) 1996; 76: 302-304.
2. Bernhard JD. Macular amyloidosis, notalgia paresthetica and pruritus: three sides of the same coin? *Dermatologica* 1991; 183: 53-54.
3. Bernhard JD. Neurogenic pruritus and strange skin sensations. In: Bernhard JD, ed. *Itch: mechanisms and management of pruritus*. New York: McGraw-Hill, 1994: 185-201.
4. Humphreys F, Spencer J, McLaren K, Tidman MJ. An histological and ultrastructural study of the "dirty neck" appearance in atopic eczema. *Clin Exp Dermatol* 1996; 21: 17-19.
5. Scadding JG. Essentialism and nominalism in medicine: logic of diagnosis in disease terminology. *Lancet* 1996; 348: 594-596.

Accepted October 1, 1996.

Jeffrey D. Bernhard  
Division of Dermatology, University of Massachusetts Medical School, Worcester, Massachusetts 01655-0307, USA.