

## Skin-derived Antileukoproteinase (SKALP) and Epidermal Fatty Acid-binding Protein (E-FABP): Two Novel Markers of the Psoriatic Phenotype that Respond Differentially to Topical Steroid

ASTRID L. A. KUIJPERS<sup>1</sup>, MIEKE BERGERS<sup>1</sup>, GEORGES SIEGENTHALER<sup>2</sup>, PATRICK L. J. M. ZEEUWEN<sup>1</sup>, PETER C. M. VAN DE KERKHOF<sup>1</sup> and JOOST SCHALKWIJK<sup>1</sup>

Departments of Dermatology, <sup>1</sup>University Hospital Nijmegen, The Netherlands and <sup>2</sup>University Hospital Geneva, Switzerland.

Recently we have described two novel markers for disturbed epidermal differentiation, which are strongly upregulated in psoriatic epidermis: skin-derived antileukoproteinase (SKALP) and epidermal fatty acid-binding protein (E-FABP). No data are available on the kinetics of SKALP and E-FABP expression *in vivo* and the relation with epidermal growth and differentiation. We used treatment of lesional psoriatic skin with topical steroid as a model to correlate the expression pattern of SKALP and E-FABP with known cell biological events during regression of the psoriatic lesion. Expression of these markers was studied using immunohistochemistry and Northern blot analysis. After 4 weeks of treatment a substantial clinical improvement was induced by the topical steroid, whereas no significant improvement had occurred at the placebo-treated sides. The expression of SKALP following treatment with steroid was nearly undetectable both at the protein and mRNA level. Mitotic activity, as measured by Ki-67 staining, and cytokeratin 16 expression were downregulated to normal levels in the steroid-treated epidermis. In contrast, although there was a marked decrease of E-FABP mRNA, the staining pattern for E-FABP at the protein level was not affected. After 4 weeks of treatment with steroid the complete suprabasal compartment remained positive, even after considerable clinical improvement of the lesion. We conclude that SKALP and cytokeratin 16 are markers that are downregulated even before complete macroscopic clearance of the lesion. The kinetics of E-FABP expression is distinct from the other molecules and lags behind the clinical signs of psoriasis. **Key words:** *proteinase inhibitor; immunohistochemistry; psoriasis; corticosteroid.*

(Accepted June 14, 1996.)

Acta Derm Venereol (Stockh) 1997; 77: 14-19.

A. L. A. Kuijpers, Department of Dermatology, University Hospital Nijmegen, P.O. Box 9101, 6500 HB Nijmegen, the Netherlands.

In the psoriatic lesion epidermal hyperproliferation, inflammation and a disturbed differentiation are well-known histological features. These aberrations can be visualised by immunohistochemical staining of different marker molecules. Some of these molecules, such as cytokeratin 16 (CK 16), are absent in normal epidermis but are expressed in lesional psoriatic skin. In psoriatic skin CK 16 is present in the upper layers of the suprabasal compartment (1, 2). Other differentiation-related proteins which are restricted to the granular layer in normal skin are strongly expressed in the stratum spinosum of the psoriatic epidermis. Well-known representatives of this class of differentiation markers are involucrin (3, 4) and transglutaminase (5).

Recently two new epidermal proteins were described: skin-

derived antileukoproteinase (SKALP) and epidermal fatty acid-binding protein (E-FABP). SKALP, identical to elafin (6), is a potent inhibitor of human leukocyte elastase and proteinase 3, enzymes which are released by activated PMN (7). It is speculated that SKALP provides protection against elastase-mediated damage and inhibits PMN migration. Immunohistochemical staining located the expression of SKALP in the upper layers of the suprabasal compartment in psoriatic skin, whereas uninvolved psoriatic skin and normal skin showed no expression (8). The expression of mRNA for SKALP, examined by *in situ* hybridization, revealed an intense staining of the suprabasal compartment in psoriatic skin (9).

The second novel epidermal protein is E-FABP, described by others as psoriasis-associated fatty acid-binding protein (PA-FABP) (10), which binds fatty acids with high specificity (11). In previous investigations the presence of an epidermal FABP distinct from other tissue-FABP was established (12). Expression levels of E-FABP were upregulated in psoriatic skin and cultured keratinocytes compared to normal skin, suggesting that the stage of keratinocyte differentiation is related to the expression of E-FABP (11, 10). Immunohistochemical staining of E-FABP showed expression in the stratum granulosum and in the upper third of the stratum spinosum in normal skin and non-lesional psoriatic skin. In psoriatic epidermis E-FABP is expressed in all suprabasal layers (11).

Topical application of corticosteroids represents an effective treatment of chronic plaque psoriasis (13). The effect of corticosteroids on histological parameters in dermis and epidermis has been investigated previously (14, 15). Both the number of cycling cells, as marked by positive nuclei in a Ki-67 staining, and the CK 16-expressing cells showed a marked decrease after only 1 week of treatment (16). Dermal polymorphonuclear leukocyte infiltration also diminished early, in contrast to the mononuclear cells, which remained unchanged after treatment.

The aim of this study was to investigate the effect of topical corticosteroid on the expression levels of two novel markers of the psoriatic differentiation program. We were particularly interested in studying whether steroids would affect the presumed anti-inflammatory part of the program (SKALP expression) or the regenerative part of the program (E-FABP expression). The changes of these markers were related to the expression of two established markers for epidermal proliferation: the Ki-67 nuclear antigen and CK 16.

### MATERIAL AND METHODS

#### Patients

Twelve patients (7 males and 5 females, mean age 52, range 30-67) with chronic plaque psoriasis participated in a randomised, double-

blind left-right study. Permission of the medical ethical committee and written informed consent from all patients were obtained. The patients had not used topical corticosteroids for at least 2 weeks. In this left-right study hydrocortisone 17-butyrate 0.1% (Locoid® Crelo®, Yamanouchi, Leiderdorp, the Netherlands) was compared with vehicle. Patients applied the creams thinly on the psoriatic lesions twice daily during 4 weeks. In one lesion on the left side and one on the right side of the body clinical scores were recorded before treatment and after 4 weeks of treatment. Erythema, induration and scaling of the lesions were assessed using a five-point scale: 0=no cutaneous involvement, 1=slight, 2=moderate, 3=severe, 4=severest possible.

#### Skin biopsies

In 6 patients punch biopsies (4 mm) were taken for histological examination. Biopsies were taken from one lesion before treatment and from both sides after 4 weeks of treatment. Biopsies were fixed in buffered 4% formalin for at least 24 h and processed for routine histology. Tissue was embedded in paraffin and 5- $\mu$ m sections were cut.

In the other 6 patients two shave biopsies for RNA measurement were taken before therapy, one from uninvolved skin and one from lesional skin. Subsequently, biopsies were taken from both sides after 2 days and 4 weeks of treatment. Biopsies were snap-frozen in liquid nitrogen and stored at  $-80^{\circ}\text{C}$  until use.

All biopsy places were marked on a transparent sheet before treatment was started.

#### Immunohistochemical staining

Staining to assess epidermal proliferation and keratinization was carried out using the following antibodies: MIB (Immunotech S.A., Marseille, France), which binds to the nuclear antigen Ki-67 present in cycling cells (17), and Ks8.12 (Sigma, St. Louis, MO, USA), which detects CK 16. CK 16 is expressed by hyperproliferative keratinocytes (1). Anti-E-FABP serum and anti-SKALP serum were prepared as previously described (8, 11).

Paraffin sections were deparaffinised and rehydrated and immunostaining was performed. An indirect peroxidase technique was used for staining with anti-CK 16 antibodies and the antisera against E-FABP and SKALP. First, the sections were pre-incubated with normal swine serum (E-FABP, SKALP) or normal rabbit serum (CK 16). For staining with the anti-CK 16 antibodies, slides were incubated with the antibody in a dilution of 1:25 for 30 min. For SKALP and E-FABP staining, sections were incubated with anti-SKALP serum at a dilution of 1:500 and anti-E-FABP serum at a dilution of 1:100 for 60 min. After incubation with peroxidase-conjugated rabbit-anti-mouse Ig (CK 16 staining) or peroxidase-conjugated swine-anti-rabbit Ig (SKALP and E-FABP staining), the sections were developed with amino-ethylcarbazole as the chromogenic substrate.

For staining of the Ki-67 antigen sections were pre-incubated with normal horse serum. Subsequently, slides were incubated with anti-Ki-67 antibodies in a dilution of 1:50 for 60 min. After incubation with biotinylated horse-anti-mouse IgG (dilution 1:200) for 30 min, complexes were formed between biotin and avidin using the Vectastain Elite ABC peroxidase kit, according to the manufacturer's instructions (Vector Laboratories, Burlingame, USA). The sections were developed with metal-enhanced diaminobenzidine as the chromogenic substrate.

#### Histological examination

Semiquantitative assessment of the histology was carried out by an observer who was unaware of whether sections were derived from steroid- or placebo-treated sites. Epidermal proliferation was measured by counting the number of Ki-67-positive nuclei per mm length of the section. The CK 16, SKALP and E-FABP staining in the epidermis was assessed using a five-point scale: 0=no staining, 1=sporadic staining, 2=weak staining, 3=moderate staining, 4=pronounced staining.

#### RNA isolation and Northern blot analysis

Total RNA was extracted from shave biopsies, using RNazol B, as suggested by the supplier (Cinna/Biotex Laboratory, Inc., Houston, TX, USA). For Northern blot analysis, 10  $\mu$ g of total RNA was electrophoresed on a 1% agarose gel containing 18% formaldehyde following standard procedures (18) and blotted onto a nylon membrane (Boehringer, Mannheim, Germany) by capillary transfer. After transfer, RNA was fixed to the membrane by ultraviolet irradiation (312 nm, 0.2 J/cm<sup>2</sup>). Hybridisation was performed as described previously using a 0.42 kbp *PvuII/EcoRI* fragment of the SKALP cDNA clone pGESKA as a probe (18). Subsequently, after stripping of the membranes with 0.1% SDS 15 mM NaCl 1.5 mM NaCitrate in RNase-free water, hybridisation was performed as described previously using the PA-FABP cDNA clone 1592 as probe, which was a kind gift of Dr. P. Madsen, Institute of Medical Biochemistry and Danish Centre for Human Genome Research, Aarhus University, Denmark (10). Control hybridisations for equal loading were performed using a human 28 S ribosomal RNA probe. All probes were labelled with <sup>32</sup>P by random priming following standard procedures. Autoradiography was performed on X-Omat S film (Kodak, France) at  $-80^{\circ}\text{C}$  with an intensifying screen.

#### Statistical analysis

The Wilcoxon ranking test for matched pairs was used for the statistical analysis.

## RESULTS

#### Clinical response

The clinical response to treatment with steroid and placebo is summarised in Fig. 1. Comparing the efficacy of treatment (= scores before treatment - scores after treatment) with steroid and efficacy of treatment with placebo, a significant difference in favour of the steroid in erythema score and desquamation score could be established. No significant difference in induration score was found.

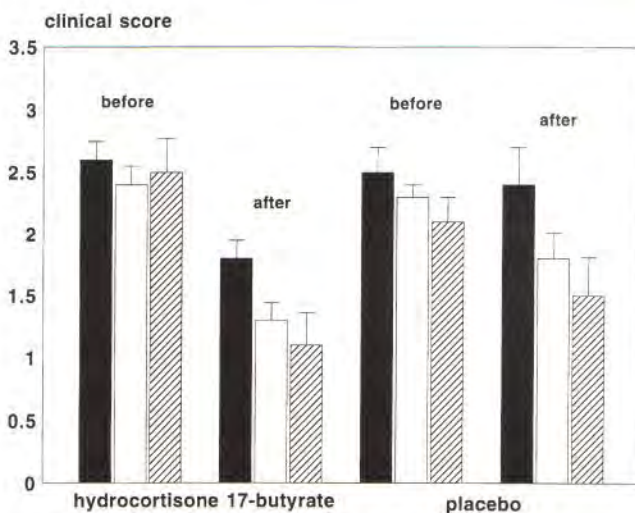


Fig. 1. The clinical scores as rated for erythema (black bars), induration (white bars) and desquamation (hatched bars) before and after treatment with hydrocortisone 17-butyrate and placebo, expressed as mean values  $\pm$  SEM. Comparing the efficacy of treatment (= scores before treatment - scores after treatment) with steroid and with placebo, a significant difference in favour of the steroid in erythema score ( $p < 0.03$ , Wilcoxon ranking test) and desquamation score ( $p < 0.05$ , Wilcoxon ranking test) was found.

Table I. Mean values of the markers for proliferation and differentiation  $\pm$  SD

The CK 16, SKALP and E-FABP staining in the epidermis was assessed using a five-point scale: 0=no staining, 1=sporadic staining, 2=weak staining, 3=moderate staining, 4=pronounced staining. Ki-67 staining was measured by counting the number of positive nuclei per mm length of the section. Comparison was made between values before treatment and after treatment with hydrocortisone 17-butyrate 0.1% and placebo, respectively ( $*p < 0.01$ , Wilcoxon ranking test)

Antigen	Week 0	Week 4 Steroid	Week 4 Placebo
SKALP	3.2 $\pm$ 0.4	0.3 $\pm$ 0.5*	3.3 $\pm$ 0.5
E-FABP	3.4 $\pm$ 0.5	2.8 $\pm$ 0.7	3.5 $\pm$ 0.5
Cytokeratin 16	3.2 $\pm$ 0.5	0.2 $\pm$ 0.4*	3.1 $\pm$ 0.9
Ki-67	98.0 $\pm$ 31.5	12.5 $\pm$ 5.0*	72.5 $\pm$ 33.8

#### Immunohistochemical observations

Semiquantitative data on the staining patterns of the different antibodies are presented in Table I. In the untreated psoriatic lesion SKALP expression is seen in the suprabasal compartment (Fig. 2a). After 4 weeks of treatment with steroid, a significant decrease in SKALP expression could be seen (Fig. 2b). In 2 patients a slight staining was still present after treatment with steroid. SKALP expression was completely absent in the other patients. The placebo-treated lesions showed no significant decrease of SKALP-positive cells (Fig. 2c).

Before treatment, the E-FABP staining was prominent in all the suprabasal layers of the epidermis (Fig. 3a). In contrast to all other markers stained, E-FABP expression in the steroid-treated lesions did not return to the normal pattern (i.e. expression limited to the stratum granulosum as described before). The E-FABP staining in the steroid-treated lesions (Fig. 3b) is similar to that in the placebo-treated lesions (Fig. 3c), showing positive staining in the entire stratum spinosum.

In this study we found a strong effect of topical steroid on CK 16 (nearly undetectable in most biopsies) and Ki-67 expression, which was downmodulated to the level found in normal skin ( $12.8 \pm 1.5$  cells per mm) (19).

#### Northern blot analysis

Before treatment, shave biopsies were taken from 6 patients from lesional and non-lesional skin. Biopsies were repeated after 2 days and 4 weeks from a steroid- and a placebo-treated lesion. Fig. 4 shows the presence of SKALP mRNA (Fig. 4a) and E-FABP mRNA (Fig. 4b) in the biopsies taken from 2 representative patients. In untreated psoriatic skin a strong expression of SKALP mRNA could be demonstrated, whereas the uninvolved skin showed no expression. After 2 days SKALP mRNA in the steroid-treated lesions showed no decrease, remaining equal to the placebo-treated lesions. After 4 weeks of treatment with placebo SKALP mRNA expression was still high, whereas a weak signal was found in the steroid-treated lesions. However, in none of the patients did steroid treatment result in complete downregulation as observed in uninvolved skin.

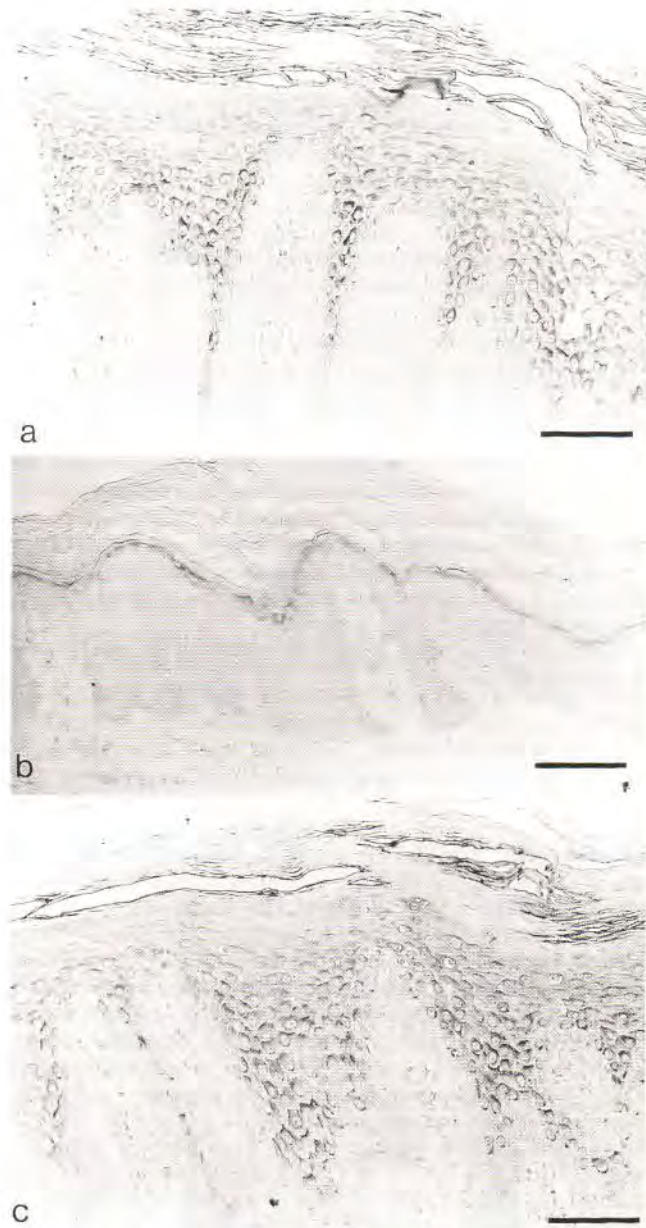


Fig. 2. (a) The SKALP expression before treatment. SKALP is seen in the suprabasal layers of the epidermis. (b) The SKALP expression after 4 weeks of treatment with hydrocortisone 17-butyrate. SKALP was only slightly expressed. (c) The SKALP expression after 4 weeks of treatment with placebo is comparable with the expression we observed before the treatment period. Bar, 100  $\mu$ m.

The expression of E-FABP mRNA in untreated psoriatic skin is strong; uninvolved skin shows no detectable expression (Fig. 4b). Remarkably, after 2 days' treatment with steroid, E-FABP mRNA expression was substantially decreased. After 4 weeks both placebo- and steroid-treated psoriatic skin showed a marked decrease of E-FABP mRNA expression, with a more pronounced decrease in the steroid-treated lesions.

#### DISCUSSION

Since the aetiology of psoriasis is unknown and the pathogenesis is only partially understood, we still do not know the

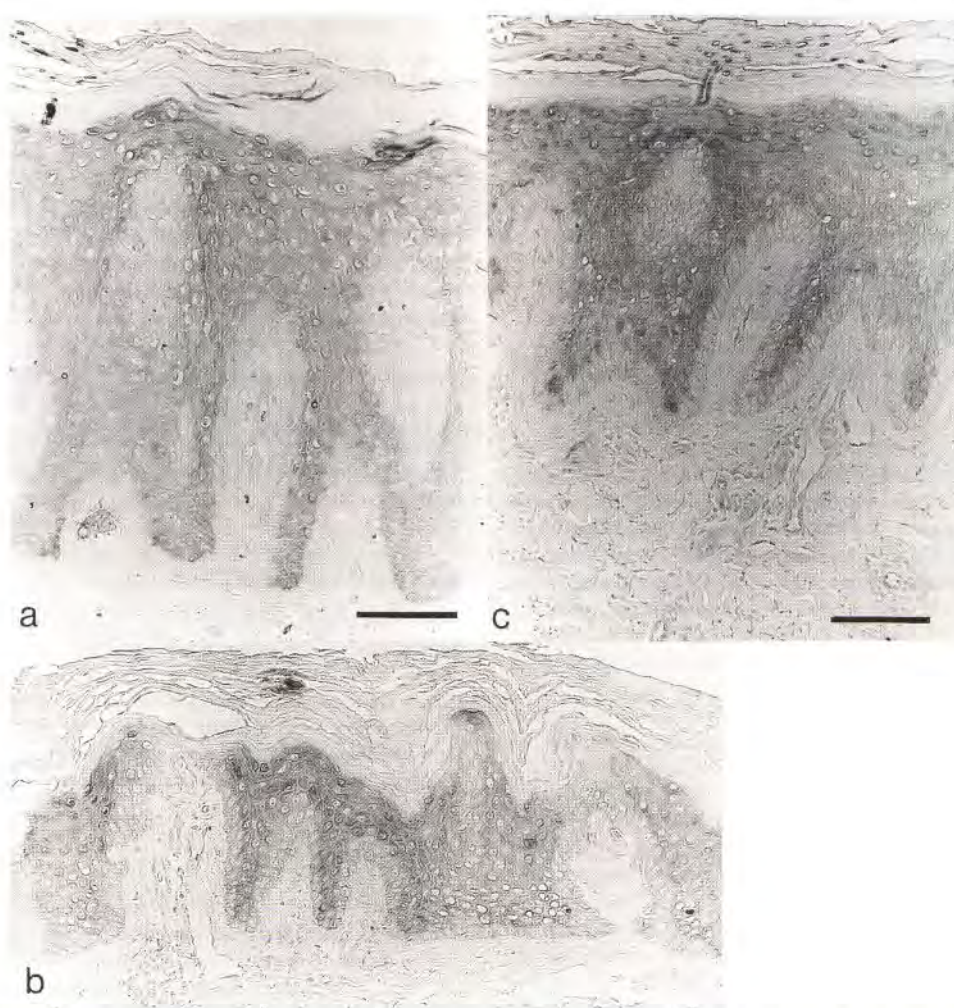


Fig. 3. (a) E-FABP staining before treatment. E-FABP is expressed in all suprabasal layers of the epidermis, the basal layer being completely negative. (b) The E-FABP expression after 4 weeks of steroid treatment. There was a slight reduction in expression of E-FABP, but it did not return to normal. (c) The E-FABP expression after 4 weeks of treatment with placebo is comparable with the expression we observed before the treatment period. Bar, 100  $\mu$ m.

rational base of most antipsoriatic therapies used. Studying the sequence of events at the cell biological level in the regression phase of a lesion during treatment could provide us with clues to the mode of action of a specific treatment and contribute to our understanding of the pathogenesis.

We have investigated the response of several markers of the psoriatic phenotype to treatment with topical steroid. In a previous study (16) we have shown that keratin 16 staining and Ki-67 expression in psoriatic epidermis were markedly downregulated under steroid treatment. Despite the use of a less potent class II steroid in present study for 4 weeks, a significant improvement of the lesions was seen compared to placebo. Remarkably, cellular proliferation, CK 16 expression and SKALP expression were found to be completely normalised in most patients, despite the fact that clinical scores were not completely normalised (compare Table I and Fig. 1). E-FABP, however, continued to be expressed throughout the entire suprabasal compartment after 4 weeks of treatment, in all patients. These findings show that cell biological alterations found in psoriatic epidermis do not necessarily display similar kinetics.

Previous studies from our group have shown that SKALP

is absent in normal skin and that it is induced in psoriatic skin and during injury (8, 20). We have described the distribution in the margin zone of psoriatic plaques (21) and the induction and regression in annular pustular psoriasis (22). Based on the finding that SKALP is a potent and specific inhibitor of PMN-derived proteinases (7) we assume that it controls PMN-dependent proteolysis in cutaneous inflammation. In vivo SKALP expression is putatively linked to the presence of elastase-containing cells (PMN and monocytes) in the inflamed skin. In this study we have shown that SKALP is downmodulated after 4 weeks of topical steroid. The finding that after 2 days of therapy the levels of SKALP mRNA are similar in steroid- and placebo-treated skin indicates that it is unlikely that SKALP is affected at the transcriptional level by steroid. SKALP downregulation is probably not a direct effect of the steroid at the transcriptional level but is rather a consequence of normalisation (healing) of the tissue. We therefore assume that steroid-treatment decreases the cellular infiltrate and that consequently SKALP expression in the epidermis is downmodulated.

E-FABP, also known as psoriasis-associated fatty-acid-binding protein (10), is a recently described member of the

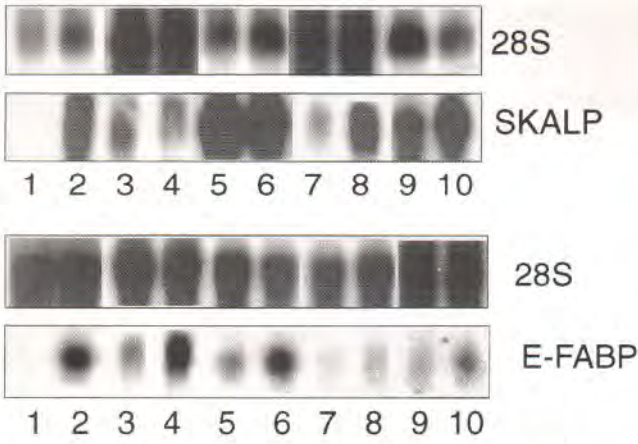


Fig. 4. Northern blot of SKALP and E-FABP mRNA in skin biopsies of 2 representative psoriatic patients treated in a left-right study with hydrocortisone 17-butyrate and placebo. Lane 1 = uninvolved skin, lane 2 = psoriatic skin before treatment; lanes 3–6 represent biopsies taken in 2 representative patients after 2 days of treatment (lanes 3+4 and lanes 5+6, respectively); lanes 3+5 = after 2 days' treatment with steroid, lanes 4+6 = after 2 days' treatment with placebo; lanes 7–10 represent biopsies taken in 2 representative patients after 4 weeks of treatment (lanes 7+8 and lanes 9+10, respectively); lanes 7+9 = after 4 weeks' treatment with steroid, lanes 8+10 = after 4 weeks' treatment with placebo. In the upper panels a probe for 28S ribosomal RNA was used for control hybridizations to check for equal RNA loading.

a. Lower panel. Before treatment no expression of SKALP could be demonstrated in uninvolved skin (lane 1), whereas psoriatic skin showed a strong expression (lane 2). After 2 days of treatment the expression in the steroid-treated lesions (lanes 3+5) and the placebo-treated lesions (lanes 4+6) was equal. After 4 weeks of treatment no significant decrease in SKALP mRNA was found in the placebo-treated lesions (lanes 8+10). Compared with placebo, the mRNA expression in the steroid-treated lesions (lanes 7+9) is strongly decreased, which is in agreement with the data on the protein level.

b. Lower panel. Before treatment no expression of E-FABP could be demonstrated in uninvolved skin (lane 1), whereas psoriatic skin showed a strong expression (lane 2). After 2 days of treatment the expression in the steroid-treated lesions (lanes 3+5) was decreased, whereas placebo-treated lesions (lanes 4+6) showed no decrease. After 4 weeks of treatment the mRNA expression in both the steroid-treated lesions (lanes 7+9) and the placebo-treated lesions is decreased, with a more pronounced decrease in the placebo-treated lesions (lanes 8+10).

cytoplasmic fatty acid binding proteins (12, 23). It is expressed at relatively low levels in normal epidermis (restricted to the granular layer) but is strongly upregulated in psoriatic epidermis (11, 10). The mechanism of its induction and its precise function are not understood at the moment. E-FABP has a high affinity for C-18 fatty acids but is not involved in arachidonic acid binding. A function of E-FABP as a scavenger of arachidonic acid to control inflammation is therefore unlikely. This agrees with the finding that E-FABP is still increased after 4 weeks of steroid therapy. In contrast to the persisting expression of E-FABP in the suprabasal layers even after 4 weeks' treatment, Northern blot analysis revealed a decrease in mRNA expression after 2 days of treatment with steroid. Whether this finding implicates that steroids have a direct influence at the transcriptional level requires further study.

Speculatively, increased E-FABP expression in psoriasis

could be involved in barrier function (enhanced transport of lipids). Studies on restoration of barrier function in healing psoriatic lesions have shown that barrier function is still impaired even after complete clearing of the lesions after dithranol treatment (24). We therefore speculate that the persistent E-FABP expression is associated with a continuous high fatty acid transport, which is needed for restoration of barrier function. We have recently completed a study on the cell biological alterations during irritant contact dermatitis, which strongly suggests that E-FABP expression is increased following barrier disruption.

In conclusion, E-FABP expression in psoriatic skin is a cell biological marker that is distinct from other markers such as CK 16, SKALP and cellular proliferation, which are downregulated even before complete clinical normalisation. Our study indicates that E-FABP expression lags behind the clinical signs of psoriasis.

#### ACKNOWLEDGEMENTS

This investigation was supported, in part, by the Swiss National Science Foundation (grant no. 32-31338.91) to GS. We would like to thank P. Madsen, Institute of Medical Biochemistry and Danish Centre for Human Genome Research, Aarhus University, Denmark, for providing the PA-FABP cDNA clone 1592 probe and F van Ruissen, Department of Dermatology, University Hospital Nijmegen, the Netherlands, for his help with the figures.

#### REFERENCES

- de Mare S, van Erp PEJ, van de Kerkhof PCM. Epidermal hyperproliferation assessed by the monoclonal antibody Ks8.12 on frozen sections. *J Invest Dermatol* 1989; 92: 130–131.
- Weiss RA, Eichner R, Sun TT. Monoclonal antibody analysis of keratin expression in epidermal diseases: a 48- and 56 kDalton keratin as molecular markers for hyperproliferative keratinocytes. *J Cell Biol* 1984; 98: 1397–1406.
- Kanitakis J, Zambruno G, Viac J, Thivolet J. Involucrin expression in keratinization disorders of the skin – a preliminary study. *Br J Dermatol* 1987; 117: 479–486.
- Watt FM. Involucrin and other markers of keratinocyte terminal differentiation. *J Invest Dermatol* 1983; 1: 100s–103s.
- Michel S, Demarchez M. Localization and in vivo activity of epidermal transglutaminase. *J Invest Dermatol* 1988; 90: 472–474.
- Wiedow O, Schröder J, Gregory H, Young JA, Christophers E. Elafin: an elastase specific inhibitor of human skin. Purification characterization and complete amino acid sequence. *J Biol Chem* 1990; 265: 14791–14795.
- Wiedow O, Lüdemann J, Utecht B. Elafin is a potent inhibitor of proteinase 3. *Biochem Biophys Res Commun* 1991; 174: 6–10.
- Schalkwijk J, van Vlijmen IM, Alkemade JA, de Jongh GJ. Immunohistochemical localization of SKALP/elafin in psoriatic epidermis. *J Invest Dermatol* 1993; 100: 390–393.
- Nonomura K, Yamanishi K, Yasuno H, Nara K, Hirose S. Up-regulation of elafin/SKALP gene expression in psoriatic epidermis. *J Invest Dermatol* 1994; 103: 88–91.
- Madsen P, Rasmussen HH, Leffers H, Honoré B, Celis JE. Molecular cloning and expression of a novel keratinocyte protein (psoriasis-associated fatty acid-binding protein [PA-FABP]) that is highly up-regulated in psoriatic skin and that shares similarity to fatty acid-binding proteins. *J Invest Dermatol* 1992; 99: 299–305.
- Siegenthaler G, Hotz R, Chatellard-Gruaz D, Didierjean L, Hellman U, Saurat JH. Purification and characterization of the human epidermal fatty acid-binding protein: localization during

epidermal cell differentiation in vivo and in vitro. *Biochem J* 1994; 302: 363–371.

12. Siegenthaler G, Hotz R, Chatellard-Gruaz D, Jaconi S, Saurat JH. Characterization and expression of a novel human fatty acid-binding protein: the epidermal type, (E-FABP). *Biochem Biophys Res Commun* 1993; 190: 482–487.
13. Corbett MF. The response of psoriasis to betamethasone valerate and clobetasol propionate. *Br J Dermatol* 1976; 94: 89–93.
14. Lavker RM, Schechter NM, Lazarus GS. Effects of topical corticosteroids on human dermis. *Br J Dermatol* 1986; 115: 101–107.
15. Bos JD, Krieg SR. Psoriasis infiltrating cell immunophenotype: changes induced by PUVA or corticosteroid treatment in T-cell subsets, Langerhans' cells and interdigitating cells. *Acta Derm Venereol (Stockh)* 1985; 65: 390–397.
16. de Jong EMGJ, de Zwart A, Wauben-Penris PJJ, Korstanje C, van de Kerkhof PCM. Effect of topical treatment with Budesonide (Preferid) on clinical scores, and on parameters for proliferation, keratinization and inflammation in psoriasis. *J Dermatol Science* 1995; 9: 185–194.
17. Gerdes J, Schwab U, Lemke H, Stein H. Production of a mouse monoclonal antibody reactive with a human nuclear antigen associated with cell proliferation. *Int J Cancer* 1983; 31: 13–20.
18. Molhuizen HOF, Alkemade HAC, Zeeuwen PLJM, de Jongh GJ, Wieringa B, Schalkwijk J. SKALP/Elafin: an elastase inhibitor from cultured human keratinocytes. Purification, cDNA sequence and evidence for transglutaminase crosslinking. *J Biol Chem* 1993; 268: 12028–12032.
19. Rijzewijk JJ, van Erp PEJ, Bauer FW. Two binding sites for Ki-67 related to quiescent and cycling cells in human epidermis. *Acta Derm Venereol (Stockh)* 1989; 69: 512–515.
20. Chang A, de Jongh G, Mier PD, van de Kerkhof PCM. Enzymatic quantification of polymorphonuclear leukocytes in normal and psoriatic skin following standardized injury. *Clin Exp Dermatol* 1988; 13: 62–66.
21. van de Kerkhof PCM, Kuppens LHCM, van Vlijmen Y, Schalkwijk J. Distribution of skin-derived antileucoproteases (SKALP) in the marginal zone of the spreading psoriatic lesion. *Br J Dermatol* 1991; 124: 10–12.
22. Kuijpers ALA, Alkemade JAC, Schalkwijk J, van de Kerkhof PCM. Topographic relation between skin-derived antileukoprotease (SKALP) and leukocyte elastase in a case of annular pustular psoriasis. *Acta Derm Venereol (Stockh)* 1995; 75: 110–113.
23. Veerkamp JH, Maatman RGJ. Cytoplasmic fatty acid-binding proteins: their structure and genes. *Prog Lipid Res* 1995; 34: 17–52.
24. Rogers S. Measurement of plaque thickness and evaporative water loss in psoriasis with PUVA and dithranol treatment. *Clin Exp Dermatol* 1993; 18: 21–24.