

## Milker's Nodule – A Report of 15 Cases in the County of North Jutland

Sir,

Pseudo-cowpox is contagious and is caused by a parapox virus. Lesions are found mainly on the teats of infected cows. In man, cutaneous lesions called milker's nodules are seen primarily on the hands of dairy farmers (1). Such cases are rare in Denmark, but in 1993 and 1994 we have seen 15 patients. Three patients developed an erythema multiforme-like eruption (Fig. 1). Treatment was mostly curettage followed by cauterization. The skin eruption then faded after 1–2 weeks. The lesions of 9 of the 15 patients and 3 lesions from the teats of cows were examined histologically. Seven human and 2 cow teat lesions were also examined by electron microscopy (EM). The lesions of one of the 9 patients and one of the 3 cow teats were in the papular stage. There was vacuolization of cells in the upper third of the epidermis of all lesions. This is consistent with a viral infection. Intracytoplasmatic inclusions were also present. Two of the 9 patients had lesions in the nodular stage, in which fingershaped projections were seen in the epidermis. The dermis contained many newly formed, dilated capillaries and a dense mononuclear infiltrate. Foci of epidermal cells with vacuolization were present. In 6 of 9 patients, lesions were in the ulcerated stage. The epidermis of these lesions was necrotic, with scale-crust and ballooning intraepidermal vesiculation.

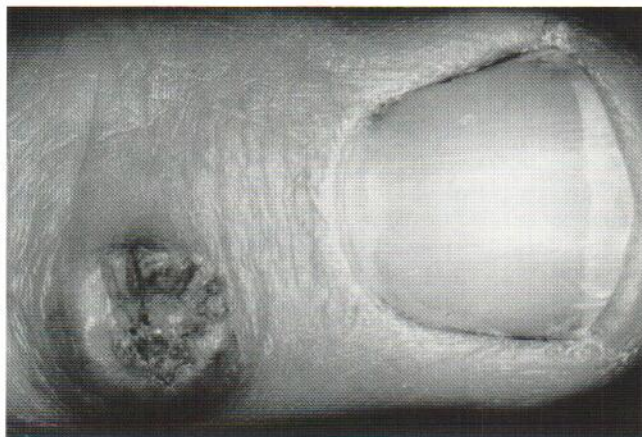


Fig. 1. Milker's nodule on the left hand.

EM was carried out on both paraffin-embedded material and on tissue fixed in glutaraldehyde. Parapox virus had a characteristic oval shape and measured approximately  $260 \times 160$  nm. The protein coat had inner and outer layers and a central electron-dense DNA core (Fig. 2). Viral particles showed a remarkable resistance to improper preparation technique.

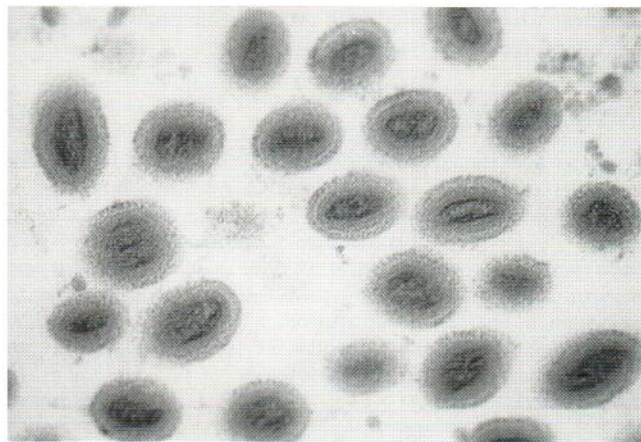


Fig. 2. Mature viral particles show the morphological characteristics of parapox virus ( $\times 80,000$ ).

### REFERENCE

1. Shelley W, Shelley ED. Surgical treatment of farmyard pox. *Cutis* 1983; 31: 191–192.

Accepted July 24, 1995.

Sanne K. Hansen<sup>1</sup>, Henrik Mertz<sup>2</sup>, Annelise Kroghdahl<sup>2</sup> and Niels K. Veien<sup>1</sup>

<sup>1</sup>The Dermatology Clinic, Vesterbro 99, Aalborg, and <sup>2</sup>Department of Pathology, Aalborg Hospital, Aalborg, Denmark.