

Morphologic Features and Clinical Significance of Skin Involvement in Patients with AIDS-related Cryptococcosis

ROBERTO MANFREDI¹, ALDO MAZZONI², ANNA NANETTI², ANTONIO MASTROIANNI¹, OLGA CORONADO¹ and FRANCESCO CHIODO¹

Institutes of ¹Infectious Diseases and ²Microbiology, University of Bologna, Bologna, Italy

Eight out of 30 consecutive patients with AIDS and cryptococcal meningoencephalitis (26,7%) presented cutaneous involvement, in the form of papulo-nodular lesions in 3 patients, molluscum contagiosum-like lesions in 3 patients, and pustular-ulcerative lesions in 2 patients. Skin localization represented an untoward prognostic sign, and in 3 out of 8 patients the lesions were diagnosed 2 to 6 weeks before the onset of systemic and neurologic signs and symptoms of the disease. A systematic examination of all suspected cutaneous lesions in subjects with advanced HIV disease may lead to an earlier diagnosis and treatment of disseminated cryptococcosis. **Key words:** HIV/AIDS; clinical picture; prognosis.

(Accepted September 4, 1995.)

Acta Derm Venereol (Stockh) 1996; 76: 72-74.

R. Manfredi, Istituto Malattie Infettive, Università di Bologna, Via Massarenti 11, I-40138 Bologna, Italy.

Skin diseases and cutaneous localization of systemic disorders are important clinical features in patients with HIV infection, and in some cases they may represent early diagnostic clues or useful prognostic markers of disease progression (1).

Cutaneous manifestations of systemic fungal infections may show a polymorphic clinical picture and a variable relationship with the disease course, when compared with those recognized in compromised patients without HIV disease (1-3).

In order to assess the incidence, morphologic features, and clinical significance of the cutaneous localization of *Cryptococcus neoformans* infection in patients with AIDS, we systematically evaluated all suspected skin lesions observed in severely immunocompromised HIV-infected patients for possible fungal involvement, both in subjects with and without an established diagnosis of cryptococcosis.

PATIENTS AND METHODS

Clinical and microbiological records of our series of 390 patients with AIDS were retrospectively reviewed, in order to identify all subjects suffering from extrapulmonary cryptococcosis.

The cutaneous localization of this opportunistic mycosis was diagnosed by considering the clinical picture and histopathological and culture studies of skin biopsy specimens or clinical samples obtained by cutaneous scarification, performed by standard techniques.

The occurrence of fungal skin lesions was related to several clinical, laboratory and prognostic variables of disease evolution.

RESULTS

Eight out of 30 consecutive subjects developing extrapulmonary cryptococcosis (26,7%) (all males, aged 26 to 50 years; 6 i.v. drug abusers, one homosexual, and one heterosexual) presented cutaneous *C. neoformans* infection. Papulo-nodular lesions were observed in 3 patients, molluscum contagiosum-like lesions in 3 patients (Fig. 1), and pustular-ulcerative lesions in the remaining 2 patients (Table I). They were localized to the face and neck in 7 cases, chest and back in 4 cases, and upper or lower extremities in 3 cases, in number ranging from 2 to over 100. Large amounts of fungal organisms were easily disclosed by histopathological studies, which always showed a massive cryptococcal infiltration of both epidermis and dermis, associated with a poor to moderate inflammatory reaction containing scattered multinucleate giant cells and histiocytes (Fig. 2).

All subjects with skin localization suffered from (or

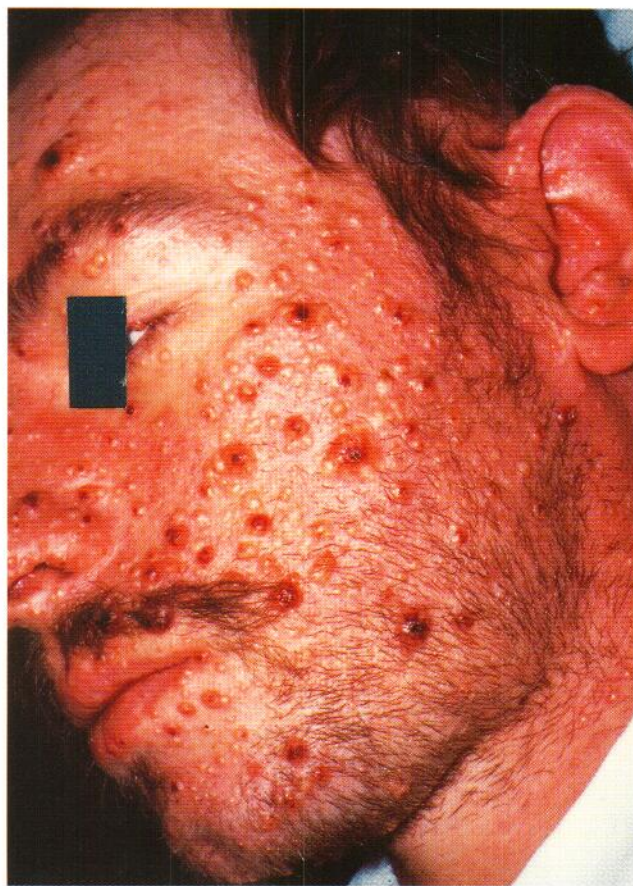

Fig. 1. Multiple skin lesions resembling molluscum contagiosum in a patient with AIDS and disseminated cryptococcosis (patient no. 8).

Table I. Epidemiological, immunological, clinical and treatment data of patients with AIDS-related cutaneous cryptococcosis

Patient no.	Type of risk for HIV infection	CD4+ lymphocyte count/mm ³	Other previous or concurrent AIDS-related diseases	Clinical features of cutaneous lesions	Antifungal treatment (i.v. route)	Outcome
1	i.v. drug user	70	-	pustular-ulcerative	amphotericin B	rapidly lethal
2	i.v. drug user	26	-	molluscum contagiosum-like	fluconazole	rapidly lethal
3	i.v. drug user	52	cryptosporidiosis	papulo-nodular	fluconazole	rapidly lethal
4	i.v. drug user	57	extrapulmonary tuberculosis	pustular-ulcerative	fluconazole	clinical remission
5	heterosexual	13	non-typhoid salmonellosis	papulo-nodular	fluconazole	rapidly lethal
6	i.v. drug user	40	-	molluscum contagiosum-like	fluconazole	rapidly lethal
7	homosexual	38	-	papulo-nodular	fluconazole + flucytosine	rapidly lethal
8	i.v. drug user	20	-	molluscum contagiosum-like	fluconazole; amphotericin B	clinical remission

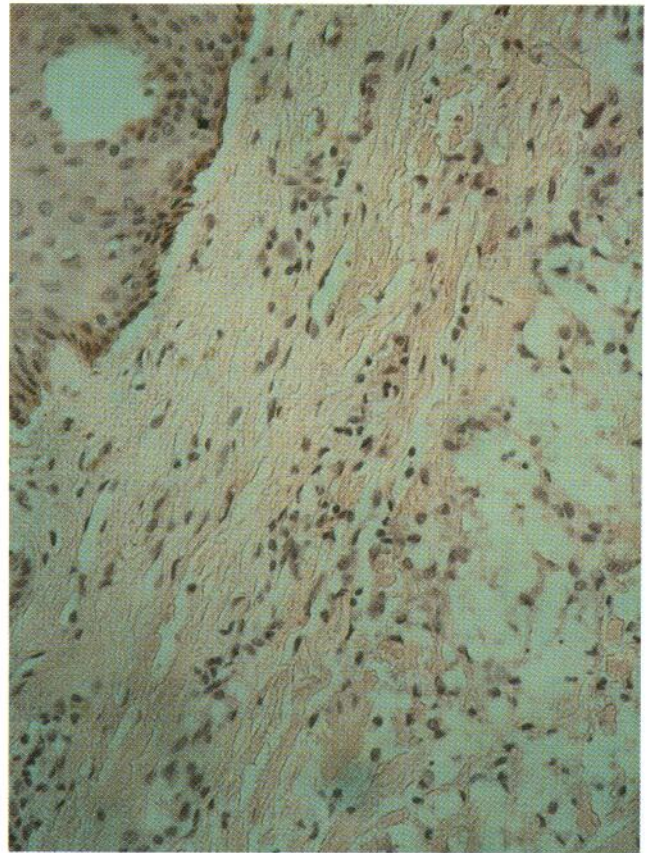


Fig. 2. Photomicrograph of biopsy specimen of a cutaneous lesion due to disseminated cryptococcosis in a patient with AIDS. A massive fungal infiltration of both epidermis and dermis is present, with cryptococcal blastospores surrounded by abundant capsular material. Hematoxylin-eosin stain; original magnification 250 ×.

developed subsequently) cryptococcal meningoencephalitis (with positive culture, microscopic examination, and antigenemia performed on the cerebrospinal fluid), associated with fungemia and disseminated disease (with recovery of fungal organisms from blood cultures in 6 cases, and isolated serum cryptococcal antigenemia in the remaining 2 patients). A severe impairment of the cell-mediated immune defence was present in all cases (with a mean CD4+ lymphocyte count of 39.5 ± 19.5 cells/mm³), and other AIDS-related opportunistic infections had been diagnosed previously or concurrently with cryptococcosis in 3 patients (Table I). In 3 out of 8 cases, the skin lesions preceded the appearance of neurologic and systemic manifestations of fungal disease by 2, 5, and 6 weeks, respectively, while in the remaining 5 subjects cutaneous localization occurred during the first episode (3 cases) or a subsequent relapse (2 cases) of cryptococcal meningoencephalitis and widespread visceral disease. When the course of disease of all 30 observed cases of AIDS-related extrapulmonary cryptococcosis was assessed, cutaneous localization was regarded as an unfavourable prognostic sign, significantly related to a rapidly fatal outcome: 6 subjects out of 8 who experienced no response to antifungals and early death, had mycotic skin lesions ($p < .002$, Fisher exact test) (Table I). In fact, in these 6 patients the onset of cutaneous localization was followed by a fairly rapid fatal course of disease (2 to 11 weeks), despite seemingly appropriate systemic antifungal

therapy, while only 2 subjects obtained clinical remission associated with the cure of fungal skin lesions.

DISCUSSION

Cutaneous localization is known to involve less than 10% of AIDS patients suffering from extrapulmonary cryptococcosis, when large series of HIV-infected subjects with this fungal complication are reviewed, and is usually considered as a sign of disseminated infection appearing only in the late stages of the disease course (2, 4–6), even if primary cutaneous cryptococcosis has occasionally been observed in this patient group (7). Morphologic features of cryptococcal skin lesions have been described mostly as single case reports (2, 8–11); their broad clinical spectrum includes polymorphic aspects, often leading to a problematic differential diagnosis, since they can resemble other skin diseases or other cutaneous manifestations of systemic AIDS-related disorders (2–4, 8–11). Abscesses, cellulitis, nodules, papules, pustules, granulomas, ulcers and patches may be observed, as single or more frequently multiple skin lesions, with occasional involvement of oral mucosa; in a considerable number of cases, skin localization can mimic other disorders commonly found in AIDS patients, such as Kaposi's sarcoma, molluscum contagiosum, ulcerative herpes, acne, pyoderma gangrenosum, or purpura (2–4, 8–11). In very rare cases, mostly during the pre-AIDS era, skin involvement has been reported to precede the appearance of signs and symptoms of disseminated disease and to represent the sole clue to diagnosis (2, 12).

In our series, cutaneous localization of *C. neoformans* infection showed a remarkably increased incidence when compared with literature series (4–6, 10), and in 3 out of 8 cases it occurred even 2 to 6 weeks before the first appearance of neurologic and systemic signs and symptoms of disease, thus representing an early clue of initial disseminated cryptococcosis.

In conclusion, our experience suggests that a careful clinical, microscopic, cultural, and histopathological examination of all suspected skin lesions in patients with advanced HIV disease, even without evident signs and symptoms suggestive of systemic complications, may lead to an earlier recognition

of extrapulmonary cryptococcosis, thus allowing a timely specific treatment of this potentially fatal opportunistic disease.

REFERENCES

- Zalla MJ, Su WP, Fransway AF. Dermatologic manifestations of human immunodeficiency virus infection. *Mayo Clin Proc* 1992; 67:1089–1108.
- Pema K, Diaz J, Guerra LG, Nabhan D, Verghese A. Disseminated cutaneous cryptococcosis. Comparison of clinical manifestations in the pre-AIDS and AIDS eras. *Arch Intern Med* 1994; 154:1032–1034.
- Cohen PR, Grossman ME. Recognizing skin lesions of systemic fungal infections in patients with AIDS. *Am Fam Phys* 1994; 49:1627–1634.
- Hay RJ. Clinical manifestations and management of cryptococcosis in the compromised patient. In: Warnock DW, Richardson MD, eds. *Fungal infections in the compromised patient*. 2nd edn. Chichester: John Wiley & Sons, 1991:85–115.
- Kovacs JA, Kovacs AA, Polis M, Wright WC, Gill VJ, Tuazon CU, et al. Cryptococcosis in the acquired immunodeficiency syndrome. *Ann Intern Med* 1985; 103:533–538.
- Rozenbaum R, Rios Gonçalves AJ. Clinical epidemiological study of 171 cases of cryptococcosis. *Clin Infect Dis* 1994; 18:369–380.
- Song IC, Hunter JG. Primary cutaneous cryptococcosis as the presenting manifestation of AIDS. *Plast Reconstr Surg* 1992; 18:1065–1067.
- Manrique P, Mayo J, Alvarez JA, Ganchegui X, Zabalza I, Flores M. Polymorphous cutaneous cryptococcosis: nodular, herpes-like, and molluscum contagiosum-like lesions in a patient with the acquired immunodeficiency syndrome. *J Am Acad Dermatol* 1992; 26:122–124.
- Picon L, Vaillant L, Duong T, Lorette G, Bacq Y, Besnier JM, et al. Cutaneous cryptococcosis resembling molluscum contagiosum: a first manifestation of AIDS. *Acta Derm Venereol (Stockh)* 1989; 69:365–367.
- Ghigliotti G, Carrega G, Farris A, Burrioni A, Nigro A, Pagano G, et al. Cutaneous cryptococcosis resembling molluscum contagiosum in a homosexual man with AIDS. Report of a case and review of the literature. *Acta Derm Venereol (Stockh)* 1992; 72:182–184.
- Durden FM, Elewski B. Cutaneous involvement with *Cryptococcus neoformans* in AIDS. *J Am Acad Dermatol* 1994; 30:844–848.
- Chu AC, Hay RJ, MacDonald DM. Cutaneous cryptococcosis. *Br J Dermatol* 1980; 103:95–100.