

Flare-up at Contact Allergy Sites in a Gold-treated Rheumatic Patient

HALVOR MÖLLER¹, ÅKE LARSSON², BERT BJÖRKNER¹, MAGNUS BRUZE¹ and ÅSA HAGSTAM³

Departments of ¹Dermatology and ²Rheumatology, Malmö University Hospital and ³Oral Pathology, School of Dentistry, Lund University, Malmö, Sweden

Contact allergy to gold sodium thiosulfate and gold sodium thiomalate was established by skin testing in a rheumatic patient intended for gold therapy. An intramuscular test dose of gold sodium thiomalate (Myocrisin®) induced a flare-up of previously positive epicutaneous and intradermal test reactions, with a histological and immunohistochemical picture compatible with an allergic contact dermatitis. Since gold allergy is frequent, the cutaneous side-effects of gold therapy ("gold dermatitis") may be explained by such an immunopathological reaction. Key words: gold sodium thiosulfate; gold sodium thiomalate; patch test; systemic provocation.

(Accepted June 29, 1995.)

Acta Derm Venereol (Stockh) 1996; 76: 55–58.

H. Möller, Department of Dermatology, Malmö University Hospital, S-205 02 Malmö, Sweden.

Cutaneous side-effects occur frequently during systemic treatment with gold salts; actually, when the number of cutaneous drug reactions is correlated to the frequency of use, gold compounds take the top position of the ranking list (1). Gold dermatitis may have a varying clinical picture but is generally considered an expression of an immunologic reaction. Still, in vivo (patch) and in vitro tests usually fail to confirm a presumed gold allergy (2, 3).

With a new test technique for patch and intradermal tests (4) a high frequency of contact allergy to gold sodium thiosulfate has been demonstrated in patients examined for eczematous disease. We have also shown (5) that patients with a contact allergy to gold sodium thiosulfate consistently react also to gold sodium thiomalate. Since this latter chemical is widely used as an antirheumatic drug (Myocrisin®), we found it warranted to study the relationship between contact allergy to gold salts and an attempt to gold therapy in a rheumatic patient.

CASE REPORT

The patient, a 52-year-old woman, was included in our prospective study on contact allergy to gold in patients elected for gold therapy. She had a seropositive rheumatoid arthritis since 3 years, with disappointing response to previous treatments with naproxen and methotrexate.

The patient was patch-tested with the Swedish standard series, with gold sodium thiosulfate and with gold sodium thiomalate (Myocrisin®). The concentrations for gold sodium thiosulfate were 0.5–10% w/v and for gold sodium thiomalate 36%, all dissolved in petrolatum. Extensive investigations have shown that these test concentrations are non-irritative (unpublished data). The patches were applied for 48 h on the upper back with Finn chambers® on Scanpor®. The patient was also tested with the two gold salts intradermally (0.55 mM in saline) on the volar aspect of one forearm.

At test reading on day 3 and day 7 all patch and intradermal tests

were negative. About 2 weeks after test application some test reactions were noted by the patient, and after a further week (D 21) they were read with positive findings (Table I).

During the following week the test reactions abated and on day 33 the patient obtained a test dose of gold sodium thiomalate (Myocrisin®), 10 mg i.m. On the following day, the patient noticed increased itch, redness, and size of the healing and symptomless test reactions which could be confirmed next day (day 35), see Table I. Now, patch as well as intradermal tests were activated with erythema and edematous infiltration, i.e. a purely dermal reaction. Punch biopsies were taken from the gold sodium thiomalate flare-up reaction for routine histopathology and immunohistochemistry. No other dermatitis was observed. During the following weeks all test reactions disappeared. No further treatments with gold salts were attempted.

Microscopically, perivascular infiltrates of mononuclear lymphocytic cells appeared in the reticular and the lower papillary dermis (Fig. 1). In the upper papillary dermis, a more diffuse lymphocytic infiltrate was accompanied by some oedema, but with no granulocytes and no eosinophils. In the epidermis, a few lymphocytic cells could also be demonstrated, in addition to some vacuolar change in the basal layers (Fig. 2).

Immunocytochemically, the lymphocytic infiltrates were composed of cells expressing T-cell (CD3) but not B-cell (L26) markers. These infiltrates contained a mixture of "naive" (PD7, Leu18, Fig. 3) and "memory" (UHCL1, Fig. 4) type T-cells; some of these cells were found to encroach closely upon and could also be demonstrated within the epidermis (Fig. 3).

With one exception, the patient had been using gold jewellery without problems. A golden necklace would – now and then but usually not – give rise to slight irritation and red patches on her neck, appearing hours or days after her starting to wear it, and disappearing rapidly after removal. She had no visual gold fillings in her mouth and was not aware of any other dental gold.

DISCUSSION

It was shown by epicutaneous and intracutaneous testing that the patient had a contact allergy to gold sodium thiosulfate

Table I. Skin tests to gold salts

– negative, (+) barely perceptible, + erythema and infiltration, ++ erythema, infiltration and papules, # erythema, oedematous infiltration

Patch tests	%	Gold i.m.			
		D 3	D 7	D 21	D 35
Gold sodium thiosulfate	0.5	–	–	–	–
Gold sodium thiosulfate	2.0	–	–	+	#
Gold sodium thiosulfate	5.0	–	–	++	#
Gold sodium thiosulfate	10.0	–	–	++	#
Gold sodium thiomalate	36.0	–	–	++	#
Intradermal tests	mM				
Gold sodium thiosulfate	0.55	–	–	(+)	# (6 × 6 mm)
Gold sodium thiomalate	0.55	–	–	(+)	# (10 × 10 mm)



Fig. 1. Section of biopsy taken from flare-up reaction of patch test with gold sodium thiomalate. An infiltration of cells is seen at several vessels (arrows). HE-stained section, $\times 90$.

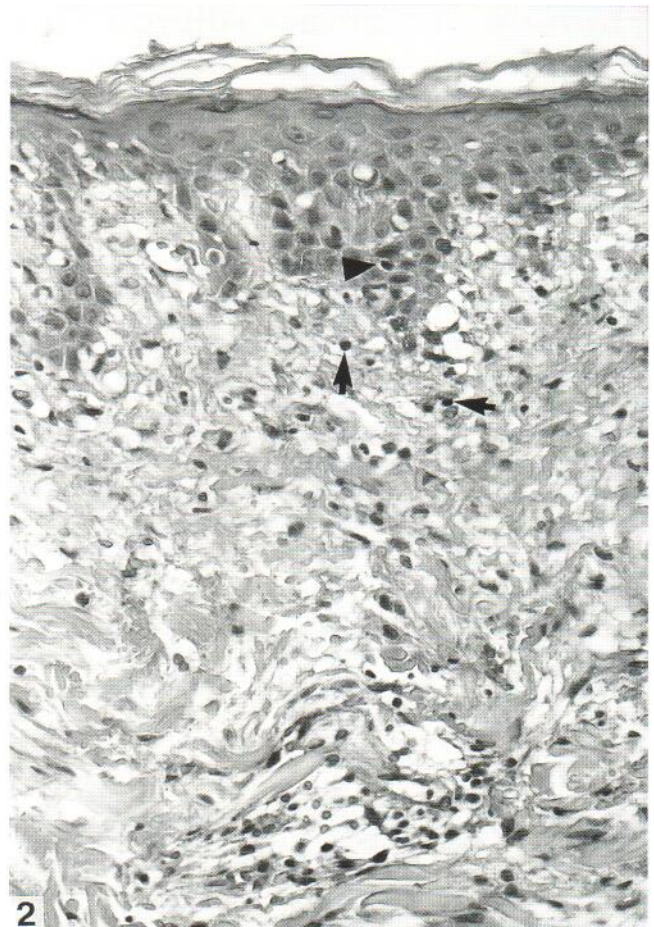


Fig. 2. Higher magnification of epidermis-papillary dermis from the biopsy depicted in Fig. 1. Mononuclear lymphocytic cells are present in slightly oedematous dermis (arrows) but also in the epidermis (arrow head), where vacuolar change is also evident mainly in the basal layers. HE-stained section, $\times 370$.

and gold sodium thiomalate which, however, was not detectable on the regular reading day (D3), nor on the 7th day after test application. The late appearance of positive skin tests has recently been shown to be characteristic of gold sodium thiosulfate in particular, and not necessarily a sign of test sensitization (6); therefore, gold allergy might be missed if the test reading is not repeated. In this particular case, the allergy should be considered weak since the patch test with our screening concentration (0.5%) was persistently negative.

If patients with a contact allergy are exposed systemically – accidentally or experimentally – to their allergen, several types of cutaneous reactions can occur (7, 8). First, a previous contact dermatitis may flare up; this also includes a previously positive, but later healed, patch test. Second, a symmetric rash, more or less extensive, may appear. In the present patient, the healed patch tests to gold sodium thiomalate flared when the allergen was given intramuscularly, a reaction characteristic of “endogenous” contact dermatitis. The specificity of the flare-up reaction has earlier been demonstrated by oral provocation in nickel allergy (9). However, the injection of gold sodium thiomalate also activated the healed patch tests to gold sodium thiosulfate, confirming the agreement in reactivity recently demonstrated by patch and intradermal testing (5).

The skin memory function (10), as illustrated by the flare-

up phenomenon, was easily activated in this case of weak contact allergy, using a fifth of the regular intramuscular dose for the challenge. Furthermore, the flare-up comprised not only the eczematous (healed) lesion but also the dermal one. Most probably, a regular dose of 50 mg gold sodium thiomalate would have resulted in a vigorous dermatitis. Such a provocation could not, for ethical reasons, be carried out. Obviously then, a clear-cut “gold dermatitis” has not been demonstrated by the present systemic administration of the patient’s contact allergen. A uniform clinical or histopathological picture does not, however, occur of the skin complications following gold therapy (11). This means that eczematous as well as dermal lesions and rashes occurring in “gold dermatitis” – as in the present case – may be elicited by mechanisms similar to those working in “endogenous contact dermatitis”.

It has been suggested (9) that nickel-induced flare-up reactions at previous nickel patch test sites may be elicited in a way different from regular contact dermatitis. However, proof of this is lacking and indeed, the factor(s) that triggers leukocyte extravasation at the site of flare-up is unknown. In the present paper on gold, we argue – based on circumstantial evidence – that the tissue factor(s) inducing a positive contact allergy patch test to an epicutaneously applied gold salt

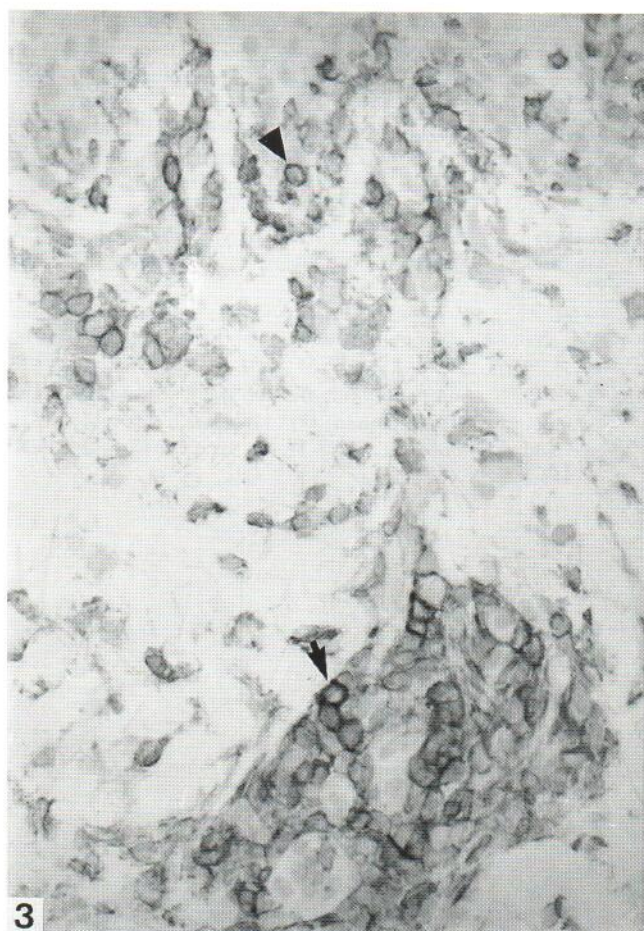


Fig. 3. Frozen section of the case illustrated in Fig. 1, incubated with PD7 antibody ("naive T"). A significant number of stained cells occur in the papillary dermis, at a blood vessel (arrow) including single cells within the lumen, and also more diffusely in adjacent tissue close to the epidermis. Stained cells can also be demonstrated within the epidermis (arrow head), $\times 370$.

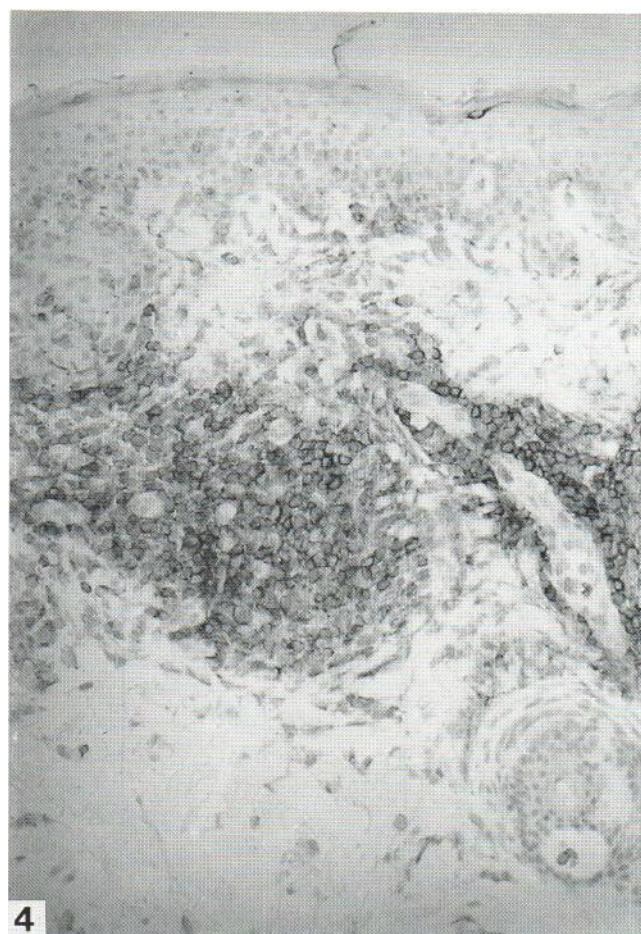


Fig. 4. Frozen section of the case illustrated in Fig. 1, incubated with UCHL-1 antibody ("memory T"). Stained cells occur in the lower papillary dermis, close to blood vessels and with a few cells also close to the epidermis, $\times 185$.

corresponds to a priming of the tissue, which is operational also in the development of a subsequent flare-up reaction following injection of the gold at a distant intramuscular site.

More research is required in order to define the nature of this priming, but since small amounts of i.m.-injected gold are known to be distributed to skin, mostly to dermis and less to epidermis (12), it is reasonable to assume that the injected gold itself should somehow be a precipitating factor at the flare-up site. Obviously, additional local factors specific to the previous test site but absent from the other gold-loaded skin sites must also be involved. Since the i.m.-injected gold reaches the previous test site via the circulation, the vascular endothelium may be part of a "primed tissue factor". Part of such a local factor(s) may also be lymphocytic. Scheper & von Blomberg (10) believe that a few allergen-specific T-cells may remain for long periods at previous skin reaction sites, being instrumental in the flare-up reactivity. Based on the present findings, it is tempting to think that such cells may be resting, memory-type T-cells. For such residual T-cells to become reactivated, an anticipated gold allergen must be presented to them locally. Hence, an antigen-presenting cell population such as dermal macrophages or dendrocytes may play an important role, at the flare-up as well as at the contact

allergy/patch test site, as recently discussed in a paper on gold contact allergy (13). Further studies are required in order to clarify the relative role of these or of other cells as part of a common pathogenetic link between these two types of skin lesions.

The conclusions to be drawn from this single case are that contact allergy to gold sodium thiomalate may be disclosed by carefully monitored skin tests with this salt or with gold sodium thiosulfate; that systemic provocation with this antirheumatic drug activates a previous eczematous and dermal dermatitis; and that patients intended for chrysotherapy should perhaps be examined before treatment with proper skin tests.

ACKNOWLEDGEMENTS

The investigative procedure was approved by the Ethics Committee of the Medical Faculty, Lund University.

REFERENCES

1. Swanbeck G, Dahlberg E. Cutaneous drug reactions. An attempt to quantitative estimation. *Arch Dermatol Res* 1992; 284: 215-218.

2. Svensson Å, Theander J. Skin rashes and stomatitis due to parenteral treatment of rheumatoid arthritis with sodium aurothiomalate. *Ann Rheum Dis* 1992; 51: 326–329.
3. Goldermann R, Schuppe H-C, Gleichmann E, Kind P, Merk H, Rau R, et al. Adverse immune reactions to gold in rheumatoid arthritis: lack of skin reactivity. *Acta Derm Venereol (Stockh)* 1993; 73: 220–222.
4. Björkner B, Bruze M, Möller H. High frequency of contact allergy to gold sodium thiosulfate – an indication of gold allergy? *Contact Dermatitis* 1994; 30: 144–151.
5. Bruze M, Björkner B, Möller H. Skin testing with gold sodium thiomalate and gold sodium thiosulfate. *Contact Dermatitis* 1995; 32: 5–8.
6. Bruze M, Hedman H, Björkner B, Möller H. The development and course of test reactions to gold sodium thiosulfate. *Contact Dermatitis*, in press.
7. Menné T, Hjorth N. Reactions from systemic exposure to contact allergens. *Semin Dermatol* 1982; 1: 15–24.
8. Tomb R, Grosshans E. Complications systémiques de l'allergie de contact médicamenteuse. *Sem Hôp Paris* 1991; 67: 1245–1248.
9. Christensen OB, Lindström C, Löfberg H, Möller H. Micro-morphology and specificity of orally induced flare-up reactions in nickel-sensitive patients. *Acta Derm Venereol (Stockh)* 1981; 61: 505–510.
10. Scheper RJ, von Blomberg BME. Cellular mechanisms in allergic contact dermatitis. In: Rycroft RJG, Menné T, Frosch PJ, eds. *Textbook of contact dermatitis*. Berlin, Heidelberg: Springer Verlag, 1995: 11–27.
11. Penneys NS, Ackerman AB, Gottlieb NL. Gold dermatitis. A clinical and histopathological study. *Arch Dermatol* 1974; 109: 372–376.
12. Penneys NS, Kramer K, Gottlieb NL. The quantitative distribution of gold in skin during chrysotherapy. *J Invest Dermatol* 1975; 65: 331–333.
13. Möller H, Larsson Å, Björkner B, Bruze M. The histological and immunohistochemical pattern of positive patch test reactions to gold sodium thiosulfate. *Acta Derm Venereol (Stockh)* 1994; 74: 417–423.