

Q-switched Ruby Laser Application Is Safe and Effective for the Management of Actinic Lentigo (Topical Glycolic Acid Is Not)

DAISY KOPERA¹, ULRICH HOHENLEUTNER² and MICHAEL LANDTHALER²

Departments of Dermatology, ¹University of Graz, Graz, Austria and ²University of Regensburg, Regensburg, Germany

A study was designed to evaluate the effectiveness of a single q-switched ruby laser exposure to erase actinic lentigo. A peeling fluid containing glycolic acid designed to treat lentigines was evaluated comparatively. Ten female patients presenting with actinic lentigines on the forearms and dorsal aspects of their hands were treated with the q-switched ruby laser on the right side. Single ruby laser irradiation of actinic lentigines on the dorsal aspects of forearms and hands caused transient crusting due to exfoliation of the epidermal surface, which generally lasted for 2 weeks. Four weeks after treatment total fading of the lesions was evident. Topical application of peeling fluid applied on the left forearms caused burning sensations, local irritation and superficial scaling but could not clear the lentigines.

A single course of q-switched ruby laser exposure is safe and efficient for the management of actinic lentigines, as it completely clears these obvious signs of ageing. Topical treatment of lentigines using a commercial peeling solution leads to moderate or severe irritation and is ineffective.

(Accepted March 28, 1996.)

Acta Derm Venereol (Stockh) 1996; 76: 461–463.

D. Kopera, Department of Dermatology, University of Graz, Auenbruggerplatz 8, A- 8036 Graz, Austria.

Senile changes in Caucasian individuals include pigmentary irregularities in sun-exposed skin (actinic or senile lentigines). These brownish macules, commonly known as "liver spots" or "age spots" appear due to cumulative effects of exposure to ultraviolet radiation. Since in highly developed societies ageing has come "out of fashion" during the last decade (1), different approaches to erase these signs of old age have been reported, such as chemical peeling, cryotherapy, dermabrasion, superficial electrocautery and pigment-specific laser therapy.

We evaluated the effectiveness of q-switched ruby laser treatment in 10 female patients. A commercially available peeling fluid containing glycolic acid designed for the clearing of age spots was comparatively used to prove whether this type of topical treatment can be seen as an equivalent option for the management of actinic lentigo or not.

PATIENTS AND METHODS

Patients and study design

Ten female patients, aged 49 to 71 (average 52.9 years), presenting actinic lentigines on the dorsal aspects of their forearms and hands, were included in the study (Fig. 1, left side). Follow-up visits took place at weeks 4 and 6.

Ruby laser treatment

A quality switched ruby laser (Meltemi, NWL, Eckental, Germany) was used. Actinic lentigines on the right forearms and hands were exposed to a single course of ruby laser irradiation at an energy level of 4.5 J/cm², 4-mm spot size, and a pulse duration of 40 ns.

Topical treatment

Patients were instructed to apply a commercial peeling fluid, containing water, glycolic acid, ammonium glycolate and hydroxymethylcellulose on the age spots of their left forearms and dorsal aspects of hands every night for a period of 2 weeks. (Glycolic acid concentration and pH-value of the solution were not indicated.) According to the commercial instructions the liquid should be left on the skin for approximately 10 min before being washed off again. Additional application of sunscreen, consisting of a hydrophilic vehicle containing octylmethoxycinnamate and β -caroten, should be maintained in the treatment areas every morning for 4 weeks.

Skin biopsy sampling

Three punch biopsies of representative lentigines had been taken before treatment. Immediately after q-switched ruby laser treatment, five biopsies were obtained. Two representative follow-up biopsies from clinically cleared lesions were taken 2 weeks after ruby laser treatment. One biopsy was taken after 2 weeks of topical treatment with peeling fluid in a non-cleared lentigo.

RESULTS

Clinical outcome after q-switched ruby laser treatment

Right forearm and dorsal surface of hand. Immediately after a single q-switched ruby laser treatment, the colour of the skin surface turned into ash-white, possibly due to vaporisation of epidermal pigments. Two days later superficial crusting occurred in some treatment sites. Complete healing and fading of the lesions after 2 weeks was the rule in all patients (Fig. 1, right side). Postlesional erythema could be observed in 5 patients.

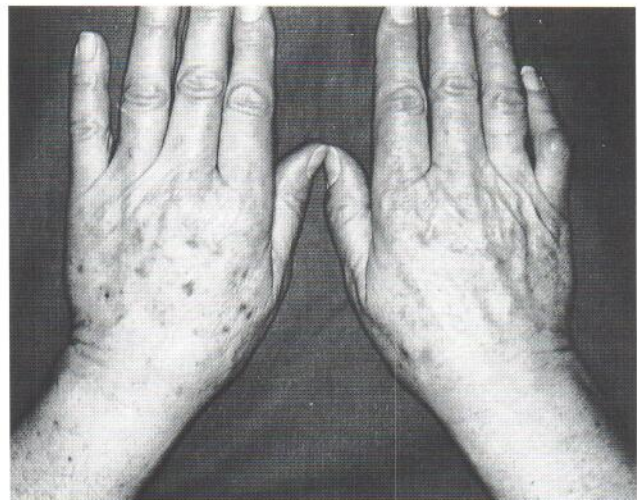

Fig. 1. Actinic lentigo: right forearm 4 weeks after q-switched ruby laser treatment; left forearm after a 2-week course of topical treatment with glycolic acid overlapped by 4 weeks of local application of sunscreen.

Clinical outcome after topical glycolic acid treatment

Left forearm and dorsal surface of hand. In 5 patients mild to moderate burning and/or itching scaling appeared after the first week of treatment. Three patients did not feel any discomfort. Superficial dryness, erythema, and/or scaling was the rule. One patient complained of severe burning sensations following application and discontinued the treatment after 7 days. One patient who did not wash off the fluid after 10 min, but left it on overnight instead, stopped the treatment after 4 days because of severe burning. In this patient, a 1-cm necrotic eschar was located on the dorsum of the left hand where the largest lentigo macule was located. Although superficial epidermal scaling occurred in all patients, clearing of actinic lentigines could not be achieved with this type of topical treatment (Fig. 1, left side).

Histopathological examination before treatment

Histopathological examination of the biopsy specimens taken before treatment showed the characteristics of actinic lentigo, featuring a compactly orthokeratotic cornified layer, slightly elongated rete ridges resembling the shape of "hockey sticks", and increased pigmentation in and around the basal cell layer (Fig. 2). Solar elastosis could be found in all cases.

Immediately after q-switched ruby laser exposition vacuolisation was evident in the basal region and in the superficial dermis (Fig. 3). Due to the large number of vacuoles, some of them confluent, epidermal ablation could be seen in parts of the lesions, clinically causing discrete crusting. The samples taken 2 weeks after ruby laser treatment featured basket weave keratosis of the epidermis and a regular epidermal strating without elongation of the rete ridges. Basal pigmentation was markedly reduced (Fig. 4).

Histopathological examination of a biopsy specimen taken of one lentigo after a 2-week course of daily application of glycolic acid peeling fluid still presented the histopathological features of actinic lentigo, as shown in Fig. 2.

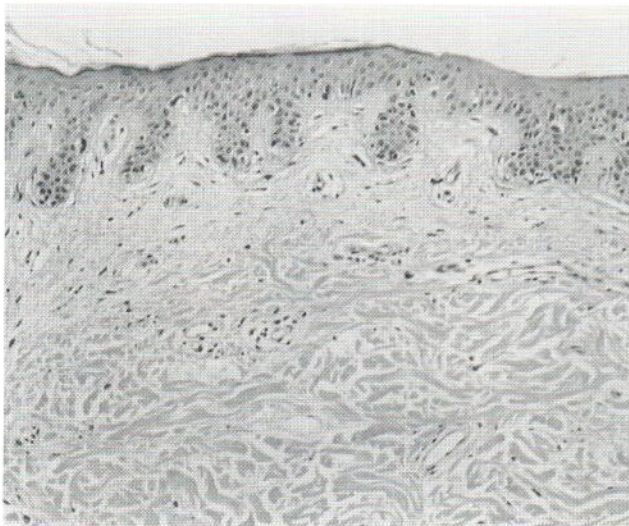


Fig. 2. Actinic lentigo: histopathology before treatment: compactly orthokeratotic cornified layer, slightly elongated rete ridges resembling the shape of "hockey sticks", and increased pigmentation in and around the basal cell layer, moderate solar elastosis in the dermis.

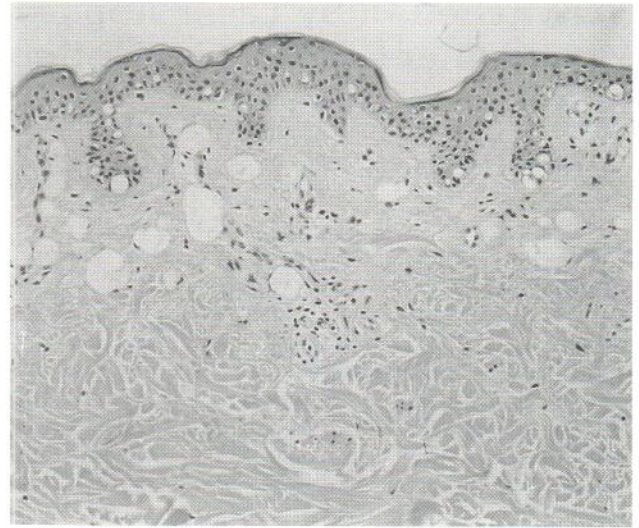


Fig. 3. Actinic lentigo: histopathology immediately after q-switched ruby laser treatment: vaporizing pigment causes vacuolisation in the basal region.

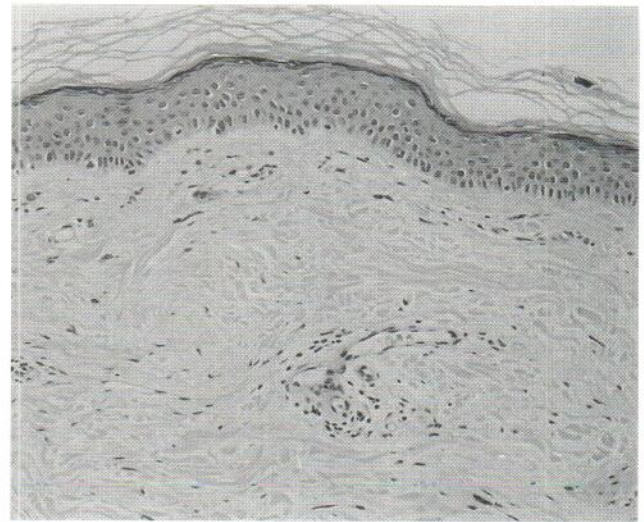


Fig. 4. Actinic lentigo: histopathology 2 weeks after q-switched ruby laser treatment: Basket weave keratosis of the epidermis showing a regular strating without elongation of the rete ridges. Basal pigmentation is markedly reduced.

DISCUSSION

Actinic lentigines, commonly known as "liver spots", or "age spots", are also labelled "senile lentigo", or "solar lentigo" in dermatological terms. They are relatively large (up to 1 cm in diameter), irregularly shaped, mottled, tan to brown, occasionally scaly lesions that develop on chronically sun-exposed areas, especially in Caucasian individuals after the age of 40 (2).

The use of various kinds of lasers has been reported for the treatment of pigmented lesions. The unspecific thermal damage set by a CO₂-laser (10,600 nm) resulted in superficial scarring comparable to the results following dermabrasion. Better results have been achieved with laser systems emitting at wavelengths between 500 nm and 755 nm specifically absorbed

by dark pigments (argon 488 nm and 514 nm, pulsed dye 510 nm, frequency-doubled q-switched Nd:Yag 532 nm, Alexandrite 755 nm). The ruby laser emitting at 694 nm has shown very promising results in the treatment of bluish-black tattoos (3–6). Much experience of ruby laser application in pigmented lesions has been gained in the treatment of naevus of Ota, an uncommon congenital oculocutaneous melanosis showing a bluish or grey-brown aspect due to melanin-producing intradermal melanocytes and sometimes affecting the sclera of the ipsilateral eye. Mostly, an average of four treatment courses is necessary to reach sufficient clearing in these dermally pigmented benign lesions (7–10). In blue naevi, an average of three courses of q-switched ruby laser exposure has been reported to achieve sufficient fading of the lesions (11). Treatment of melanocytic lesions, however, remains controversial, due to surviving unpigmented or deep dermal melanocytes (12).

The ruby laser emits light of 694 nm, a wavelength better absorbed by melanin (melanosomes) than by other optically absorbing structures in the skin. With this selectively absorbed wavelength, highly selective target damage can be expected if the pulse duration is less than the approximate thermal relaxation time of the target chromophore (selective photothermolysis) (13). The quality-switched mode allows the release of all laser energy stored in the cavity in one brief pulse, so high energies can be applied in pulses of approximately 40 ns. Targeted pigments absorb these powerful light impulses, transform them into heat, and evaporate within the skin, producing a conspicuous vapour bubble (vacuolisation). Due to high energy density, short impulse duration, and the selective absorption adjacent tissue is affected minimally. In lesions offering dense basal pigmentation epidermal ablation may occur. In benign pigmented lesions revealing pigmentation limited to the basal cell layer area, e.g. actinic lentigo or simple lentigo, a single course of q-switched ruby laser treatment is sufficient for clearing (14).

Peeling agents of many kinds have been proclaimed in the dermatological literature and commercialized by the cosmetic industry, to eradicate these undesired markers of ageing (15). To evaluate the equivalency of these therapeutic options, we compared topical application of a commercial peeling solution to q-switched ruby laser treatment for the management of actinic lentigines. Our results show that a single course of q-switched ruby laser therapy can remove lentigines safely and effectively without adverse reactions, whereas the peeling fluid is ineffective and as a side-effect causes moderate irritation of the skin.

Within a short follow-up period of 6 weeks we did not observe recurrence of lentigines after q-switched ruby laser treatment (16). However, repigmentation of lentigo maligna 4 years after argon laser therapy has been reported. In case of repigmentation of actinic lentigo we recommend histological

examination before a second course of q-switched ruby laser treatment is administered to clear the lesion.

A single 40-ns exposure of the macular lesions to the q-switched ruby laser led to complete removal of actinic lentigines, whereas topical application of a commercial glycolic acid peeling solution caused discomfort and irritation without clearing of the lesions. We therefore conclude that due to selective photothermal injury of skin pigments (melanin granules, melanosomes, pigmented cells), q-switched ruby laser treatment represents a safe and efficient treatment of actinic lentigo.

REFERENCES

1. Graham-Brown RAC, Ebling FJG. The ages of man and their dermatoses. In: Rook A, Wilkinson R, Ebling H, eds. *Textbook of dermatology*. Oxford: Blackwell, 1992.
2. Ackerman AB, Mendoca AMN, eds. *Differential diagnoses in dermatopathology*. Philadelphia: Lea and Febiger, 1992: 138–141.
3. Reid WH, Miller ID, Murphy MJ, Paul JP, Evans JH. Q-switched ruby laser treatment of tattoos; a 9-year experience. *Br J Plast Surg* 1990; 43: 663–669.
4. Scheibner A, Kenny G, White W, Wheeland RG. A superior method of tattoo removal using the q-switched ruby laser. *J Dermatol Surg Oncol* 1990; 16: 1091–1098.
5. Taylor CR, Anderson RR, Grange RW, Michaud NA, Flotte TJ. Light and electron microscopic analysis of tattoos treated by q-switched ruby laser. *J Invest Dermatol* 1991; 97: 131–136.
6. Kilmer SL, Lee MS, Grevelnik JM, Flotte TJ, Anderson RR. The q-switched Nd-YAG laser effectively treats tattoos. *Arch Dermatol* 1993; 129: 971–978.
7. Geronemus RG. Q-switched ruby laser therapy of nevus of Ota. *Arch Dermatol* 1992; 128: 1618–1622.
8. Goldberg DJ, Nychay SG. Q-switched ruby laser treatment of nevus of Ota. *J Dermatol Surg Oncol* 1992; 18: 817–821.
9. Lowe NJ, Wieder JM, Sawcer D, Burrows P, Chalet M. Nevus of Ota: treatment with high energy fluences of the q-switched ruby laser. *J Am Acad Dermatol* 1993; 29: 997–1001.
10. Watanabe S, Takahashi H. Treatment of nevus of Ota with the q-switched ruby laser. *N Engl J Med* 1994; 331: 1745–1750.
11. Milgraum SS, Cohen ME, Auletta MJ. Treatment of blue nevi with the Q-switched ruby laser. *J Am Acad Dermatol* 1995; 32: 307–310.
12. Kopera D, Hohenleutner U, Landthaler M. Q-switched ruby laser treatment of pigmented lesions. *J Invest Dermatol* 1995; 105: 461.
13. Anderson RR, Parrish JA. Selective photothermolysis: precise microsurgery by selective absorption of pulsed radiation. *Science* 1983; 220: 524–527.
14. Goldberg DJ. Benign pigmented lesions of the skin. Treatment with the q-switched ruby laser. *J Dermatol Surg Oncol* 1993; 19: 376–379.
15. Kotler R, ed. *Chemical rejuvenation of the face*. St. Louis: Mosby, 1992.
16. Arndt KA. New pigmented macule appearing 4 years after argon laser treatment of lentigo maligna. *J Am Acad Dermatol* 1986; 14: 1092.