

## Lobular Panniculitis Associated with Venous Congestion in Right-sided Heart Failure

*Sir,*

Nodular panniculitis is a descriptive term which refers to the presence of inflammatory nodules in the subcutaneous fat. Traditionally a discrimination is made between septal, lobular and mixed panniculitis according to the pattern of inflammation, i.e. whether it occurs in the interlobular septa, in the lobule proper or both (1, 2). Septal panniculitis is usually associated with erythema nodosum, while the lobular type has various causes. Some of the different main forms have distinct histological features and/or are associated with typical laboratory findings, aiding the diagnostic evaluation (2, 3), but in about 50% of the cases the aetiology remains unknown (idiopathic panniculitis).

We report here a patient with venous congestion secondary to right-sided heart failure associated with primary pulmonary hypertension, who developed nodular panniculitis in the subcutaneous fat of the abdominal wall. A temporal relationship was noted between the development of severe heart failure and the occurrence of tender subcutaneous nodules. These nodules disappeared promptly after successful treatment of the pulmonary hypertension and heart failure.

### CASE REPORT

The patient was a 24-year-old woman, slightly overweight, but previously healthy, except for a history of mild allergic asthma. In May 1991 she noticed for the first time an unusual exertional dyspnoea

during a skiing holiday. No further symptoms were experienced until the spring of 1992, when exertional dyspnoea recurred. During the following months, an upper abdominal pain and discomfort were added to her symptoms. She was admitted to a local hospital in the beginning of July 1992 after three episodes of fainting. The tentative diagnosis was acalculous cholecystitis and orthostatic hypotension. During the following 2 months she started to gain weight and to develop oedema of the lower extremities. At the same time, she noticed tender nodules in the subcutaneous fat of the abdominal wall. In September a diagnosis of pulmonary hypertension with secondary right heart failure was made, explaining the episodes of syncope, dyspnoea, abdominal pain and oedema. She was then admitted to our hospital, and on admission was found to have right-sided heart failure of NYHA class IV, and generalised oedema corresponding to a weight gain of approximately 15 kg. Ultrasonographic examination of the abdomen revealed ascites and marked portal hypertension. Tender nodules on the anterior abdominal wall were observed. Punch biopsies of these nodules revealed a picture of panniculitis of the mixed type, but with a predominantly lobular pattern, in the subcutaneous fat (Fig. 1a). Histologically there was quite extensive fat necrosis with early lipophagia. The most striking features were an abundant extravasation of red blood cells and the presence of fibrinoid thrombi in capillary vessels (Fig. 1b). Only a sparse inflammatory response, with mostly macrophages and a few lymphocytes, was observed. There was no sign of vasculitis or of a granulomatous reaction.

The further clinical investigation of the patient included pulmonary vessel radiology with pressure recordings, and laboratory tests for coagulopathy, serum amylase,  $\alpha_1$ -antitrypsin and other acute phase reactants, antibodies against nuclei, DNA and neutrophil cyto-



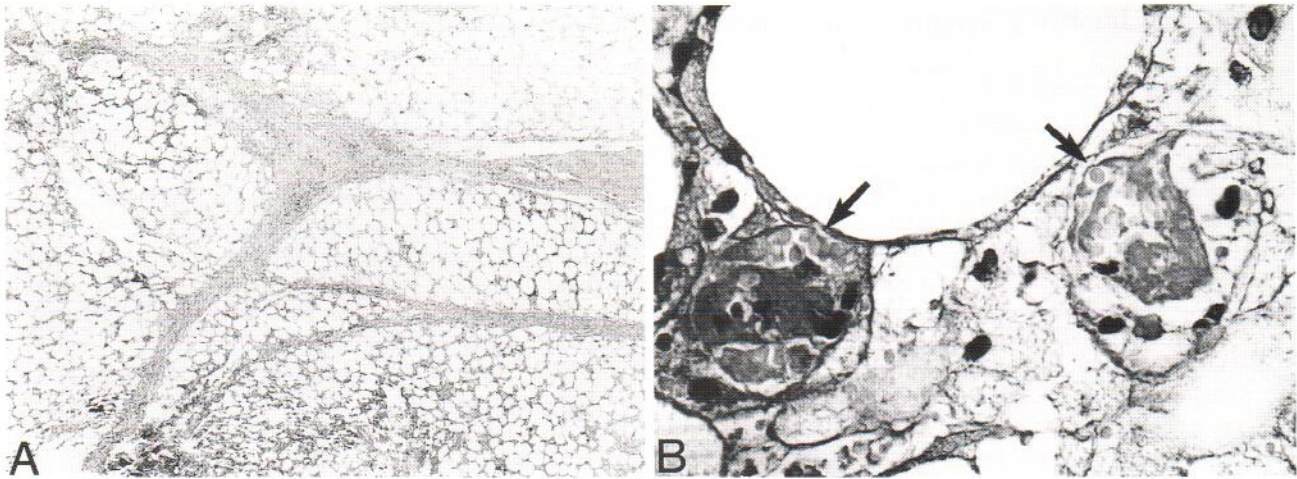


Fig. 1. Histological features of subcutaneous nodule taken from the abdominal wall. A) Low magnification showing panniculitis of the mixed type, predominantly with a lobular pattern (H & E,  $\times 25$ ). B) High magnification showing panniculitis with two capillaries (arrows) partially occluded by microthrombi, and extravasation of red blood cells. A macrophage reaction is seen in the fatty tissue (PAS  $\times 400$ ).

plasm, and serum complement activity. No evidence of pancreatitis,  $\alpha_1$ -antitrypsin deficiency, systemic vasculitis (e.g. secondary polycythaemia, thrombocytosis, autoantibodies), thromboembolic disorders or venous disease was obtained. After diuretic treatment the heart failure slightly improved, but the panniculitis and pulmonary hypertension persisted.

The high-dose nifedipine test procedure and treatment protocol established by Rich et al. (4) was used and a prompt reduction of the pulmonary hypertension was achieved. Within 2 weeks of treatment with nifedipine (140 mg daily), the nodules had disappeared without leaving any scars or depressions. This coincided in time with rapid normalisation of the cardiac function. Nifedipine treatment was well tolerated, except for the development of gingival hyperplasia. When a change was made to amlodipine (15 mg/day), the gingival hyperplasia disappeared, without deterioration of cardiac function. Now, after 3 years of observation and treatment, the working capacity and pulmonary haemodynamics are normal and the patient has not experienced any recurrent episodes of panniculitis.

## DISCUSSION

A close temporal relationship between the occurrence of painful subcutaneous nodules and the clinical signs of venous congestion in both the systemic and portal circulation was noted. The disappearance of these manifestations also coincided in time. The positive effect of calcium-blocking agents on the lobular panniculitis is probably due to the normalisation of venous pressure, although a direct effect on the subcutaneous tissue of the abdominal wall cannot be ruled out. We speculate that in predisposed individuals, an abnormal vessel reactivity may lead to the development of both pulmonary

hypertension and certain forms of panniculitis. Alternatively, it is conceivable that microthrombi, as were found in the subcutaneous nodules in the present case, could form in small vessels and capillaries of the pulmonary circulation, thereby causing pulmonary hypertension. Although we did not find any evidence of thromboembolic disease either radiologically or in laboratory tests, this possibility cannot be excluded. The changes in the subcutaneous vasculature and in the pulmonary circulation may therefore be similar and may give clues to the pathogenetic mechanisms underlying both of these disorders.

## REFERENCES

1. Lever WF, Schaumberg-Lever G. Inflammatory diseases of the subcutaneous fat. In: *Histopathology of the skin*. 7th edn. Philadelphia: Lippincott Company, 1990: 269–283.
2. Ryan TJ. Panniculitis: its pathogenesis and management. In: Champion RH, Pye RJ, eds. *Recent advances in dermatology 9*. London: Churchill Livingstone, 1991: 17–32.
3. Black MM. Panniculitis: problems with diagnosis. *Australas J Dermatol* 1988; 29: 79–84.
4. Rich S, Kaufmann E, Levy PS. The effect of high doses of calcium-channel blockers on survival in primary pulmonary hypertension. *N Engl J Med* 1992; 327: 76–81.

Accepted February 29, 1996.

Eystein S. Husebye<sup>1</sup>, Fredrik Pontén<sup>2</sup> and Lars Wibell<sup>1</sup>  
 Departments of <sup>1</sup>Internal Medicine and <sup>2</sup>Pathology, University Hospital, S-751 85 Uppsala, Sweden.