

Generalised Acanthosis Nigricans with Vitiligo

ULRIKE BLUME-PEYTAVI, TILMAN SPIEKER, HANSJÖRG REUPKE and CONSTANTIN E. ORFANOS

Department of Dermatology, University Medical Center Benjamin Franklin, Free University of Berlin, Berlin, Germany

We report on a 19-year-old woman with generalised acanthosis nigricans of the inherited type and concomitant vitiligo. Cutaneous velvety thickening of the skin with intensification of skin markings and progressive development of hyperpigmented papillomatous, verrucoid lesions in the body folds started to develop in early childhood. These hyperpigmentations were continuously replaced by a progressive vitiligo, finally leaving most of the acanthosis nigricans lesions completely depigmented. Generalised, pachyderma-like acanthosis nigricans with concomitant vitiligo is an association which to the best of our knowledge has not yet been described. Key words: acanthosis nigricans generalisata; inherited type.

(Accepted February 19, 1996.)

Acta Derm Venereol (Stockh) 1996; 76: 377–380.

Ulrike Blume-Peytavi, MD, Department of Dermatology, University Medical Center Benjamin Franklin, The Free University of Berlin, Hindenburgdamm 30, D-12200 Berlin, Germany.

Acanthosis nigricans is characterised by hyperpigmented velvety thickening of the skin on any part of the body, most typically located in the axilla, the neck, the submammary, the genital, and the umbilical areas. The first cutaneous change is hyperpigmentation, followed by intensified skin markings and varying degrees of hypertrophy of the epidermis without induration. Generally, the colour of the lesions is brown but may be yellow, grey or black; the colour, representing melanin deposition, fades at the margin. Soft papillomatous and warty nodules may stud the affected surface. The degree of cutaneous involvement varies from subtle hyperpigmentation and some papillary thickening, affecting limited skin areas, to deeply pigmented and verrucoid lesions over large areas, including even mucous membranes.

Four types of acanthosis nigricans exist: inherited, endocrine, malignant and so-called pseudoacanthosis nigricans type (1–3). The inherited type may have its onset during infancy, childhood or adulthood, with lesions usually developing in the flexural areas (1, 2). The endocrine type is associated with a pituitary tumour such as in acromegaly, with polycystic ovary syndrome, with insulin resistance, or with Hashimoto thyroiditis (4–6). The malignant type is more extensive and has more pronounced lesions, with an onset usually after the age of 40 years. This type is generally associated with a malignant tumour, particularly an adenocarcinoma, mainly of gastric origin (Table I) (7, 8). Pseudoacanthosis nigricans can be observed in obesity (9), but also after intake of drugs such as nicotinic acid (10), diethylstilbestrol (11) or corticosteroids (2).

Vitiligo is supposed to be an antibody-associated autoimmune disease with depigmented macules, preferentially located in skin areas which are usually hyperpigmented such as the face, the axillae, the areolae mammae, and the groins (12, 13). Vitiligo is sometimes associated with autoimmune and

endocrine disorders such as thyroid disease, diabetes mellitus, and alopecia areata (12), but also with malignant melanoma (14).

We describe the case of a 19-year-old woman with generalised pachyderma-like acanthosis nigricans with vitiligo. To the best of our knowledge this peculiar association has not been reported before.

MATERIAL AND METHODS

A 19-year-old woman presented with generalised hyperpigmented thickening of her entire skin, with an increased cobblestone-like skin marking. In the perioral, the nuchal, the axillary, and the genital area mammillated, verrucoid and warty lesions were most prominent. Even the mammillae and the surrounding hyperpigmented areolae were involved in this process and presented small filiform warty lesions.

Table I. Association of acanthosis nigricans or of vitiligo with various other disorders

Acanthosis nigricans	Vitiligo
I. Association with genetic syndromes	
● Autosomal recessive ectodermal dysplasia (15)	● Autosomal recessive ectodermal dysplasia (15)
● Ataxia teleangiectatica (1, 2)	
● Bloom syndrome (1, 2)	
● Stein-Leventhal syndrome (1, 2)	
● Lawrence-Seip syndrome (2)	
● Hypogonadal syndromes with insulin resistance (1, 2)	
● Acanthosis nigricans with polythelia, polycystic kidneys and syndactyly (6)	
II. Association with autoimmune and endocrine disorders	
● Hashimoto thyroiditis (5, 21, 22)	● Thyroid diseases (21)
● Diabetes mellitus and insulin resistance types A, B, C (4, 5, 16)	● Diabetes mellitus (12)
● Acromegaly (2)	● Atopic eczema (23)
● Cushing's disease (2)	● Alopecia areata (12)
● Addison's disease (2)	● Pernicious anaemia (12)
III. Association with neoplasia	
● Adenocarcinoma: stomach (62%), hepatic, uterus, ovary tract (8, 24)	● Malignant melanoma (14, 25)
● Bronchial carcinoma (10%) (26)	
● Breast cancer (3%)	
● Rarely cancer of the testes, pancreas (8)	
● Hodgkin and Non-Hodgkin lymphoma, mycosis fungoides, sarcoma very rarely (26)	

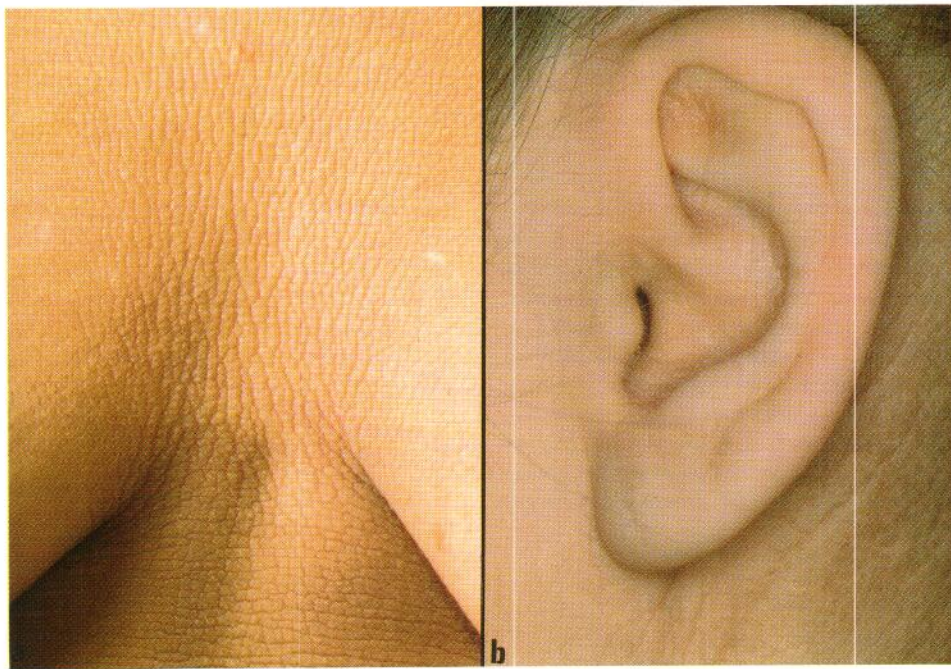


Fig. 1. (a) Generalised coarsening of the skin with pronounced skin line pattern. (b) Grade 1 dysplasia of the ear conch.

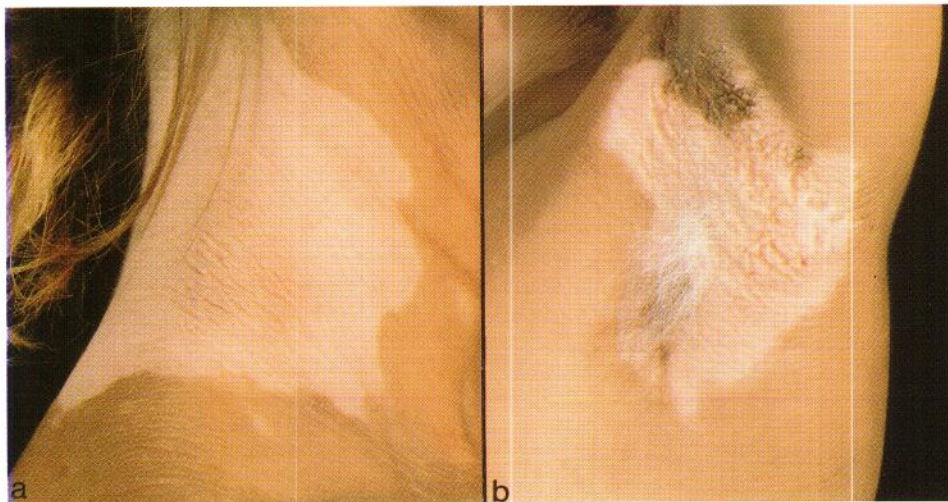


Fig. 2. (a) Elevated papillomatous skin folds in the nuchal region, with circumscribed sharply delineated hypopigmented areas. (b) In the axillary region, clearly delineated depigmented papillomatous skin with white depigmented hair. In the extreme lower and upper part are areas of brownish-greyish hyperpigmentation of a velvety texture.

The skin changes had started at the age of 4 years, with thickening of the skin showing a pronounced skin line pattern over the entire body (Fig. 1a). Predominantly the flexural areas, such as the nuchal (Fig. 2a) and the axillary region (Fig. 2b), presented brownish hyperpigmentations covered by small papillomatous and warty elevations of velvety texture corresponding to acanthosis nigricans. About 7 years later the patient developed large depigmented areas in the neck, the abdomen, the groins, and the popliteal areas. These depigmented lesions only progressed slowly for several years, leaving the acanthosis nigricans lesions in the body folds nearly completely depigmented when the patient presented for the first time at our department (Fig. 2a, b). There was no family history of similar skin lesions or of any other skin diseases except for a mild form of ichthyosis vulgaris in her mother and one cousin.

RESULTS

Diagnostic procedures

Clinical examination. Extended clinical examinations, including internal, gynaecological, urological and neurological consultation, revealed no evidence for any malignant disease or neoplasm. The patient presented only grade 1 dysplasia of the ear conch (Fig. 1b), but no other signs of ectodermal dysplasia (teeth, bones, etc).

Laboratory findings. Laboratory findings were normal, including blood cell counts, liver and kidney function tests, electrolytes, protein electrophoreses, and hormone levels (hypophysis,

ovaries, thyroid and adrenal glands). Vitamin levels and tumour markers were also within the normal range, except antinuclear antibodies of 1:80 with a freckled pattern and a CD4/CD8 ratio of 1.0.

Direct high-power light microscopy (DHP-LM). The skin surface of the face, the trunk, the nuchal and the axillary region was examined by DHP-light microscopy. This system consists of a flexible and transportable electronic microscope, enabling the direct investigation and analysis of skin lesions and skin surface even in difficult body localisation, with a magnification from 10 up to 400 times. In our patient we could observe an accentuated skin line pattern in the intermammary region (Fig. 3a) and pronounced skin marking around the mouth (Fig. 3b). Verrucoid regions with papillomatous and hyperproliferative warty lesions could well be delineated (Fig. 3c, d).

Histology. Low magnification of a typical lesion in the axillary region showed epidermal papillomatosis and mild to moderate slightly irregular acanthosis with hyperkeratosis. The papillomatosis was caused by hypertrophy of dermal papillae with formation of "fingerlike" projections (Fig. 4a). Besides hyperpigmentation of the basal layer, areas of depigmentation could also be observed, with complete absence of melanocytes in the basal layer. Histological examination of the skin in the intermammary region with cobblestone-like skin marking revealed important papillomatosis and acanthosis (Fig. 4b).

DISCUSSION

The patient described here presented with two distinct clinical entities, i.e. acanthosis nigricans and vitiligo. Moreover, our patient showed velvety pachyderma-like thickening of the skin with a cobblestone skin pattern in a generalised distribution. Typically, acanthosis nigricans is only localised in the body folds such as the neck, the axillae, the genitals and the antecubital and popliteal areas. On occasion, especially in malignant acanthosis nigricans and in female patients with insulin resistance type A (2), the eruption may become almost generalised. In all cases of acanthosis nigricans, a thorough

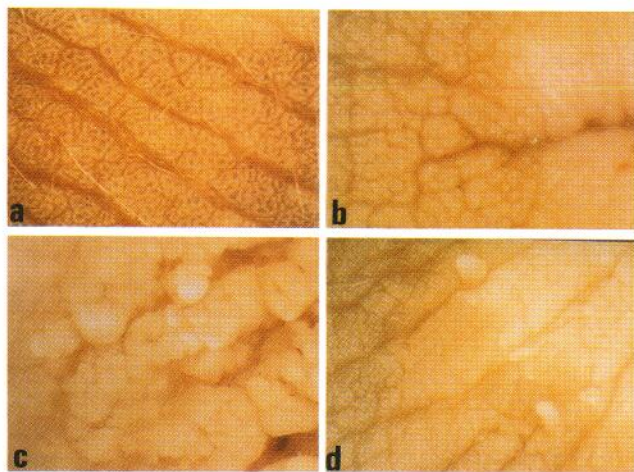


Fig. 3. Examination of the skin by direct high-power light microscopy (DHP-LM) (1:25): (a) intermammary region with pronounced skin line pattern, (b) angle of the mouth with elevated skin folds and narrowings, (c) hyperproliferative warty lesions in the centre of the axillary region and (d) at the lower border from acanthosis nigricans to pachyderma-like skin.

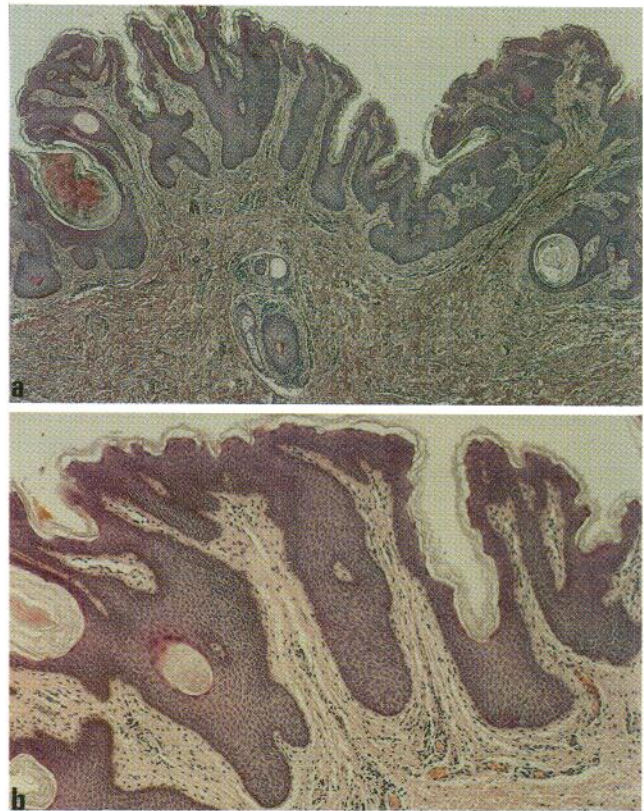


Fig. 4. (a) Histology taken from the axillary region showing hyperkeratosis and irregular papillomatosis, alternating with areas of attenuation and "fingerlike" projection of the dermal papillae (haematoxylin and eosin, 40 \times). (b) Biopsy taken from the submammary region, presenting important papillomatosis (haematoxylin and eosin, 60 \times).

clinical examination should be performed to exclude the presence of any neoplasm (8), all the more as the four types of acanthosis nigricans – inherited, endocrine, malignant and pseudoacanthosis nigricans – are clinically indistinguishable (3). Based on our patient's history and the normal results of the careful clinical and laboratory examination, acanthosis nigricans of the inherited type was diagnosed. Interestingly, in our patient the lesions involved the entire integument and in addition, a progressive vitiligo led to a nearly complete depigmentation of the acanthosis nigricans lesions in the body folds. In the literature, only three patients with circumscribed lesions of acanthosis nigricans in the body folds and perioral and periorbital diffuse hypopigmentation in the general frame of a peculiar autosomal recessive ectodermal dysplasia have been reported (15). To the best of our knowledge this association of acanthosis nigricans generalisata with concomitant occurrence of vitiligo has not been reported before.

Acanthosis nigricans is most likely a disorder of the epidermis, possibly due to abnormal epidermal proliferation and qualitative differences in the stratum corneum. The aetiology of acanthosis nigricans is still not elucidated; however, different theoretical approaches have been proposed: (i) acanthosis nigricans is probably a reaction to elevated levels of a chemical factor stimulating keratinocytes and dermal fibroblasts at the cell receptor level (4, 16); (ii) peptide growth factors might bind to cell receptors and stimulate epidermal growth (17, 18); (iii) in malignant acanthosis nigricans a peptide with

growth factor properties produced by the tumour might be implicated; (iv) there may be growth-promoting effects of insulin itself in insulin-resistant syndrome (18), especially as the insulin receptor has an intrinsic tyrosine kinase activity essential for signal transduction (19); and (v) in some patients with acanthosis nigricans antibodies against the insulin receptors have been identified (2).

In vitiligo evidence for the involvement of both cell-mediated and humoral immunity in generalised vitiligo (16) and also the presence of circulating antimelanocyte antibodies in vitiligo patients have been reported (20).

When these hypotheses are taken into consideration, it can be concluded that the onset of acanthosis nigricans may predate a variety of different autoimmune diseases or can be associated with a disordered immunoreactivity (21). This may possibly help to explain the association of acanthosis nigricans with other autoimmune processes, such as vitiligo in our patient.

REFERENCES

- Matsuoka LY, Wortsman J, Goldman J. Acanthosis nigricans. *Clin Dermatol* 1993; 11: 21–25.
- Schwartz RA. Acanthosis nigricans. *J Am Acad Dermatol* 1994; 31: 1–19.
- Lever WF, Schaumburg-Lever G. Metabolic diseases. In: Lever WF, Schaumburg-Lever G, eds. *Histopathology of the skin*. Philadelphia: J.B. Lippincott Company, 1990: 477–478.
- Rendon MI, Cruz PD, Sontheimer RD, Bergstresser PR. Acanthosis nigricans: a cutaneous marker of tissue resistance to insulin. *J Am Acad Dermatol* 1989; 21: 461–469.
- Ober KP. Acanthosis nigricans and insulin receptor resistance associated with hypothyroidism. *Arch Dermatol* 1985; 121: 229–231.
- Bonnekoh B, Wevers A, Spangenberg H, et al. Keratin pattern of acanthosis nigricans in syndrome-like association with polythelia, polycystic kidneys, and syndactyly. *Arch Dermatol* 1993; 129: 1177–1182.
- Abeloff MD. Paraneoplastic syndromes: a window on the biology of cancer. *N Engl J Med* 1987; 317: 1598–1600.
- Andreev VC. Malignant acanthosis nigricans. *Semin Dermatol* 1984; 3: 265–272.
- Hirokawa M, Matsumoto M, Iizuka H. Confluent and reticulated papillomatosis: a case with concurrent acanthosis nigricans associated with obesity and insulin resistance. *Dermatology* 1994; 188: 148–151.
- Elgart ML. Acanthosis nigricans and nicotinic acid (Letter). *J Am Acad Dermatol* 1981; 5: 709–710.
- Banuchi SR, Cohen L, Lorincz AL, et al. Acanthosis nigricans following diethylstilbestrol therapy: occurrence in patients with childhood muscular dystrophy. *Arch Dermatol* 1974; 109: 545–546.
- Cunliffe WJ, Hall R, Newell DJ. Vitiligo, thyroid disease and autoimmunity. *Br J Dermatol* 1968; 80: 135–139.
- Abdel-Naser MB, Krüger-Krasagakes S, Krasagakis K, et al. Further evidence for involvement of both cell mediated and humoral immunity in generalized vitiligo. *Pigment Cell Res* 1994; 7: 1–8.
- Schallreuter KU, Berger J. Vitiligo and cutaneous melanoma: a case study. *Dermatologica* 1991; 183: 239–245.
- Lelis J. Autosomal recessive ectodermal dysplasia. *Cutis* 1992; 49: 435–437.
- Ellis DL, Kafka SP, Chow JC, et al. Melanoma, growth factors, acanthosis nigricans, the sign of Leser-Trélat, and multiple acrochordons: a possible role for alpha-transforming growth factor in cutaneous paraneoplastic syndromes. *N Engl J Med* 1987; 317: 1582–1587.
- Lerner AB. On the cause of acanthosis nigricans. *N Engl J Med* 1975; 281: 106–107.
- Sheretz EF. Improved acanthosis nigricans with lipodystrophic diabetes during dietary fish oil supplementation. *Arch Dermatol* 1988; 124: 1094–1096.
- Taira M, Hashimoto N. Human diabetes associated with a deletion of the tyrosine kinase domain of the insulin receptor. *Science* 1989; 245: 63–66.
- Naughton GK, Eisinger M, Bystryk JC. Detection of antibodies to melanocytes in vitiligo by immunoprecipitation. *J Invest Dermatol* 1983; 81: 540–542.
- Sturmer RA, Denning S, Marchase P. Acanthosis nigricans and autoimmune reactivity. *JAMA* 1981; 246: 763–765.
- Atkinson AB, Kennedy L, Andrews WJ, et al. Diverse endocrine presentations of the syndrome of acanthosis nigricans and insulin resistance. *J R Coll Physicians Lond* 1989; 23: 165–169.
- Perfetti L, Cespa M, Nume A, Orecchia G. Prevalence of atopy in vitiligo: a preliminary report. *Dermatologica* 1991; 182: 218–220.
- Zaerko VV. Acanthosis nigricans in patients with stomach cancer. *Klin Med (Mosk)* 1992; 70: 50–52.
- Schallreuter KU, Lemke R, Brandt O, et al. Vitiligo and other diseases: coexistence or true association? *Dermatology* 1994; 188: 269–275.
- Gheeraert P, Goens J, Schwartz RA, et al. Florid cutaneous papillomatosis, malignant acanthosis nigricans, and pulmonary squamous cell carcinoma. *Int J Dermatol* 1991; 30: 193–197.