

# Topical Treatment by Urea Reduces Epidermal Hyperproliferation and Induces Differentiation in Psoriasis

INGKE HAGEMANN and EHRHARDT PROKSCH

Department of Dermatology, University of Kiel, Kiel, Germany

The mechanisms of action of urea-containing ointments in the treatment of eczema, ichthyosis and psoriasis are only partly known and related to proteolysis and keratinolysis. In this study, we have examined the effects of topical urea on epidermal proliferation and differentiation in 10 patients with psoriasis. Plaque type lesions were treated for 2 weeks with an ointment containing 10% urea, with the vehicle alone, or left untreated. Clinical score, hydration of the stratum corneum, transepidermal water loss (TEWL), and immunohistochemical studies were performed. Epidermal proliferation was assessed using the Ki-S3 proliferation-associated nuclear antigen. For epidermal differentiation antibodies against involucrin and against keratins CK 5, 6, 17 and CK 1, 5, 10, 14 were used.

The patients showed a reduction of the clinical score (>50%), a 2-fold increase in stratum corneum hydration ( $p < 0.01$ ), and a small decrease in TEWL (N.S.) on the urea-treated compared to the untreated site. Light microscopy studies revealed a 29% reduction in epidermal thickness ( $p < 0.01$ ); epidermal proliferation was decreased by 51% ( $p < 0.005$ ). The altered expression of involucrin and of cytokeratins (reduction of CK 5, 1 and 10 and induction of CK 6 and 17) was partially reversed. The ointment base also improved psoriasis, but urea was significantly better than the vehicle (urea: 40% reduction in epidermal proliferation vs. vehicle). In summary, these studies show that urea influences epidermal proliferation and differentiation in psoriasis. **Key words:** stratum corneum hydration; transepidermal water loss; DNA-synthesis; involucrin; cytokeratins.

(Accepted February 28, 1996.)

Acta Derm Venereol (Stockh) 1996; 76: 353–356.

Ehrhardt Proksch, M.D., Ph.D., Department of Dermatology, University of Kiel, Schittenhelmstr. 7, D-24105 Kiel, Germany.

Urea has a long history in dermatology and was originally used for the treatment of infected wounds (1). Treatment of eczema with a urea-containing formulation was reported in 1943 by Rattner (2). Swanbeck showed the effect of urea in ichthyosis and other hyperkeratotic disorders (3). Today urea cream is widely used for the treatment of dry skin, eczema, and ichthyosis. There are only a few reports about the usefulness of urea in psoriatic skin. Swanbeck mentioned urea creams as adjuvant therapy for psoriasis (4). A combination of urea and dithranol has also been used (5).

The mechanism of action of urea in diseased skin is only partly known. An increased binding of water in the stratum corneum after treatment with urea is widely accepted (6). High concentrations of urea (6–30%) have proteolytic activity. It is a hydrogen bond breaker and has been used extensively in protein chemistry as a denaturing agent (7). Keratinolytic effects of urea have also been reported, which means a thinning of the stratum corneum and an increased loss of scales (8). Wohlrab & Schiemann found a reduction of  $^3\text{H}$ -thymidine incorporation in DNA by using a 50% urea solution on the

guinea pig ear and in healthy human skin (9). However, in diseased skin measurements of epidermal DNA synthesis after treatment with urea are not described. Also the effects of urea on epidermal differentiation are unknown. In this study we examined the effect of an ointment base containing 10% urea on stratum corneum hydration, on skin permeability barrier (transepidermal water loss (TEWL)), on epidermal proliferation, involucrin and keratin expression in psoriatic skin.

## MATERIALS AND METHODS

### Treatment regimens

The trial was approved by an Institutional Review Board and performed on 10 adult patients, over 18 years of age, with manifestation of a plaque type of psoriasis. The patients were untreated for at least 4 weeks. In a randomized double-blind study, three corresponding lesions on the extremities, namely right vs. left arm or right vs. left leg, with a size of at least 5 cm in diameter were treated by an ointment containing 10% urea (Basodexan S ointment), by the vehicle (without urea), or were left untreated. The ointments were applied three times a day for 2 weeks.

### Stratum corneum hydration and transepidermal water loss

Water content of the stratum corneum and transepidermal water loss, a marker of epidermal barrier function, were determined daily using an electrical capacitance recorder (Corneometer, Courage & Khazaka, Cologne, Germany), and a skin evaporative water recorder (10) (TEWA-meter, Courage & Khazaka, Cologne, Germany) respectively. Stratum corneum hydration was recorded in relative numbers (absolute numbers are not available) (11). During the course of all measurements, the relative environmental humidity was  $45 \pm 2\%$  and the room temperature was  $22 \pm 1^\circ\text{C}$ .

### Clinical assessment

The disease severity was assessed at week 0 (baseline), week 1, and week 2 (after 7 and 14 days of treatment). Scaling, erythema and induration were quantified by assigning a score from 0 to 5 based on severity as follows: 0, absent; 1, very mild; 2, mild; 3, moderate; 4, severe; and 5, very severe.

### Histological analysis

Four-millimetre punch biopsies from the borders of the lesions were taken under local anaesthesia at the end of the treatment period. For uninvolved skin the biopsies were taken at a distance of at least 4 cm from lesional skin. Hematoxylin and eosin-stained sections were studied by light microscopy. Epidermal thickness was determined with a calibration kit.

### Immunohistochemistry and antibodies

Immunohistochemical studies were performed in formalin-fixed paraffin-embedded sections. Epidermal proliferation was assessed by immunohistochemical methods in 6 patients using the Ki-S3 proliferation-associated nuclear antigen (R. Parwaresch, Department of Pathology, University of Kiel) (12). The stainings were performed on 6- $\mu\text{m}$  sections after heating in a microwave. Reactivity was visualized with a standard biotin-avidin immunostaining method, using a commercially available kit (Vecta Stain, Camon, Wiesbaden, Germany). The slides were evaluated using a Zeiss microscope along with a 1-mm

calibration kit, and the number of Ki-S3-positive cells was counted per square millimetre of nucleated epidermis. The number of Ki-S3-positive cells was counted by two trained persons. Only fully stained cells were counted. At each biopsy site, the mean number of Ki-S3-positive cells was determined from the number of cells in three sections taken at 100- $\mu$ m intervals.

For epidermal differentiation the monoclonal mouse anti-human cytokeratin DAKO-CK MNF 116 (CK 5, 6, 8, 17) and DAKO-CK 34BE12 (CK 1, 5, 10, 14) (DAKO, Glostrup, Denmark) were used. Involucrin was determined by an anti-human involucrin antibody (Paesel & Lorei, Frankfurt, Germany).

#### Statistical methods

Significant differences were determined using a Student *t*-test.

## RESULTS

### Clinical findings

All patients showed clinical improvement on the urea-treated sites. Erythema, scaling and induration were reduced. Scaling showed the greatest response after 2 weeks (-73%) and was already reduced after the first 2 days (data not shown) of treatment. Erythema and induration were also significantly reduced (-44% and -57%, respectively,  $p < 0.01$ ). Compared to the vehicle, after 2 weeks, urea was significantly better in reducing scaling (-60%) and induration (-32%) ( $p < 0.025$ ), but not significantly better in reducing erythema. Adverse reactions were not observed. The vehicle was also effective in reducing scaling and induration, but urea was significantly better than the vehicle.

### Stratum corneum hydration

Fig. 1 shows stratum corneum hydration determined daily over 14 days. Hydration was not significantly increased after application of the vehicle. In contrast, a significant increase in epidermal hydration was determined on the urea-treated sites (at 2 weeks: +73%,  $p < 0.025$ ). After 2 days of treatment, urea was significantly better than the vehicle. These results show that 10% urea in an ointment base increased stratum corneum hydration in psoriatic skin.

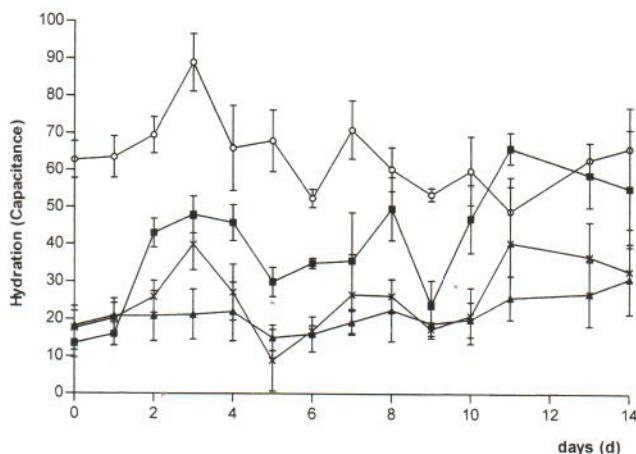


Fig. 1. Stratum corneum hydration of nonlesional skin ○, psoriatic skin (untreated) ▲, vehicle-treated skin X, and urea-treated skin ■.

### Transepidermal water loss

TEWL was not significantly decreased after treatment with either the vehicle or with the urea-containing ointment. TEWL in lesional skin after treatment was well above the levels of uninvolved skin ( $33 \pm 7$  and  $13 \pm 6$  g/m<sup>2</sup>/hr, respectively), showing ongoing disruption in epidermal permeability barrier. These results demonstrate that topical application of urea in an ointment base does not restore epidermal permeability barrier in psoriasis.

### Histological studies

Biopsies in urea-treated skin showed pronounced improvement of psoriasis. Hyperkeratosis, acanthosis, elongation of the rete ridges, and suprapapillary plate thinning were significantly reduced. The thickness of the epidermis was  $0.424 \pm 0.03$  mm before and  $0.301 \pm 0.03$  mm after treatment (-29%,  $p < 0.01$ ). In addition, a loss of confluent parakeratosis, development of orthokeratosis, and the reappearance of the granular layer were detected. In the vehicle-treated psoriatic skin significant changes were also noted, but the overall thickness of the epidermis and the elongation of the rete ridges were less on the urea-treated site. Histological changes could also be found in the slides stained with the Ki-S3 antibody for epidermal proliferation (Fig. 2A-D).

### Epidermal proliferation

As shown in Fig. 2A-D epidermal proliferation rate assessed by Ki-S3-positive cells was increased 9-fold in psoriatic lesions compared to uninvolved skin. Urea-treated skin showed a 51% decrease in epidermal proliferation ( $p < 0.005$ ). After application of the vehicle epidermal proliferation was slightly decreased (-19%), but the difference did not reach statistical significance. The urea-containing ointment was significantly better than the ointment base (DNA synthesis: -40%,  $p < 0.025$ ). These results show that urea treatment leads to significant reduction of epidermal proliferation in psoriatic skin.

### Involucrin

In normal epidermis the anti-human involucrin antibody showed a sharp band-like staining of the granular layers. In psoriatic skin we found a diffuse staining extending to the lower spinous layers (Fig. 3A). After treatment with urea the band-like staining was reduced to the upper spinous layers and the granular layers and showed sharper margins than in untreated and the vehicle-treated skin (Fig. 3B). The effect of the vehicle was less pronounced. These results show that urea treatment influences the expression of the cornified envelope protein involucrin in psoriatic skin.

### Keratins

In normal epidermis the anti-human cytokeratin antibodies MNF 116 and 34BE12 exhibited staining of the basal layers and lower spinous layers. In psoriatic lesions, staining of the basal layers was reduced and there was a diffuse staining of the spinous layers. This is in accordance with the known decreased expression of keratin 5 in the basal layers of psoriatic

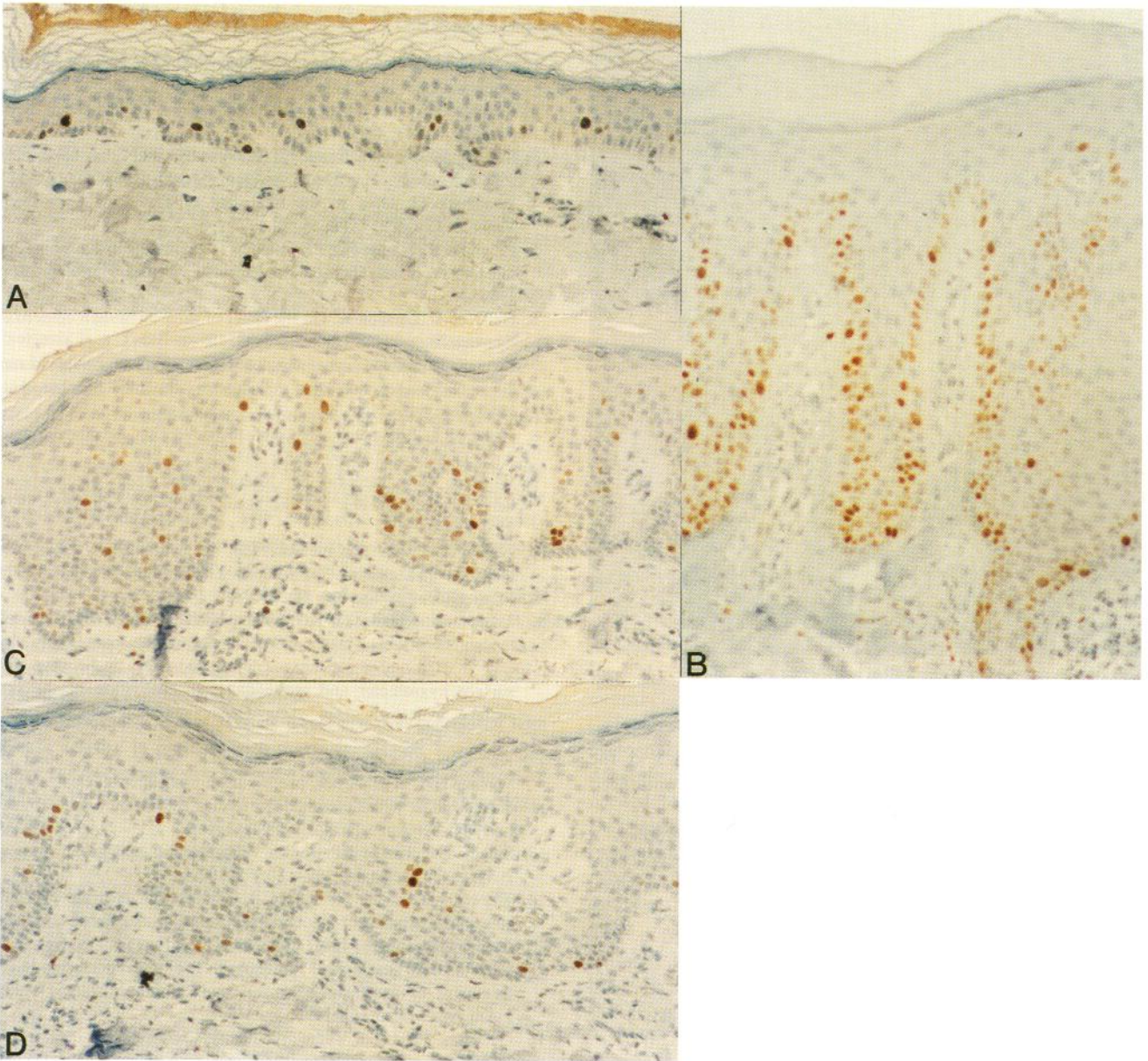


Fig. 2. Light microscopy and Ki-S3 immunostaining of nonlesional skin (A), psoriatic skin (un-treated) (B), vehicle-treated (C), and urea-treated skin (D) (magnification  $\times = 160$ ).

epidermis. In the suprabasal layers differentiation-related keratins 1 and 10 are replaced by proliferation-related keratins 16 and 17 (13, 14). Treatment with urea increased staining in basal and reduced staining in the suprabasal layers. This was more pronounced after treatment with urea compared to the vehicle (data not shown). The results demonstrate that urea influences keratin expression related to differentiation.

#### DISCUSSION

In this study, we found that treatment with a urea-containing ointment improved psoriasis. The clinical severity was reduced, hydration of the stratum corneum was significantly increased, and light microscopy studies showed an amelioration of the psoriatic phenotype. Remarkably, urea treatment reduced

epidermal DNA synthesis and induced epidermal differentiation. Previously, the mechanism of action of urea in diseased skin was related to the proteolytic and keratolytic effects of urea (7–9). We now point out that reduction of epidermal hyperproliferation and induction of differentiation could be important effects of urea in psoriasis. But it is still unknown how urea influences epidermal DNA synthesis and differentiation.

It is also important that the ointment base significantly improves psoriasis regarding the clinical scores for scaling and induration and regarding the differentiation markers involucrin and keratins. This could be related to the occlusive effect of the greasy ointment. Previously, it was shown that occlusion improves psoriasis (15, 16). But the urea-containing ointment produced significantly more improvement than the ointment

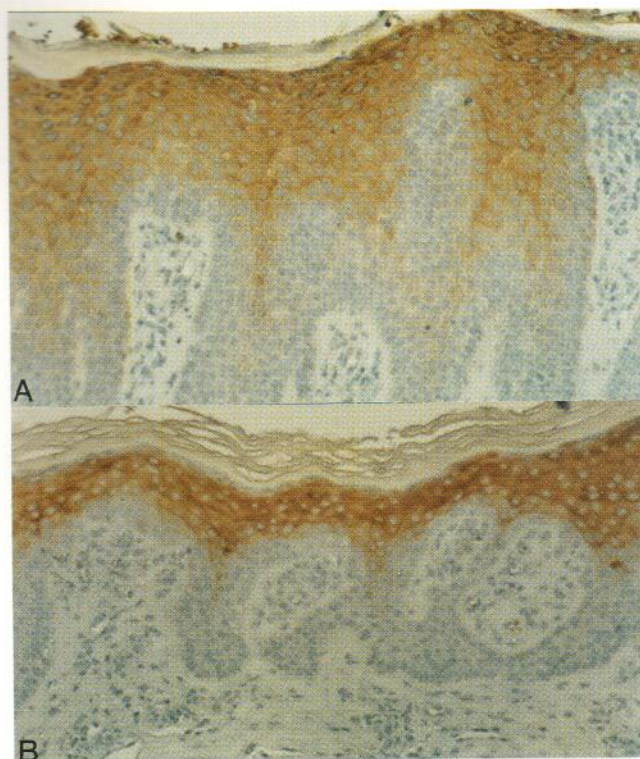


Fig. 3. Involucrin immunostaining of psoriatic skin (A) and urea-treated skin (B) (magnification  $\times = 160$ ).

base; the increase in stratum corneum hydration and the decrease in DNA synthesis were significantly more pronounced after treatment with urea.

Urea improves psoriasis but it does not accomplish a complete healing. The epidermal permeability barrier was only slightly improved. Urea does not have the same therapeutic potency as drugs like anthralin, PUVA, corticosteroids, or cyclosporine. For example, urea treatment showed a 53% reduction in DNA synthesis compared to PUVA-bath therapy, which showed a 73% reduction (17). However, urea seems to be suitable for adjuvant therapy in psoriasis. It is easy to use and lacks side-effects.

#### ACKNOWLEDGEMENTS

We thank C. Neumann for excellent technical assistance. T. Evers capably performed typing of the manuscript. Supported in part by a grant from Röhme Pharma (Darmstadt, Germany).

#### REFERENCES

1. Robinson W. Use of urea to stimulate healing in chronic purulent wounds. *Am J Surg* 1936; 33: 192–197.
2. Rattner H. Use of urea in hand creams. *Arch Derm Syph (Chicago)* 1943; 48: 47–49.
3. Swanbeck G. A new treatment of ichthyosis and other hyperkeratotic conditions. *Acta Derm Venereol (Stockh)* 1968; 48: 123–127.
4. Swanbeck G. Urea in the treatment of dry skin. *Acta Derm Venereol (Stockh)* 1992; Suppl 177: 7–8.
5. Przybilla B, Kaudewitz PK, Bieber T. Harnstoff in Kombination mit Dithranol zur Therapie der Psoriasis vulgaris. *Hautarzt Suppl* 1989; 40, IX: 54–57.
6. Hellgren L, Larsson K. On the effect of urea on human epidermis. *Dermatologica* 1974; 149: 289–293.
7. Katz S, Denis J. Mechanisms of denaturation of bovine serum albumin by urea and urea-type agents. *Biochim Biophys Acta* 1969; 188: 247–254.
8. Huber E, Christophers E. "Keratolytic" effect of salicylic acid. *Arch Dermatol Res* 1977; 257: 293–297.
9. Wohlrab W, Schiemann S. Untersuchungen zum Mechanismus der Harnstoffwirkung auf die Haut. *Arch Dermatol Res* 1976; 255: 23–30.
10. Nilson GE. On the measurement of evaporative water loss, methods and clinical application. Linköping University, 1977. Medical dissertation No. 48.
11. Hashimoto-Kumasaka K, Takahashi K, Tagami H. Electrical measurement of the water content of the stratum corneum in vivo and in vitro under various conditions: comparison between skin surface hygrometer and corneometer in evaluation of the skin surface hydration state. *Acta Derm Venereol (Stockh)* 1993; 73: 335–339.
12. Kreipe H, Heidebrecht HJ, Hansen S, Röhlk W, Kubbies M, Wacker HH, et al. A new proliferation-associated nuclear antigen detectable in paraffin-embedded tissues by the monoclonal antibody Ki-S1. *Am J Pathol* 1993; 142: 1–9.
13. Smack DP, Korge BP, James WD. Keratin and keratinization. *J Am Acad Dermatol* 1994; 30: 85–102.
14. Thewes M, Stadler R, Korge B, Mischke D. Normal psoriatic epidermis expression of hyperproliferation-associated keratins. *Arch Dermatol Res* 1991; 283: 465–471.
15. Griffiths CE, Tranfaglia MG, Kang S. Prolonged occlusion in the treatment of psoriasis: a clinical and immunohistologic study. *J Am Acad Dermatol* 1995; 32: 618–622.
16. Gerritsen MJP, van Vligmen-Willems, Chang A, van de Kerkhof PCM. The effect of hydrocolloid occlusive dressing (DuoDERM E) on keratinization in psoriasis vulgaris. *Acta Derm Venereol (Stockh)* 1994; 74: 483–484.
17. Vallat VP, Gilleaudeau P, Battat L, Wolfe J, Nabeya R, Heftler N, et al. PUVA bath therapy strongly suppresses immunological and epidermal activation in psoriasis: a possible cellular basis for remittent therapy. *J Exp Med* 1994; 180: 283–296.