

Congenital Ectopic Nails of the Fingers Associated with Bone Deformities

Sir,

Ectopic nail, known as congenital onychoheterotopia, was referred to as *polyonychie congenita sine polydactylie* in cases reported by Ohya in 1931 (1). A congenital ectopic nail is an additional nail independent of the normal nail, a relatively rare condition. Several authors (1-8,10) have described this condition, mainly in Japan, as an asymmetrical, non-hereditary, non-familial change involving one finger or toe, unlike most congenital disorders. We describe a patient with ectopic nails on the palmar tips of the right fifth and left fourth finger.

CASE REPORT

A 26-year-old Japanese woman presented with hard keratotic papules on the tip of the right fifth finger and the left fourth finger. Physical examination revealed a small hard oval, keratotic lesion, measuring 4 × 3 mm, with a rough surface at the center of the palmar aspect of the right fifth finger, which showed a clubbed appearance at the tip (Fig. 1A), and a thin small flattened keratotic lesion, just beneath the nail at the center of the ulnar aspect of the left fourth finger (Fig. 2A) without motor disturbance in the affected fingers. These hyperkeratotic lesions on the fingers had existed since birth and grew with the same speed as the other normal nails, so that she had to trim them occasionally. On closer examination and with information from the patient, they were determined to be nails. Radiography disclosed a Y-shaped bifurcation of the distal phalanx of the right fifth finger (Fig. 1B) and an M-shaped depressed deformity in the phalanx of the

left fourth finger (Fig. 2B), corresponding to the location of the ectopic nail.

Fusing of the distal interphalangeal joint of the bilateral fourth and fifth toes and latent bifidus of the sacral bone were also found on roentgenogram. Her family history was not contributory and no previous injuries to the affected fingers were noted. She was not seeking surgical removal of the ectopic nails at this time.

DISCUSSION

In 1931, Ohya (1) reported an ectopic nail, referring to it as *polyonychie congenita sine polydactylie*. Subsequently, Kikuchi (2) described two similar cases, for which he proposed the term "ectopic nail". Affected patients show no association of motor disturbance or other anomalies involving the fingers or toes. The present case can be differentiated from congenital onychodysplasia of the index finger (COIF or Iso-Kikuchi syndrome (9)), because the localization of the ectopic nails in COIF is restricted to the dorsal aspect of the finger. Similar conditions, such as polyonychia associated with syndactyilia and polydactyilia, can be differentiated by their clinical and radiographic appearance. In addition, acquired digital fibrokeratosis and supernumerary digits can be differentiated, since the lesions described had the clinical appearance of nail-plate with similar hardness and continuous growth.

Previously, some authors (1-8, 10) have described cases of Ohya's type congenital ectopic nail. A patient with ectopic

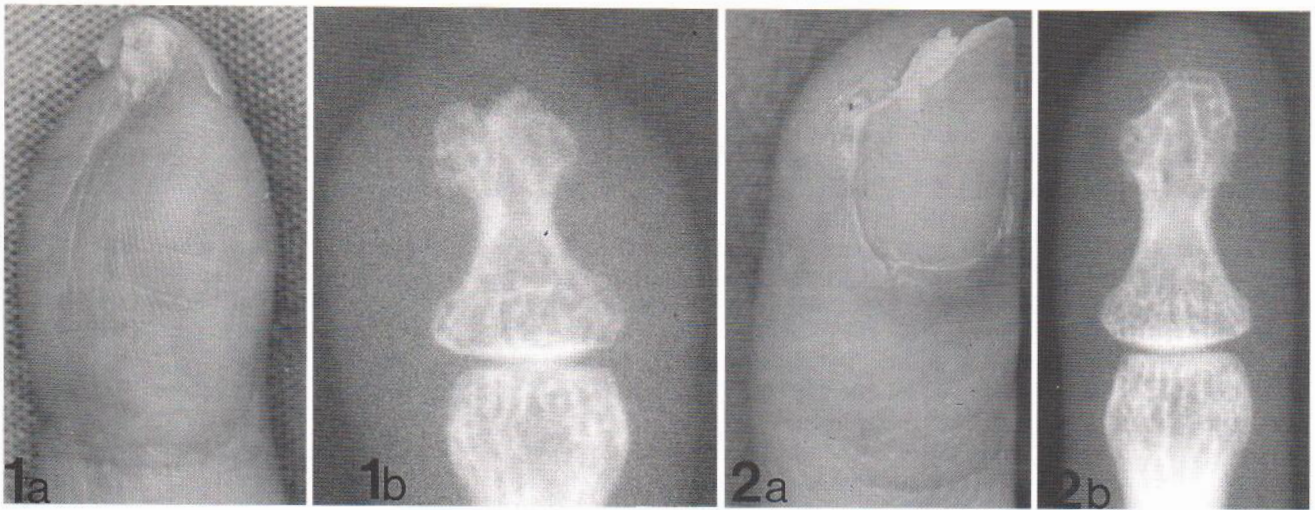


Fig. 1. (a) Ectopic nail on the palmar tip of the right little finger. (b) Xeroradiograph showing Y-shaped bone deformity.

Fig. 2. (a) Ectopic nail just beneath the nail of the left ring finger. (b) Xeroradiograph showing M-shaped bone deformity.

nails involving two fingers has not previously been described in the literature. In addition, M-shaped and Y-shaped bone deformities of the affected fingers were demonstrated on roentgenologic observations in the present case. Associations with bone deformities were described only by Yamasaki et al. (4) and Higashi (6). Yamasaki et al. (4) showed an M-shaped deformity of the distal phalanx of the affected little finger (similar to that in Fig. 2B). In contrast, Higashi (6) showed a Y-shaped appearance of the distal phalanx in the affected little finger (similar to that in Fig. 1B). Baran & Juhlin (11) reported that development of the normal nail appears to be dependent on the underlying bone; this dependence may extend to the middle phalanx, and onychia or hyponychia may result when the underlying bone is either hypoplastic or completely absent. In the present case, several bone anomalies, including M- and Y-shaped deformities of the distal phalanges, fusing of the distal interphalangeal joint of the bilateral fourth and fifth toes and latent bifidus of the sacral bone, were associated. In the present case, it has been postulated that the ectopic nails may have resulted from the latent bone anomalies in the distal phalanges of the affected fingers. With regard to pathogenesis, previous authors (1-3, 10) suggested that such anomalies might develop from ectopic germ cells (i.e. hamartoma or teratoma) during embryonic development without a junction between the normal and the ectopic nail matrix, though they could not exclude the possibility of a vestigial nail of occult polydactyly (3). The exact pathogenesis of the ectopic nails in the present case remains unclear.

REFERENCES

- Ohya Z. Polyonychie congenita sine polydactylie. *Acta Dermatol (Kyoto)* 1931; 17: 70-71.
- Kikuchi I, Ono T, Ogata K. Ectopic nail: case reports. *Plast Reconstr Surg* 1978; 61: 781-783.
- Katayama I, Maeda M, Nishioka K. Congenital ectopic nail of the fifth finger. *Br J Dermatol* 1984; 111: 231-233.
- Yamasaki R, Yamasaki M, Kokoroishi T, Jidoi J. Ectopic nail associated with bone deformity. *J Dermatol* 1984; 11: 295-300.
- Aoki K, Suzuki H. The morphology and hardness of the nail in two cases of congenital onychoheterotopia. *Br J Dermatol* 1984; 110: 717-723.
- Higashi N. A case of congenital ectopic nail. *Jpn J Skin Research* 1984; 26: 1043-1045.
- Markinson B, Brenner AR, McGrath M. Congenital ectopic nail. A case study. *J Am Podiatr Med Assoc* 1988; 78: 318-319.
- Aoki K, Hataba Y. A case of congenital onychoheterotopia on both fifth fingers. *Clin Exp Dermatol* 1991; 16: 285-286.
- Kikuchi I, Horikawa S, Amano F. Congenital onychodysplasia of the index fingers. *Arch Dermatol* 1974; 110: 743-746.
- Kikuchi I, Ogata K, Idemori M. Vertically growing ectopic nail. Nature's experiment on nail growth direction. *J Am Acad Dermatol* 1984; 10: 114-116.
- Baran R, Juhlin L. Bone dependent nail formation. *Br J Dermatol* 1986; 114: 371-375.

Accepted January 2, 1996.

Shuichi Kuniyuki

Division of Dermatology, Juso Municipal Hospital, Juso-Higashi 2-3-7, Yodogawa-ku, Osaka, 532, Japan.