

Impaired Expression of Stem Cell Factor in Dermatofibroma Fibroblasts

TOSHIYUKI YAMAMOTO, ICHIRO KATAYAMA and KIYOSHI NISHIOKA

Department of Dermatology, Tokyo Medical and Dental University, School of Medicine, Tokyo, Japan

The number of mast cells is increased in dermatofibroma lesions and plays a role in the induction of fibrosis or its proliferation. We have investigated stem cell factor expression in solitary and multiple dermatofibromas by immunohistochemical staining. We also analyzed messenger RNA (mRNA) expression of stem cell factor in dermatofibroma tissues and cultured fibroblasts derived from dermatofibromas, using reverse transcriptase polymerase chain reaction. We found immunoreactive stem cell factor in keratinocytes, dermal fibroblasts, melanocytes and hair follicles. Unexpectedly, a reduced expression of immunoreactive stem cell factor in dermatofibroma fibroblasts was observed in solitary and multiple type. However, mRNA expression of stem cell factor was detected both in the dermatofibroma tissue and cultured dermatofibroma-derived fibroblasts. We speculate that the altered expression of stem cell factor of tumor cells in dermatofibroma lesions can be associated with the tumor cell proliferation and induction of dermatofibroma. Key words: SCF mRNA; mast cell.

(Accepted November 15, 1995.)

Acta Derm Venereol (Stockh) 1996; 76: 257-259.

T. Yamamoto, Department of Dermatology, Tokyo Medical and Dental University, School of Medicine, 5-45, Yushima 1-chome, Bunkyo-ku, Tokyo, Japan.

Dermatofibroma (DF) has been considered a reactive hyperplasia rather than a true neoplasm, but the issue remains unsettled. DF is a common, benign dermal nodule which usually occurs as a solitary lesion, or occasionally as a few lesions. Several cases have been reported on multiple DFs associated with autoimmune disorders (1, 2). The number of mast cells is increased in DF, especially in the upper portion of the lesion or the layer between the overlying epidermis and the DF lesion (2). Sometimes, DFs rapidly increase in number or fade away in the course of accompanying autoimmune disorders (2). The sera of patients with systemic lupus erythematosus (SLE) with multiple DFs showed much stronger fibroblast growth stimulatory activity than those of patients with SLE without DFs (3). It is suggested that DF is a reactive proliferation and that mast cells may play an important role in the induction and exacerbation of the fibrotic process, especially in cases of multiple DFs associated with autoimmune diseases.

The growth factor for connective tissue type mast cells is a cytokine and is the ligand for the protein product of the c-kit proto-oncogene. It is also known as stem cell factor (SCF), steel factor, and c-kit ligand (4-7). Mast cell growth factor stimulates the growth and differentiation of murine mast cells in vitro (4-8). To investigate the possible role of mast cell growth factor in the proliferation of fibroblasts in DF, we used a monoclonal antibody specific for this factor.

MATERIAL AND METHODS

Mast cell count

Skin biopsy specimens of 6 solitary DFs and 7 multiple DFs in 2 cases were fixed with 10% formalin and stained with toluidin blue at pH 7.0. As we previously reported (2), mast cells were counted under high magnification of 400 power-fields of a light microscope in 10 fields of the layer between the DF lesion and the overlying epidermis.

Immunohistochemical studies

Six solitary DFs and 7 multiple DFs in 2 cases were examined. 5-8 μ m cryostat sections were allowed to air-dry, fixed in acetone at room temperature for 5 min and washed in PBS. Standard avidine-biotin peroxidase technique (Vectastain ABC kit, Vector Laboratories Inc, Burlingame, CA) was then used to detect SCF expression. The primary anti-SCF antibody (R&D Systems, Minneapolis, MN) was applied at a dilution of 1:10. In addition, other antibodies to factor XIII a (diluted 1:200, Calbio Chem Corp, La Jolla, CA), Vimentin (diluted 1:100, Dakopatts A/S, Denmark) and CD34 (diluted 1:50, Immunotech Inc, Marseille, France) were also used for the immunostaining procedures. The sections were developed with 3-amino-9-ethylcarbazole as chromogen. The sections were counterstained with hematoxylin, dehydrated, cleared and mounted. Negative controls were prepared by omission of the specific antibody, and by its substitution with a non-specific IgG subclass mix or an irrelevant isotype-matched monoclonal antibody.

Reverse transcriptase polymerase chain reaction (RT-PCR)

The central portion of 2 solitary DFs and 1 DF of multiple type was each cut into pieces (1 \times 1 mm) and then cultured in Dulbecco's modified Eagle's medium supplemented with 10% fetal calf serum at 37°C in an atmosphere of 5% CO₂-95% air. The medium was changed every 2 days. Total RNA was isolated from fourth- to sixth-passaged cultured fibroblasts or from fifty 5- μ m-thick cryostat sections of 3 solitary DF tissues and 1 DF tissue of multiple type, using RNA zol (Biotex CS 101), and then reversely transcribed to cDNA with RAV-2 reverse transcriptase (RT; Takara 2610B). PCR was performed in a solution containing 20 pmol/l of SCF-specific primer pairs (5'GGGCTGGATCGCAGCGC3' and 5'CTCCACAAGGTCATCC-AC3') (9). We used the following conditions for SCF mRNA preparation: 40 cycles each of denaturation at 95°C for 1 min, annealing at 47°C for 1 min and extension at 72°C for 2 min. PCR products were electrophoresed in 1.7% agarose gel. The gel was stained with 1.7% ethidium bromide and visualized under ultraviolet light.

RESULTS

The mean mast cell number counted in solitary DFs was 55.4 ± 17.6 mm² (mean \pm SD), which was significantly higher than that of normal skin (32.5 ± 8.8) ($p < 0.01$). The mean mast cell number was 120.8 and 46.1 in 2 cases of multiple DFs. Positive staining for factor XIII a and Vimentin was found in the DF fibroblasts in all cases. CD34 was negatively stained in all cases. We found a negative staining of tumor cells for SCF antigen in all 13 cases of DF, both in solitary and multiple type (results are summarized in Table I). SCF-positive cells were absent in the lesions of DF, while a large

Table I. Immunostaining findings of stem cell factor in solitary and multiple dermatofibromas

All of the dermatofibroma cases showed negative findings of immunoreactive stem cell factor.

	Case	Overlying Epidermis	DF Lesion	Overlying Dermis	Dermis
Solitary DF	1	-	-	+	+
	2	+	-	+	+
	3	-	-	+	+
	4	+	-	+	+
	5	+	-	+	+
	6	-	-	+	+
Multiple DF	7	-	-	+	+
	7	+	-	+	+
	7	+	-	+	+
	8	-	-	+	+
	8	-	-	+	+
	8	-	-	+	+
Normal Skin	9	-	-	+	+
	10	-	-	+	+

- : negative
+ : positive

number of positive cells were observed throughout the dermis except for the DF lesions (Fig. 1). SCF was relatively strongly expressed in the overlying dermis. Normal skin dermis was positively stained in a diffuse pattern (data not shown). Positive staining of SCF for the hair follicle cells and basal melanocytes in the overlying epidermis was observed. Keratinocytes in the overlying epidermis of DF lesions showed an intercellular pattern of positive SCF expression (Fig. 2). SCF mRNA expression was strongly detected both in solitary and multiple DF-derived culture cells by RT-PCR analysis (Fig. 3). SCF mRNA expression was also detected in the cryosections of solitary and multiple DFs (data not shown).

DISCUSSION

Our immunohistochemical studies indicated selective disappearance of SCF-positive tumor cells in the DF lesion. Immunoreactive SCF was present in the dermis other than the DF lesion in a diffuse pattern and was relatively strongly expressed in the layer between the DF lesion and the overlying epidermis, in which mast cells were increased. Dense immunoperoxidase staining of SCF was found in hair follicles and basal melanocytes. Keratinocytes were also focally found




Fig. 1. Stem cell factor is negatively expressed in a dermatofibroma lesion (arrow).

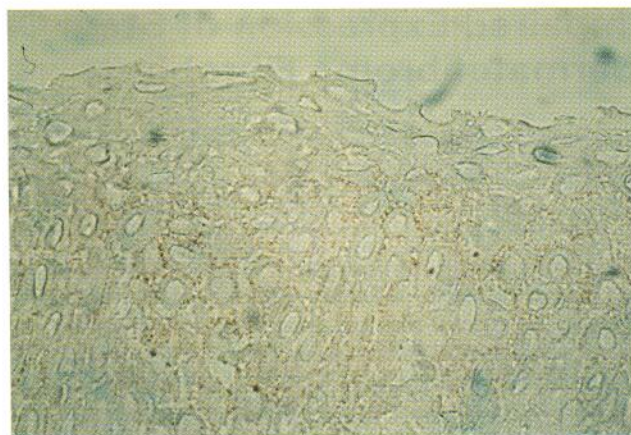


Fig. 2. Keratinocytes in the overlying epidermis of a dermatofibroma lesion show an intercellular pattern of stem cell factor expression.

Human Stem Cell Factor

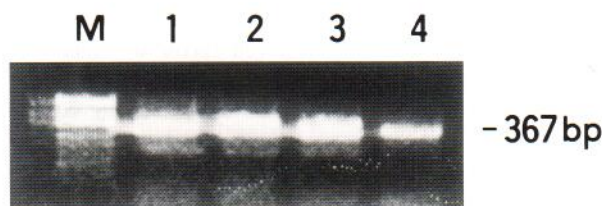


Fig. 3. Electrophoretic analysis of stem cell factor gene expression by RT-PCR in dermatofibroma-derived cell cultures. M indicates marker, lanes 1-2, solitary dermatofibroma-derived cells, lane 3, multiple dermatofibroma-derived cells, lane 4, normal skin-derived cells.

positive in the overlying epidermis of DF lesions, which may be due to the soluble form of SCF.

SCF is produced by keratinocytes, fibroblasts and endothelial cells in human skin (10, 11). It has also been reported that cultured normal human keratinocytes and fibroblasts express SCF mRNA (12). In this study, although positive immunostaining for SCF was not found in the tumor cells of DF, we were able to detect SCF gene expression in the DF-derived cultured cells and cryosections examined by RT-PCR analysis, which indicated that extremely low levels of SCF were expressed in the tumor cells of DF. The reason for the discrepancy of the expression of SCF between the protein and mRNA level using PCR is unknown. Some speculations could be considered: first, the strong expression of SCF mRNA because of inhibition of protein synthesis; second, that transcripts of the SCF gene are made without further process; third, that immunoreactive SCF protein is easily destroyed; and fourth, that cultured fibroblasts change their behavior or the isolated RNA detected in the DF specimens derived from positive hair follicles, keratinocytes or fibroblasts around the DF lesion. In cutaneous mastocytosis, altered cutaneous metabolism of SCF is believed to cause the abnormal proliferation of mast cells (9). The increased basal pigment in the overlying epidermis of DF lesions may be caused by SCF, which also stimulates the production of melanin by melanocytes (9). SCF accumulated between keratinocytes in the lesional skin might explain the basal pigment or underlying mast cell proliferation. On the other hand, keratinocyte-derived basic fibroblast

growth factor is reported to be a mitogen for melanocytes in addition to fibroblasts (13), so this growth factor may also be associated with basal pigment and acanthosis of the overlying epidermis in DF. It is speculated that altered expression of SCF of tumor cells in DF lesions might be associated with the tumor cell proliferation and induction of DF. Further studies are necessary to support the hypothesis that the increased number of mast cells represents a hyperplastic response of fibroblasts rather than a true neoplastic process in DF.

REFERENCES

1. Newman DM, Walter JB. Multiple dermatofibromas in patients with systemic lupus erythematosus on immunosuppressive therapy. *N Engl J Med* 1973; 289: 842-843.
2. Yamamoto T, Katayama I, Nishioka K. Mast cell number in multiple dermatofibromas. *Dermatology* 1995; 190: 9-13.
3. Yamamoto T, Katayama I, Nishioka K. Involvement of basic fibroblast growth factor in fibroblast stimulatory activity of SLE sera with multiple dermatofibromas. *Dermatology* 1995; 191: 281-285.
4. Williams DE, Eisenman J, Baird A, Rauch C, Ness KV, March CJ, et al. Identification of a ligand for the c-kit proto-oncogene. *Cell* 1990; 63: 167-174.
5. Copeland NG, Gilbert D, Cho B, Donovan P, Jenkins N, Cosman D, et al. Mast cell growth factor maps near the steel locus on mouse chromosome 10 and is deleted in a number of steel alleles. *Cell* 1990; 63: 175-183.
6. Anderson DM, Lyman SD, Baird A, Wignall JM, Eisenman J, Rauch C, et al. Molecular cloning of mast cell growth factor, a hematopoietin that is active in both membrane bound and soluble forms. *Cell* 1990; 63: 235-243.
7. Flanagan JG, Leder P. The kit ligand: a cell surface molecule altered in steel mutant fibroblasts. *Cell* 1990; 63: 185-194.
8. Onoue H, Ebi Y, Nakayama H, Ru XM, Kitamura Y, Fujita J. Suppressive effect of S1/S1 mouse embryo-derived fibroblast cell lines on diffusible factor-dependent proliferation of mast cells. *Blood* 1989; 74: 1557-1562.
9. Longley BJ, Morganroth GS, Tyrrell L, Ding TG, Anderson DM, Williams DE, et al. Altered metabolism of mast-cell growth factor (c-kit ligand) in cutaneous mastocytosis. *N Engl J Med* 1993; 328: 1302-1307.
10. Grabbe J, Welker P, Dippel E, Czarnetzki BM. Stem cell factor, a novel cutaneous growth factor for mast cells and melanocytes. *Arch Dermatol Res* 1994; 287: 78-84.
11. Weiss RR, Whitaker-Menezes D, Longley J, Bender J, Murphy GF. Human dermal endothelial cells express membrane-associated mast cell growth factor. *J Invest Dermatol* 1995; 104: 101-106.
12. Morita E, Lee DG, Sugiyama M, Yamamoto S. Expression of c-kit ligand in human keratinocytes. *Arch Dermatol Res* 1994; 286: 273-277.
13. Halaban R, Langdon R, Birchall N, Cuono C, Baird A, Scott G, et al. Basic fibroblast growth factor from human keratinocytes is a natural mitogen for melanocytes. *J Cell Biol* 1988; 107: 1611-1619.