

# Multiple Symmetrical Lipomatosis in a Patient on Long-term Corticosteroid Therapy

Sir,

Multiple symmetrical lipomatosis (MSL) is an uncommon disorder of unknown aetiology, characterised by large non-encapsulated lipomas distributed around the neck, shoulders and other axial regions (1).

## CASE REPORT

A 56-year-old male presented with a 20-year history of diffuse lipomatous growths around the shoulders, arms, upper trunk and thighs. The fatty accumulations had been rapidly progressive for the first 4 years and gradually increased over the next 16 years. There was no family history of a similar disease. The patient was a non-alcoholic and had no known diabetes. In addition, the patient had been suffering from chronic actinic dermatitis for the last 30 years and had received oral corticosteroids in doses up to 40 mg of prednisolone equivalent daily.

The patient was normotensive. Cutaneous examination revealed diffuse, non-tender, lipomatous growths restricted to the shoulders, upper chest, arms, trunk and thighs (Figs. 1, 2). The face and distal part of extremities were conspicuously spared. Side-effects of corticosteroid therapy in the form of skin atrophy with striae were present on the lower trunk and calf area. The patient, however, did not have "moon-faces" or "buffalo-hump". There was no clinical evidence of superior venacaval obstruction, respiratory complaints or peripheral neuropathy.

Erythematous scaly papules and plaques were present on the face and extensors of the forearms when the patient was first seen in the outpatient department. These subsided within 2 weeks of hospitalisation with photoprotection and topical application of betamethasone valerate (0.1%) ointment. Oral corticosteroids were gradually tapered and stopped over a period of 4 weeks.

On examination, the patient was found to be suffering from diabetes mellitus. Skin biopsy from one of the growths revealed a non-

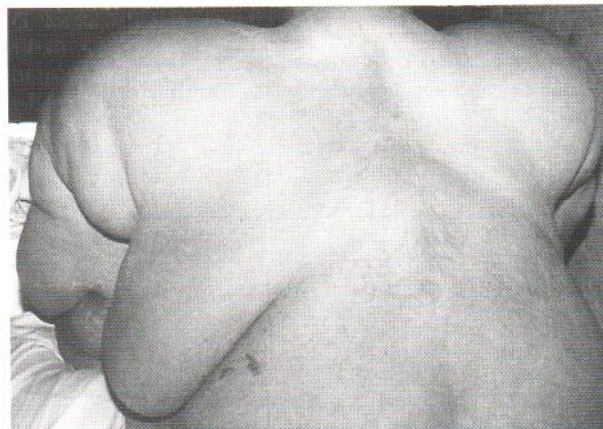

Fig. 2. Lipomatous deposits on the trunk.

encapsulated lipoma. Electrophysiological study of the nerves was suggestive of sensorimotor neuropathy involving both upper and lower limbs. Routine haemogram, liver and kidney function tests were within normal limits and so were his serum cortisol and uric acid levels. A skiagram of the chest and ultrasonographic study of the abdomen revealed no abnormality.

## DISCUSSION

Two patterns of distribution of lipomas have been described in MSL (2). In the type I variant lipomatous deposits are found primarily in the nape of the neck, supraclavicular and deltoid region, while in the type II variant lipomas are not localised to the neck but extend down over the trunk and proximal part of extremities, whereas the lower part of the trunk and lower extremities are conspicuously spared (2). Mediastinal extension of lipomas with obstructive symptoms due to pressure on trachea and superior venacava have been described in the type I pattern (3). The disorder is frequently associated with alcoholic habit, peripheral neuropathy and deranged liver functions (1). Rarely association with gout, hypertension, obesity, diabetes and various neurological symptoms has been reported (4, 5). Certain metabolic abnormalities in the form of hyperuricemia, hypertriglyceridemia and hyperinsulinism may be found (2, 4). However, there is little convincing evidence that these associations are other than due to chance.

Our patient had a clinical presentation consistent with type II MSL. On examination, the patient was found to have diabetes mellitus and peripheral neuropathy, commonly associated with MSL. However, alcoholic habit frequently reported




Fig. 1. Patient having lipomatous deposits involving shoulders, arms and trunk.

in this disorder was not present in our patient. Serum cholesterol and uric acid levels were normal.

Our patient also had steroid-induced striae and atrophy of the skin. However, this was unrelated to the characteristic presentation of MSL, where the lipomatous growths were confined to the shoulders, upper part of trunk and the proximal extremities. There was conspicuous sparing of the face, involvement of which is universally seen in patients with Cushing's syndrome. The association of chronic actinic dermatitis and MSL in our patient is probably inconsequential, like many other associations reported in the literature.

## REFERENCES

1. Matamale-Gimeno C, Perez-Calvo JI, Amores-Ferreras M. Multiple symmetrical lipomatosis. *Ann Med Interna (Panz)* 1994; 11: 95-99.
2. Foster DW. The lipodystrophies and other rare disorders of adipose tissue. In: Isselbacher KJ, Braunwald E, Wilson J, Martin JB, et al., eds. *Harrison's Principles of internal medicine*. 13th edn. New York: McGraw Hill, 1994: 2134-2135.
3. Uhlin SR. Benign symmetric lipomatosis. *Arch Dermatol* 1979; 115: 94-95.
4. Greene ML, Glueck CJ, Fuymoto MY, Seegmiller JE. Benign symmetric lipomatosis (Launois-Bensaude adenolipomatosis) with gout and hyperlipoproteinemia. *Am J Med* 1970; 48: 239-245.
5. Carlin MC, Ratz JL. Multiple symmetrical lipomatosis: treatment with liposuction. *J Am Acad Dermatol* 1988; 18: 359-362.

*Accepted December 4, 1995.*

Neena Khanna MD., Devraj Dogra MD, Sanjay K Rathi MBBS and J. S. Ravindradas MBBS  
Department of Dermatology & Venereology, All India Institute of Medical Sciences, New Delhi, India.