

## Acute Multifocal Skin Necrosis: Synergism between Invasive Streptococcal Infection and Cocaine-induced Tissue Ischaemia?

PETER H. HOEGER, GUDRUN HAUPT and EBERHARD HOELZLE

Department of Dermatology, University of Hamburg, Hamburg, Germany

**A 30-year-old pregnant woman with full thickness skin necrosis following parenteral abuse of cocaine and heroine is described. Three lesions occurred simultaneously on the trunk and right knee subsequent to an abscess on the left thigh from which *S. pyogenes* group A and *S. aureus* were isolated. Histology revealed necrotic subcutaneous tissue with obliterated vessels and a mixed inflammatory infiltrate. The sequence of events suggests a synergism between the effects of bacterial proteases and cocaine-induced impairment of soft tissue perfusion. In the present case, this synergism may have been further enhanced by decreased cocaine tolerance during pregnancy. Key words: *S. pyogenes* group A; *S. aureus***

(Accepted December 11, 1995.)

Acta Derm Venereol (Stockh) 1996; 76: 239–241.

P. H. Hoeger, Department of Dermatology, University of Hamburg, Martinistr. 52, D-20246 Hamburg, Germany.

Intravenous drug abuse is associated with a variety of complications, including soft tissue and systemic infections, vascular lesions, and the imminent risk of lethal overdosing. Cocaine in particular has been associated with side-effects related to its ability to induce persistent vasoconstriction, favouring endothelial injury and local ischaemia. Cutaneous effects of cocaine include ulcerations at the site of i.v. drug injections (1), the development of connective tissue disease and Raynaud phenomenon (2), and bullous skin disease (3). The risk of necrotizing fasciitis (4) and necrotizing angitis (5, 6) is increased many-fold among cocaine abusers.

We report an unusual case of large multifocal skin necrosis in a woman who abused cocaine and heroine during pregnancy. We hypothesize that in predisposed hosts, skin necrosis might result from the synergistic action of microbial pathogens and cocaine-induced impairment of soft tissue perfusion.

### CASE REPORT

A 30-year-old woman was referred to the Department of Dermatology for evaluation and treatment of extensive skin necrosis. The patient had been well until 2 weeks before, when she observed a painful swelling on her left thigh. Two to 3 days later she noted tender erythematous patches on her right breast, left hip and medial aspect of her right knee, which turned into blisters filled with clear fluid during the following day. She did not seek medical attention until 2 days later, when the pain in her left thigh increased. In the emergency room an abscess on the proximal left thigh was diagnosed. On incision, several ml of yellowish pus were drained. Bacteriological culture grew *S. pyogenes* group A and *S. aureus*. Being in the 38th week of her first pregnancy, she was referred to the maternity clinic. On admission, the patient was afebrile, normotensive (125/85 mm Hg) and slightly tachycardic (110 BPM). Laboratory investigations revealed a leukocytosis of 23,300/ $\mu$ l and an elevation of the C-reactive protein (296 mg/l). Cardiocotographic signs of fetal distress mandated emergency Caesarean section. A mature and slightly dystrophic boy

(2,600 g/47 cm) was delivered (APGAR score 4/7/9) and transferred to the pediatric department for further evaluation.

On further questioning, the patient conceded intravenous abuse of heroine and cocaine during the past 4 weeks of her pregnancy. She had been abusing these substances previously for about 8 years and was substituted with L-methadone (35 mg/d p.o.) during pregnancy. Heroine and cocaine had been injected into the left femoral vein. According to the patient's own estimate, total daily consumption of heroine averaged 0.8 g/d (in 5–6 single shots). Cocaine was injected every other day (4 injections per day, total consumption: about 0.5 g/d). She was smoking about 20 cigarettes per day.

During the following days, the erythematobullous areas on her right breast, left hip and right knee started to demarcate. The patient was treated with amoxicillin plus clavulanic acid (3  $\times$  1 g of amoxicillin per day i.v.) and penicillin G (3  $\times$  10<sup>6</sup> units per day i.v.); since the skin lesions were initially attributed to a presumptive acute HSV infection, she also received acyclovir (3  $\times$  500 mg per day i.v. for 4 days).

She was transferred to the Department of Dermatology on the 9th postoperative day, where on admission, necrotic skin areas were noted on her right breast (18  $\times$  11 cm, Fig. 1A), left flank (23  $\times$  17 cm) and the medial aspect of her right knee (8  $\times$  4.5 cm), each surrounded by a 1.0–1.5 cm erythematous margin and a livedo reticularis-like skin discoloration. There was a suppurative ulcer in her left groin (2  $\times$  1.5 cm) and an indurated area (20  $\times$  10 cm) with a recent incision wound on her left proximal thigh. The remainder of the physical findings was unremarkable.

Echocardiography revealed no signs of active endocarditis, and funduscopy as well as a cranial CAT scan gave normal results.

Laboratory evaluation showed a mild leukocytosis of 11,570/ $\mu$ l with 67% neutrophils. ESR (120 mm/h) and CRP (46 mg/l) were still elevated, while bilirubin, serum-amylase, lactate dehydrogenase, ASAT, ALAT, uric acid, kreatinin,  $\alpha_1$ -proteinase-inhibitor (3.6 g/l), and coagulation parameters including protein C (117% of normal), protein S (76%) and antithrombin III (101%) were within the normal range. Assays for anti-DNA-antibodies and cardiolipin antibodies were negative. Urine analysis on admission was positive for cocaine, heroine, L-methadone, and metabolites of these drugs.

Toxicologic analysis of a hair sample gave the following results (per g hair): benzoylecgonine 6.8  $\mu$ g, cocaine 2.9  $\mu$ g, morphine 2.5  $\mu$ g, codeine 1.97  $\mu$ g, monoacetylmorphine 6.7  $\mu$ g.

Histology was performed on the necrotic plaques, which were removed 10 days after admission. The small vessels of the largely necrotic subcutaneous tissue were obliterated and necrotic themselves. A mixed inflammatory infiltrate was noted around the subcutaneous septae.

Bacteriology. Bacteriological cultures taken from blood, breast wound and from pus removed from the left thigh abscess on admission, i.e. 8 days after antibiotic treatment was begun at the referring hospital, remained sterile. *Ps. aeruginosa* (sensitive to ciprofloxacin) was grown from hip and knee wound but not from breast wound swabs. Antistreptolysin (1,310 units) and anti-streptococcal DNase (6390 U/ml) were strikingly elevated. The antistaphylolysin level was within the normal range (0.7 IE). The patient was seropositive for anti-HB<sub>s</sub>-IgG and anti-HSV-IgG, but seronegative for the human immunodeficiency virus and hepatitis C.

Therapy and clinical course. The patient received a 21-day course of amoxicillin plus clavulanic acid (3  $\times$  1 g per day i.v.) and ciprofloxacin



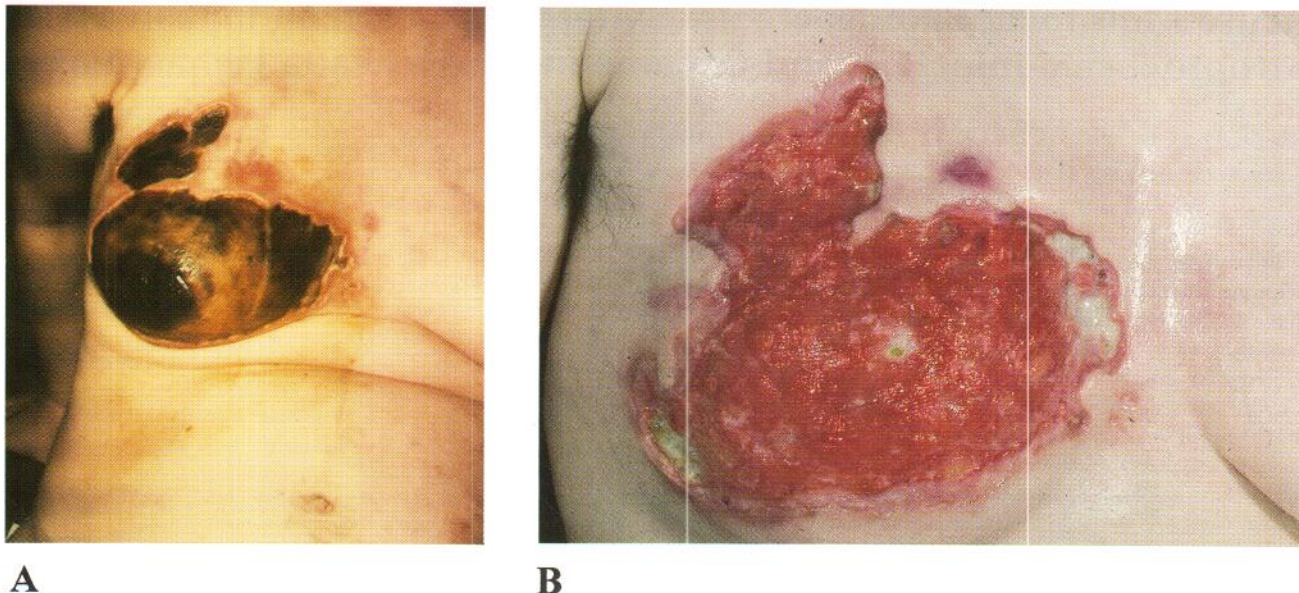


Fig. 1. Demarcated necrotic skin areas on the right breast, (A) on admission:  $18 \times 11 \text{ cm}^2$  area of necrotic demarcation, (B) after 3 weeks of systemic antibiotic therapy, topical débridement and cleansing: formation of unaffected granulation tissue on the ground of the ulcer.

( $2 \times 250 \text{ mg}$  per day i.v.), both applied through a left subclavian vein catheter, in order to cover all microorganisms isolated during the course of the disease (*S. pyogenes* group A, *S. aureus*, *Ps. aeruginosa*). Substitution with L-methadone ( $45 \text{ mg/d}$  p.o.) was continued. Topical treatment consisted of débridement, extensive wound cleansing with  $\text{H}_2\text{O}_2$ , and polyvidone iodine dressings. Removal of the necrotic plaques revealed full-thickness necrosis of the skin, reaching down to the adipose tissue layer. Granulation tissue was present on the ground of the ulcers (Fig. 1B). A second incision of the thigh abscess was sterile.

On follow-up 4 weeks after admission, the antistreptolysin titer was 775 units, anti-streptococcal DNase B was 1,850 units/ml, the ESR was  $50 \text{ mm/h}$  and the CRP was  $25 \text{ mg/l}$ . Wound healing continued uneventfully. Reconstructive surgery of the right breast was scheduled for 3 months later.

## DISCUSSION

Skin necrosis is not a diagnostic entity but the common final pathway of a variety of disorders leading to local ischemia (7). These include primary vascular events (e.g. vasospasm, vasculitis, embolization), coagulation disorders, chemical or physical injury, and infections. Parenteral drug abuse is associated with an increased risk and a peculiar pattern of systemic infections. These are mostly due to the inoculation of skin contaminants such as streptococci or staphylococci, and thus many infections are polymicrobial.

The case reported here is noteworthy for the extent and rapid development of full thickness necrotic skin ulceration occurring simultaneously in three different body areas. Although the clinical presentation was reminiscent of that in coumarin-induced skin necrosis (8), a thorough examination of the coagulation system revealed no abnormality; deficiency of protein C, protein S (9) or antithrombin III (10) were ruled out. Lupus anticoagulant antibodies (11) were not detected, and there were no signs of disseminated intravascular coagulation (12) or pancreatitis (10). Moreover, the sites of the skin lesions had not been used for injection of parenteral drugs, and the simultaneous appearance of cutaneous lesions at

different sites argues against extravasation of intravenously infused agents (13) or accidental intraarterial injection. *Ps. aeruginosa*, which was grown from some but not all of the skin lesions, and only after antibiotic therapy, can probably be considered a secondary contaminant in this case. The skin changes did not resemble the punch-out lesions typical of ecthyma gangrenosum or pyoderma gangrenosum (14, 15). They were considerably larger and did not show the acral predilection of bacterial emboli (14, 15).

The sequence of events, i.e. the appearance of skin lesions on the trunk and right knee subsequent to the development of a large abscess on the left thigh, is suggestive of a septic process resulting in soft tissue infarction. *S. pyogenes* group A and *S. aureus* were isolated from the thigh abscess adjacent to the site of i.v. drug injections, and laboratory investigations gave evidence of a systemic streptococcal infection responsive to antibiotic therapy. Owing to their capacity to produce proteases, *S. pyogenes* group A as well as staphylococci have been associated with skin necrosis (7, 16). Unlike streptococcal gangrene (necrotizing fasciitis), necrosis did not extend beyond the fat layer (4, 17), and signs of systemic toxicity were absent in our case. The clinical presentation of necrotizing streptococcal infections is variable, and indolent courses of invasive cutaneous streptococcal infections with minimal fever have been described before (14).

Manifestation and clinical course of infections in drug addicts are influenced by pharmacologic properties of the injected drug; cocaine in particular has been associated with a significantly increased risk of endocarditis (18) and of necrotizing fasciitis (4). The capacity of cocaine to constrict blood vessels predisposes to ischemia and necrotizing soft tissue infections (4, 17). Cocaine blocks the presynaptic re-uptake of the neurotransmitters norepinephrine and dopamine, inducing an excess of catecholamines at the postsynaptic receptor sites (19, 20). The result is a striking adrenergic activation characterized by vasoconstriction, tachycardia and an acute rise in arterial pressure. Vasoconstriction can induce endothel-



ial injury and lead to the formation of thrombi (19). After long-term use, unmetabolized cocaine is sequestered in peripheral tissue; it can be detected up to 10 days after intake (21). Cocaine abuse has been associated with intracranial hemorrhage, aortic dissection, local ischemia or infarction (19, 22, 23), as well as necrotizing angitis (5, 6).

In our patient, the development of necrotizing soft tissue infections was probably facilitated by the vasoconstrictive action of cocaine. On admission, tachycardia and the livedo-like figurated erythema surrounding the necrotic areas were additional features suggestive of the adrenergic action of cocaine. Several factors may have contributed to increased cocaine toxicity in this case: cocaine was used intravenously and at high doses (approx. 0.5 g of cocaine per day); the purity of cocaine purchased illegally is unpredictable and may vary from 25 to 90% (20). It is usually inhaled and consumed at doses around 1–3 g per week. Secondly, the patient had only recently resumed cocaine abuse after a period of several months of abstinence. Thirdly, cocaine is usually detoxified by plasma and liver cholinesterases to water-soluble metabolites such as benzoylecgonine and ecgonine methylester that are excreted in the urine (20). Plasma cholinesterase activity is much lower in pregnant women, fetuses and patients with liver disease (19, 24, 25). Cocaine use during pregnancy has been associated with an increased risk of myocardial and vascular toxicity. Finally, concomitant cigarette smoking exacerbates the toxic effects of cocaine, e.g. on myocardial oxygen supply (26), and may have further contributed to ischaemic vascular damage in our patient.

## REFERENCES

- Garcia Castano J, Martin MI, Muino A, Gonzalez Ramallo V. Lesiones dérmicas por cocaína. *Anales Med Intern (Madrid)* 1992; 9: 49–50.
- Trozak DJ, Gould WM. Cocaine abuse and connective tissue disease. *J Am Acad Dermatol* 1984; 10: 525.
- Tomecki KJ, Wiekas SM. Cocaine-related bullous disease. *J Am Acad Dermatol* 1985; 12: 585–586.
- Jacobson JM, Hirschman SZ. Necrotizing fasciitis complicating intravenous drug abuse. *Arch Intern Med* 1982; 142: 634–635.
- Citron BP, Halpern M, McCarron M, Lundberg GD, McCormick R, et al. Necrotizing angitis associated with drug abuse. *N Engl J Med* 1970; 283: 1003–1011.
- Kaye BR, Fainstat M. Cerebral vasculitis associated with cocaine abuse. *JAMA* 1987; 258: 2104–2106.
- Quintal D, Jackson R. Necrosis of the skin. In: Moschella SL, Hurley HJ, eds. *Dermatology*. 3rd edn, Vol. 2. Philadelphia: WB Saunders, 1992: 1206–1214.
- Bauer KA. Coumarin-induced skin necrosis. *Arch Dermatol* 1993; 129: 766–768.
- Stephens CJM, Jurd KM, Smith NP, Jenkins RE, Black MM, Hunt BJ. Cutaneous necrosis. A dramatic presentation of a thrombotic state. *Br J Dermatol* 1993; 129 (Supp. 42): 30–31.
- Su WPD. Diseases of the subcutaneous tissue. In: Moschella SL, Hurley HJ, eds. *Dermatology*. 3rd edn, Vol. 2. Philadelphia: WB Saunders, 1992: 1312–1332.
- Francès C, Tribout B, Boisnic S, Drouet L, Piette JC, Blétry O, et al. Cutaneous necrosis associated with the lupus anticoagulant. *Dermatologica* 1989; 178: 194–201.
- Colman RW, Minna JD, Robboy SJ. Disseminated intravascular coagulation: a dermatologic disease. *Int J Dermatol* 1977; 16: 47–51.
- Dufresne RG. Skin necrosis from intravenously infused materials. *Cutis* 1987; 39: 197–198.
- Swartz MN. Cellulitis and superficial infections. In: Mandell GL, Douglas RG, Bennett JE, eds. *Principles and practice of infectious diseases*. 3rd edn. New York: Churchill Livingstone, 1990: 796–807.
- Kingston ME, Mackey D. Skin clues in the diagnosis of life-threatening infections. *Rev Infect Dis* 1986; 8: 1–11.
- Talkington DF, Schwartz B, Black CM, Todd JK, Elliott J, Breiman RF, et al. Association of phenotypic and genotypic characteristics of invasive *Streptococcus pyogenes* isolates with clinical components of streptococcal toxic shock syndrome. *Infect Immun* 1993; 61: 3369–3374.
- Dobkin JF. Infections in parenteral drug abusers. In: Mandell GL, Douglas RG, Bennett JE, eds. *Principles and practice of infectious diseases*. 3rd edn. New York: Churchill Livingstone, 1990: 2276–2280.
- Chambers HF, Morris DL, Täuber MG, Modin G. Cocaine use and risk for endocarditis in intravenous drug users. *Ann Intern Med* 1987; 106: 833–836.
- Jaffe JH. Drug addiction and drug abuse. In: Goodman Gilman A, Rall TW, Nies AS, Taylor P, eds. *The pharmacological basis of therapeutics*. 8th edn. New York: Pergamon, 1990: 522–573.
- Cregler LJ, Mark H. Medical complications of cocaine abuse. *N Engl J Med* 1986; 315: 1495–1500.
- Cone EJ, Weddington WW Jr. Prolonged occurrence of cocaine in human saliva and urine after chronic use. *J Anal Toxicol* 1989; 13: 65–68.
- Isner JM, Estes NAM, Thompson PD, Costanzo-Nardin MR, Subramanian R, Miller G, et al. Acute cardiac events temporally related to cocaine abuse. *N Engl J Med* 1986; 315: 1438–1443.
- Webster WS, Brown-Woodman PDC. Cocaine as a cause of congenital malformations of vascular origin: experimental evidence in the rat. *Teratology* 1990; 41: 689–697.
- Stewart DJ, Inaba T, Lucassen M, Kalow W. Cocaine metabolism: cocaine and norcocaine hydrolysis by liver and serum esterases. *Clin Pharmacol Ther* 1979; 25: 464–468.
- Slutsker L. Risks associated with cocaine use during pregnancy. *Obstet Gynecol* 1992; 79: 778–789.
- Moliterno DJ, Willard JE, Lange RA, Negus BH, Boehrer JD, Glamann DB, et al. Coronary-artery vasoconstriction induced by cocaine, cigarette smoking, or both. *N Engl J Med* 1994; 330: 454–459.