

## Expression of the p53 Protein in Sun-damaged Skin

MARÍA A. BARNADAS<sup>1</sup>, LLUIS COLOMO<sup>2</sup>, ROMÁN CURELL<sup>2</sup> and JOSÉ M. DE MORAGAS<sup>1</sup>

Departments of <sup>1</sup>Dermatology and <sup>2</sup>Pathology, St. Cross and St. Paul Hospital, Barcelona, Spain

The expression of the p53 protein in photodamaged skin from the face, forearm and neck of 18 subjects was compared to non-exposed skin taken at autopsy from the abdomens of 9 subjects of the same age. Paraffin sections and the polyclonal antibody CMI were used with the ABC technique.

The p53 protein was expressed in the nuclei of keratinocytes in 7 of the 18 samples obtained from sun-exposed skin and in 1 of 9 samples from non-exposed skin. The expression in sun-exposed skin can be due either to its overexpression due to DNA damage or to the appearance of mutant forms. **Key words:** photoaging; mutation.

(Accepted October 24, 1995.)

Acta Derm Venereol (Stockh) 1996; 76: 203–204.

J.M<sup>a</sup> de Moragas, Department of Dermatology, Hospital de la Sta. Creu i St. Pau, C/ St. Antoni M<sup>a</sup> Claret, 167, E-08025 Barcelona, Spain.

Recent studies suggest that the protein p53 has the capacity to regulate cell cycle progression following exposure to DNA-damaging agents. If repair fails to take place, p53 may trigger cell suicide by apoptosis (1). When p53 protein in tumour cells is inactivated by mutation, or by binding to host or viral proteins, it cannot carry out this arrest. As a result these tumour cells are genetically less stable, and mutations and chromosomal rearrangements will accumulate at an increased rate, leading to the rapid selection of malignant clones (2).

In the last few years, immunohistochemical studies have shown the expression of the p53 protein in several cutaneous dermatoses and tumours (3). p53 mutation has also been demonstrated in tumours and precursor lesions (4).

We have here investigated the expression of p53 protein in sun-damaged skin and compared it with that in non-exposed skin.

### MATERIALS AND METHODS

We studied chronically sun-exposed skin from face, forearm and neck obtained from 18 patients, 7 males and 11 females, aged between 38 and 89 years (mean 72 years). The biopsy samples were obtained from the Department of Pathology and selected from patients that had suffered either a reexcision of a tumour or a biopsy from a lesion suspected of being a cutaneous cancer and where the histopathology only showed actinic elastosis. We divided the skin samples into two groups: (A) punch biopsies of 4 mm or less in diameter ( $n=11$ ) (from our records one patient had suffered from basal cell carcinoma and another from actinic keratosis), and (B) wedge biopsies of more than 4 mm in diameter ( $n=7$ ) (from our records 2 patients had suffered from malignant melanoma, one from a squamous cell carcinoma and one from an actinic keratosis). There were no differences in sex or age in either group.

As a control we studied non-chronically sun-exposed skin taken at autopsy from the abdomens of 9 subjects (4 males and 5 females, aged between 66 and 79 years with a mean age of 71.5). All the samples were between 5 and 20 mm in diameter.

The study was performed on paraffin sections using the polyclonal antibody CMI (Bio-Genex). Each specimen was deparaffined in xylol

and ethanol at different gradients. Later they were rinsed in phosphate-buffered saline (PBS) for 15 min. Afterwards, the sections were incubated with 1.2% normal horse serum for 20 min. Without rinsing, sections were incubated with the polyclonal antibody anti-CMI (Bio-Genex) for 45 min and then rinsed with PBS. The sections were then incubated with biotinylated anti-rabbit IgG, diluted in 1% normal horse serum for 30 min and, rinsed and incubated with 6% H<sub>2</sub>O<sub>2</sub> in PBS for 15 min. Then they were incubated with the avidin-biotinylated horseradish peroxidase complexes using the Vectastain ABC Kit (Vector laboratories, Burlingame, CA), diaminobenzidine and Harris hematoxylin.

### RESULTS

In group A, where the punch biopsies obtained from chronically sun-exposed skin were less than 4 mm in diameter, we detected the presence of cells that had stained nuclei in 2 out of the 11 cases studied. In both cases groups of positive nuclei were observed in the basal layer, and lower-median spinous layers. In group B, where the biopsies were larger, the expression of the protein in the nuclei of keratinocytes was seen in 5 out of the 7 samples studied. In 2 cases, p53-positive nuclei were observed as isolated cells in the basal cell layer or in the spinous layer. In the other 3 cases, positive cells were observed in groups both in the basal layer and at all levels of the spinous layer (Fig. 1). In one of these cases the staining of nuclei was throughout a small segment of the epidermis. In all cases the cells were not uniformly distributed in the epidermis but in a random fashion.

Because of the focal distribution of the positive nuclei we did not consider it beneficial to perform a quantitative study of the positive cells with respect to the negative nuclei of the keratinocytes.

We could only detect positive nuclei in isolated cells in the spinous layer in one out of the 9 skin samples of the abdominal wall skin obtained from the autopsies.

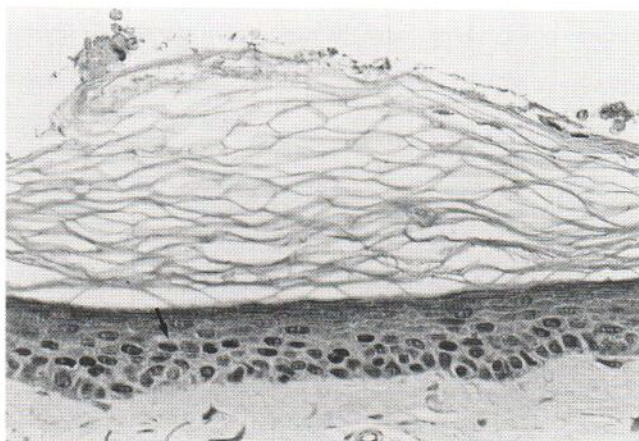


Fig. 1. Expression of the p53 protein in the nuclei of keratinocytes of the basal cell layer and spinous layer from sun-exposed skin (arrow) ( $\times 400$ ).

## DISCUSSION

The higher expression of p53 in the wedge biopsies compared to the punch biopsies, indicates that the probability of finding p53-positive cells increases with the size of the samples and could be due to the focal distribution of the p53 expression. Another explanation is that the sun damage in the group of patients in which a wedge excision was performed might have been higher than in the group of patients in which a punch biopsy was obtained, since more malignancies were detected in the wedge biopsy group.

The fact that the CMI antibody detects both the wild and the mutant forms of this protein does not allow us to distinguish between the two forms in our patients. At present, several antibodies have been raised against the p53 protein. Some of them are polyclonal and others monoclonal. In the early immunohistochemical studies performed on cutaneous and non-cutaneous tumours, the authors suggested that when the p53 protein was expressed it was due to the expression of the mutant form, given that the half-life of the wild form was very short and that of the mutant form longer. In the excellent review of McNutt et al. (3) the authors indicate that this is not always true. It has been suggested that the wild form can be detected by means of immunohistochemical studies (4).

Recently it has been demonstrated that in normal skin, exposure to UV irradiation can trigger a transient expression of the p53 protein in epidermal keratinocytes (5), which can be present in all layers of the spinous layer after irradiation with UVB (6). These findings have been considered to be a reactive phenomenon to the DNA damage by UV light, as no mutation has been observed using an immunohistochemical technique (5).

The mechanism of increased p53 expression after UV irradiation has been shown to be, at least in part, due to post-translational stabilization in a study performed by Maltzmann et al. in 1984 after irradiation of mouse cell cultures with UVC (7).

Healey et al. have also demonstrated an increase in the expression of the p53 protein in the nuclei of keratinocytes after UVB irradiation (8). This expression was dissociated from the UVB-induced erythema. It was not possible to detect an increase in the p53 mRNA, indicating that the induction of the p53 protein in human skin after UV occurs predominantly at a post-transcriptional stage. On the other hand the authors observed that after the exposure of the skin to several

irritants, such as dithranol, retinoic acid and sodium dodecylsulphate, there was an increase in the p53 expression that was accompanied by an increase in the p53 mRNA. These differences indicate that different mechanisms operate in the *in vivo* upregulation of the p53 protein and suggest that this induction after UV irradiation is not a non-specific response to any noxious stimuli.

Other publications have also reported the expression of the p53 protein in chronically sun-damaged skin and the lack of expression in non-exposed abdominal skin (3). It would be interesting to carry out further studies on the possible presence of mutations by means of other immunohistochemical studies (using the p240 monoclonal antibody) or studies of genomic DNA. It would also be interesting to evaluate whether the type of mutation is specific to UV induction or not. The fact that the mutations may be focally distributed, as has been suggested in the present study, indicates that it would probably be necessary to perform large biopsies (shave biopsies) rather than punch biopsies in order to clarify this point and to avoid false negative results.

## REFERENCES

1. Yonish-Rouach E, Resnitzky D, Lotem J, Sachs L, Kimchi A, Oren M. Wild type p53 induces apoptosis of myeloid leukaemic cells that is inhibited by interleukin-5. *Nature* 1991; 352: 345-347.
2. Lane DP. p53, guardian of the genome. *Nature* 1992; 358: 15-16.
3. McNutt NS, Saenz-Santamaria C, Volkenandt M, Shea CR, Albino AP. Abnormalities of p53 protein expression in cutaneous disorders. *Arch Dermatol* 1994; 130: 225-232.
4. Campbell C, Quinn AG, Angus B, Reed JL. The relation between p53 mutation and p53 immunostaining in non-melanoma skin cancer. *Br J Dermatol* 1993; 129: 235-241.
5. Hall PA, McKee PH, Menage HP, Dover R, Lane DP. High levels of p53 protein in UV-irradiated normal human skin. *Oncogene* 1993; 8: 203-207.
6. Campbell C, Quinn AG, Angus B, Farr PM, Rees JL. Wavelength specific patterns of p53 induction in human skin following exposure to UV radiation. *Cancer Res* 1993; 53: 2697-2699.
7. Maltzmann W, Czyzk L. UV irradiation stimulates levels of p53 cellular tumor antigen in nontransformed mouse cells. *Mol Cell Biol* 1984; 4: 1689-1694.
8. Healey E, Reynolds NJ, Smith MD, Campbell C, Farr PM, Rees JL. Dissociation of erythema and p53 protein expression in human skin following UVB irradiation, and induction of p53 protein and mRNA following applications of skin irritants. *J Invest Dermatol* 1994; 103: 493-499.