

Cutaneous Leishmaniasis: An Old Disease with a New Face

Sir,

There is a world-wide resurgence of interest in leishmaniasis both as an endemic disease of high morbidity in many countries of the Middle East and as an investigative tool of host-parasite interactions. The overall picture of the disease has been changing in several aspects. Indeed, new clinical patterns and novel discoveries on the vector front have expanded the spectrum of the disease and broadened its etiological basis. Thus, a species like *Leishmania tropica*, long considered responsible for purely cutaneous disease, has recently been reported to cause visceral illness in veterans of operation "desert storm" (1).

In Lebanon and during the 15-year civil strife, the exodus of non-immunized citizens into rural areas and neighboring endemic countries across the Middle East accounts for the change noted over the past years in the clinical presentations and the concomitant histological manifestations.

We describe 3 patients in whom the clinical and histological features are underscored.

CASE REPORTS

Case 1

A 57-year-old man complained of two skin lesions located close to the outer canthus of the right eye, of 2 months' duration. Each was a 1-cm erythematous nodule with an atrophic center and pearly telangiectatic borders (Fig. 1).

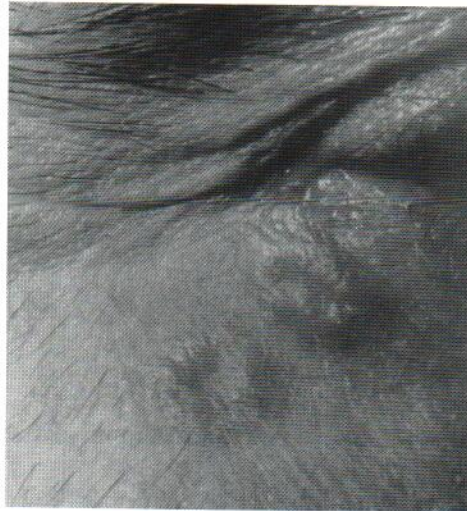

Fig. 1. Acute cutaneous leishmaniasis simulating basal cell carcinoma.

Case 2

A 53-year-old man complained of erythematous infiltrated plaques with surface scaling and erosions over the elbows bilaterally (Fig. 2). The lesions were of 4 months' duration and were gradually increasing in size. The patient had travelled to Syria, an endemic country, prior to the onset of the skin lesions.

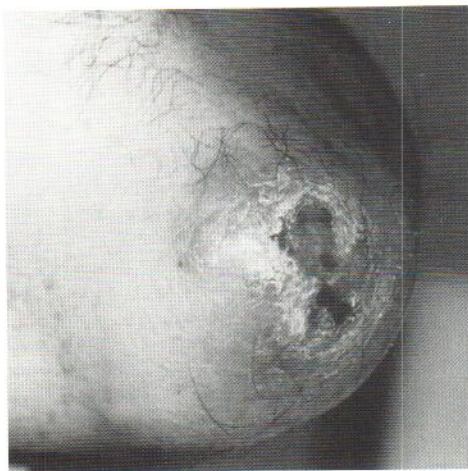


Fig. 2. Acute cutaneous leishmaniasis mimicking eczematous dermatitis.

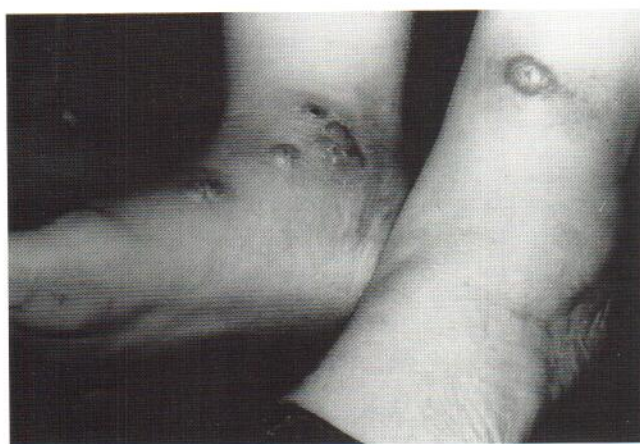

Fig. 3. Grouped sporotrichoid lesions of acute cutaneous leishmaniasis.

Case 3

A 68-year-old woman complained of multiple clustered erythematous nodules with a crateriform center over the left foot (Fig. 3). One similar lesion was present over the right foot. The lesions were of 8 months' duration. She reported travel to Syria.

Skin biopsy specimens were obtained from the 3 patients. All had a granulomatous dermatitis with numerous Leishman bodies, features typical of acute cutaneous leishmaniasis (2). In one case, there was a striking perineural lymphohistiocytic inflammatory infiltrate with relative swelling of the nerve twig.

DISCUSSION

All 3 patients were healthy and presumably immunocompetent. They had no signs or symptoms to suggest visceral disease. The clinical differential diagnoses of these patients included basal cell carcinoma, eczematous dermatitis, prurigo and other infectious granulomas.

The prototype lesion of cutaneous leishmaniasis (Old World leishmaniasis), the "oriental sore", is mainly seen in the native population, while a variety of clinical patterns are recognized in visitors to an endemic area depending on the host-parasite-vector interactions (3-5). For example, cutaneous leishmani-

asis can assume a sporotrichoid pattern due to spread of the infection along the lymphatic vessels draining the area, as was observed in one of our patients (6).

In addition, an interesting finding in one of our patients was the presence of a perineural mononuclear infiltrate. The nerve was not infiltrated by the inflammatory cells, and this feature may have been observed within an area where dense inflammation occurred. Yet, the affinity of leishmaniasis for neural tissue or "neurotropism" has recently been reported (7,8). This is an important manifestation that should be recognized, as it may be confused with leprosy, especially since these two diseases often occur in the same country.

On the vector front a novel peptide called maxadilan has recently been isolated from the salivary glands of the sandfly *Lutzomyia longipalpis* (9). This peptide has a very potent vasodilatory activity and may in addition have immunosuppressive properties. These combined biological effects of maxadilan allow the sandfly to be successful in obtaining a blood meal and help in the establishment in tissue of the *Leishmania* parasites, which reside in the salivary glands of the sandfly.

REFERENCES

- Magill AJ, Grogl M, Gasser RA, Sun W, Oster CN. Visceral infection caused by *Leishmania tropica* in veterans of operation desert storm. *N Engl J Med* 1993; 328: 1383-1387.
- Kurban AK, Kibbi AG. Diseases caused by protozoa. In: Farmer ER, Hood AF, eds. *Pathology of the skin*. Norwalk, Conn: Appleton & Lange, 1990: 366-371.
- Farah FS, Malak JA. Cutaneous leishmaniasis. *Arch Dermatol* 1971; 103: 467-474.
- Kubba R, Al-Gindan Y, El-Hassan AM, Omer AHS. Clinical diagnosis of cutaneous leishmaniasis (oriental sore). *J Am Acad Dermatol* 1987; 16: 1183-1186.
- Norton SA, Frankenburg S, Klaus SN. Cutaneous leishmaniasis acquired during military service in the Middle East. *Arch Dermatol* 1992; 128: 83-87.
- Kibbi AG, Karam PG, Kurban AK. Sporotrichoid leishmaniasis in patients from Saudi Arabia: clinical and histologic features. *J Am Acad Dermatol* 1987; 17: 759-764.
- Kubba R, El-Hassan AM, Al-Gindan Y, Omer AHS, Bushra M, Kutty MK. Peripheral nerve involvement in cutaneous leishmaniasis (Old World). *Int J Dermatol* 1987; 26: 527-531.
- Satti MB, El-Hassan AM, Al-Gindan Y, Osman MA, Al-Sohaibani MO. Peripheral neural involvement in cutaneous leishmaniasis. A pathologic study of human and experimental animal lesions. *Int J Dermatol* 1989; 28: 243-247.
- Lerner EA, Ribeiro JMC, Nelson RJ, Lerner MR. Isolation of maxadilan, a potent vasodilatory peptide from the salivary glands of the sand fly *Lutzomyia longipalpis*. *J Biol Chem* 1991; 266: 11234-11236.

Accepted October 18, 1995.

Abdul-Ghani Kibbi¹, Lina Hassouna² and Nelly G. Rubeiz²

¹Department of Dermatology, American University of Beirut, 850 Third Avenue, New York, N.Y. 10022, USA and ²Department of Dermatology, American University of Beirut, Medical Center, Beirut, Lebanon.