

A Case of Actinic Granuloma Associated with Periumbilical Perforating Pseudoxanthoma Elasticum

HYOUNG WOO LEE, MIN AH PARK, SEUNG CHUL LEE, YOUNG HO WON and INN KI CHUN

Department of Dermatology, Chonnam University Medical School, Kwangju, Korea

We report an unusual case of actinic granuloma of the face and periumbilical perforating pseudoxanthoma elasticum located superior to the umbilicus in a 57-year-old Korean woman. Histopathologically, these two dermatoses have a similar degeneration of elastic fibers, but they show different host reactions to the altered elastic fibers. In the actinic granuloma, actinically damaged elastic fibers were followed by granulomatous infiltration on the sun-exposed area, while in the perforating pseudoxanthoma elasticum, the altered elastic fibers induced a foreign body reaction, with subsequent transepidermal elimination. This is the first case report showing both actinic granuloma and periumbilical perforating pseudoxanthoma elasticum in the same patient, which suggests that the basic mechanism eliciting these dermatoses is similar. *Key word: elastic fiber degeneration.*

(Accepted September 8, 1995.)

Acta Derm Venereol (Stockh) 1996; 76: 133–135.

Inn Ki Chun, M.D., Department of Dermatology, Chonnam University Hospital, 5 Hack-Dong, Tongku, Kwangju City, 501-757, Korea.

Actinic granuloma (AG) is characterized by the development of annular plaques on sun-exposed skin, especially on the face. Originally the disorder was described by O'Brien (1) as an "elastotic" connective tissue disorder caused by solar damage. Since his first description, there have been hot discussions about the disorder in relation to the clinical term associated with its pathogenesis. Hanke et al. (2) proposed to use a more general term not specifying solar origin for the disorder as an "annular elastolytic giant cell granuloma (AEGCG)". In perforating pseudoxanthoma elasticum (PPXE), elastotic material is removed by transepidermal elimination instead of forming a granulomatous reaction in the dermis. The disorder was first described by Hicks et al. (3) in 6 black patients – multiparous, obese women whose skin lesions were confined to the anterior portion of the trunk, especially around the umbilicus. We here describe a patient with, initially, skin lesions of AG and then after a year, with lesions of PPXE. It is interesting that two dermatoses have a similar pathogenesis of elastosis but show different reactions to the elastotic materials in the host reaction. This is the first reported case showing both dermatoses in the same patient, suggesting that the basic mechanism eliciting the disorder is similar.

CASE REPORT

A 57-year-old Korean woman first visited our clinic in July 1990, complaining of dull erythematous annular lesions on the forehead. She had had reddish papules on the forehead for approximately 3 years prior to our clinical examination. The lesions began as an asymptomatic papule and had been slowly enlarging. She denied a history of trauma including any kind of operation, diabetes mellitus, hypertension, or pulmonary tuberculosis.

Physical examination revealed several annular plaques, up to 2.5 cm in diameter, on the forehead (Fig. 1). The annular eruption had an

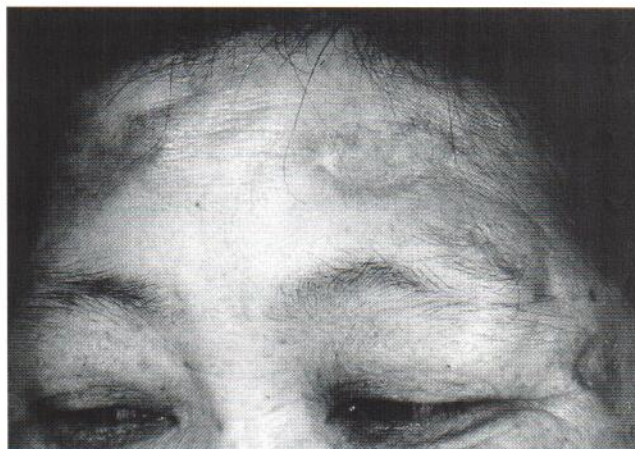

Fig. 1. Several annular plaques with erythematous elevated border and atrophic hypopigmented center on the forehead.

erythematous raised border and slightly depressed hypopigmented centers. Occasionally reddish papules were intermingled with the plaques. These papules had gradually enlarged centrifugally, with central healing, and had evolved into large annular plaques. Her general condition was good, except for the skin lesions.

Laboratory examinations, including complete blood cell count, urinalysis, liver function test, serum electrolytes, serum fasting glucose and serum angiotensin converting enzyme level, were within normal limits. A chest X-ray film showed no abnormalities and an electrocardiogram showed premature ventricular contraction.

The skin biopsy specimens were obtained from the elevated border of an annular plaque on the forehead. Histopathologic examination of the hematoxylin-eosin-stained specimen showed a disappearance of elastic fibers and a granulomatous infiltration composed of lymphocytes, histiocytes and several foreign body and Langhans' giant cells in the mid- and lower dermis. Fragments of elastic fibers were engulfed within a few giant cells (Fig. 3). Necrobiosis was absent, and there were no deposits of mucin or lipid. The Verhoeff-van Gieson's-stained section showed black-colored curled, thickened and fragmented elastic fibers in the dermis (Fig. 4). Intra-dermal injections of corticosteroid (triamcinolone acetonide 2.5 mg/ml every 2 weeks for 2 months) were given into the borders of the annular lesions of the forehead. Enlargement of the lesions ceased and the elevated border flattened.

One year later the patient noticed an asymptomatic abdominal lesion. A well-defined hyperpigmented plaque (approximately 2 × 1.5 cm) with an irregular surface located 1.5 cm superior to the umbilicus was observed (Fig. 2). The lesion had a firm, verrucous surface studded with hyperkeratotic papules. She was multiparous, gravida 6 and obese with excessive body weight for her height. A skin biopsy was taken from the periumbilical hyperpigmented plaque. Histologic examination of the hematoxylin-eosin-stained specimen showed fragmented, basophilic elastic fibers in the mid- and lower dermis. In Verhoeff-van Gieson's stain, the altered short fragmented elastic fibers were extruded through the hyperplastic epidermis and from the adjacent dermis (Fig. 5). The von Kossa's stain showed calcium deposit along the altered elastic fibers in the mid- and lower dermis (Fig. 6). The lesion was completely excised, but approximately 1 month later asymptomatic papules developed on the previous excision site.

DISCUSSION

AG was first described by O'Brien (1) in 1975 to define an annular eruption on habitually sun-exposed skin, which

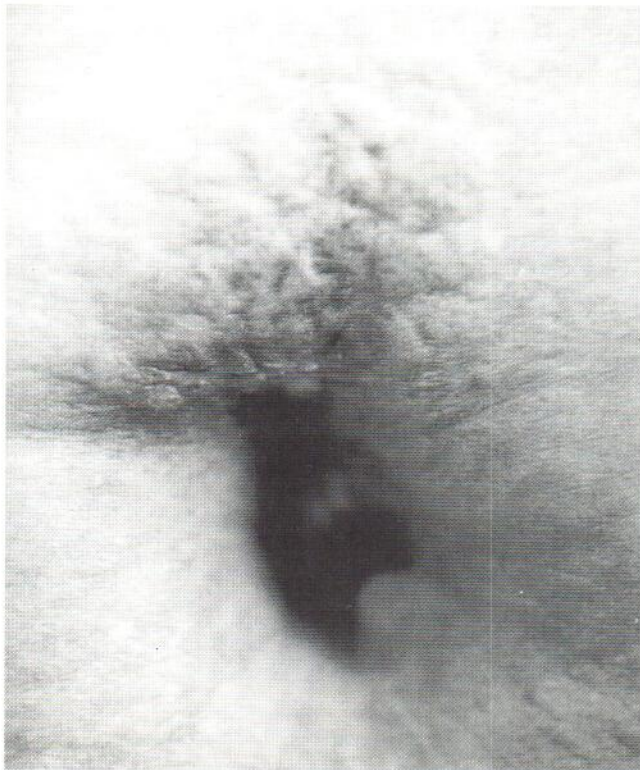


Fig. 2. Well-demarcated, yellow-colored verrucous plaque of pseudo-xanthoma above the umbilicus.

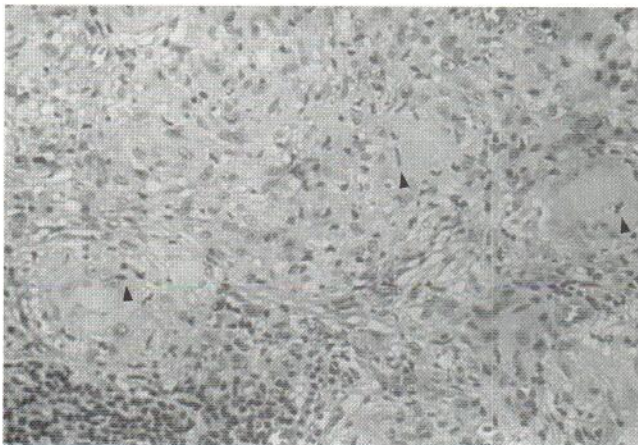


Fig. 3. Multinucleate giant cells containing cytoplasmic fragments of elastic fibers (arrowhead) (hematoxylin-eosin stain, X100).

showed microscopically three zones: a central zone with absence of elastic fibers; an annular zone with consumption of elastotic and normal elastic fibers by giant cells and histiocytes; and a non-inflammatory external zone of actinic elastosis. Other authors have described similar cases as Miescher's granuloma of the face (4), and atypical necrobiosis lipoidica of the face and scalp (5).

In 1979, Hanke et al. (2) observed some clinical and histopathologic features similar to those described by O'Brien, but solar elastosis was not necessarily observed in some cases. They proposed the more appropriate term "annular elastolytic giant cell granuloma (AEGCG)" to describe the similar mor-




Fig. 4. Curled clamps of aggregated elastic fibers in the dermis (Verhoeff-van Gieson stain, X400).

phologic changes in patients with cutaneous eruptions arising in non-sun-exposed skin. Ishibishi et al. (6) reported AEGCG occurring in areas not exposed to the sun, i.e. the chest, abdomen and inguinal region.

Ragaz & Ackermann (7) claimed that AG was not a separate disease entity but an example of granuloma annulare based on the fact that absence of elastic tissue occurred in all cases of granuloma annulare, that the presence of elastotic material within giant cells can be seen in any granulomatous process, and that there is not a consistent association between solar elastosis and granulomatous inflammation of the skin. However, Steffen (8) reported 12 cases of AG and described the difference between AG and granuloma annulare. The most striking difference was the absence of elastic fibers in the mid-dermis within the granuloma (within the clinical annulus) in AG.

PPXE was initially described by Hicks et al. (3) in 1979. Clinically, the cutaneous lesions are periumbilical, well-demarcated, hyperpigmented patches or plaques with atrophic, grooved, fissured or verrucous surface. In 1979, Neldner & Martinez-Hernandez (9) described this disease entity as localized acquired cutaneous pseudoxanthoma elasticum, which is clinically, histopathologically, and ultrastructurally similar to the inherited form of pseudoxanthoma, but it is distinguished by negative family history, late onset, localized cutaneous lesion or absence of flexural skin lesion, and absence of an angiod streak or other systemic manifestations.

It is very interesting that both AG and PPXE can be coexistent in the same patient, in view of the fact that both have a similar disorder affecting the elastic tissue. Abnormal elastotic materials formed by various causes should be eliminated from the tissue by different host reactions.

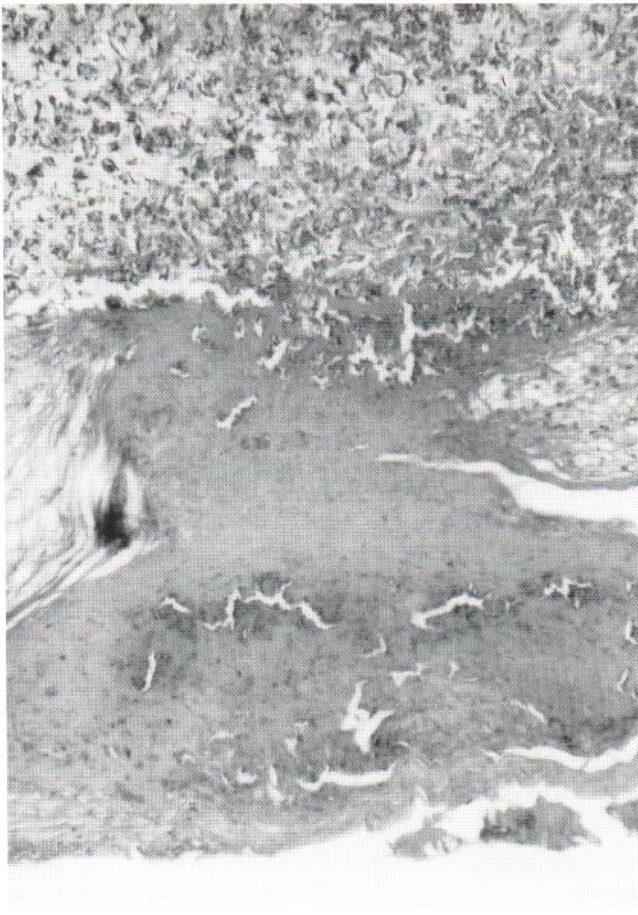

Fig. 5. Altered short fragmented elastotic fibers are extruded through the hyperplastic epidermis and present in the adjacent dermis (Verhoeff-van Gieson stain, X100).

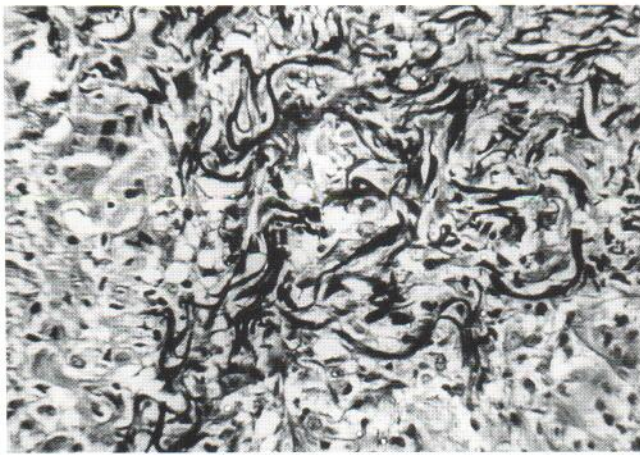


Fig. 6. Fragmented and irregularly clumped calcified elastic fibers in the mid- and lower dermis (von Kossa stain, X20).

In the case of AG, many granulomatous reactions with giant cells engulfing elastic fibers were elicited, while transepidermal elimination of altered elastica in PPXE is another mechanism to remove abnormal elastic fibers from the dermis.

McGrae (10) described immunohistochemical findings of AG, which revealed the presence of lysozyme in giant cells and a predominance of T helper cells in the lymphocytic

infiltrate associated with the granuloma, and postulated that the pathogenesis may involve a cell-mediated immunologic response against weakly antigenic determinants on actinically altered elastic fibers.

The perforation in PPXE is not a specific pathognomic phenomenon but a secondary reaction to eliminate abnormal elastic fibers. Some reported this condition as the coexistence of pseudoxanthoma elasticum and elastosis perforans serpiginosa. But Lund & Gilbert (11) reviewed the previous 7 cases and proposed that conditions were not separate but that it was pseudoxanthoma elasticum with perforation and secondary transepidermal elimination.

Hicks et al. (3) suggested that patients were genetically predisposed to pseudoxanthoma elasticum and that damage to elastic fibers from multiple traumatic events causing abdominal distension such as multiparity, obesity, massive ascites (9), abdominal surgery, or saltpeter (calcium chloride) exposure (12), produces abnormal elastic fibers which, when superficially located, undergo transepidermal elimination. Our patient was an obese, multiparous woman, which may have caused PPXE.

We postulate that the patient had a degeneration of elastic fibers caused by solar damage with subsequent granulomatous infiltration on the sun-exposed area, and genetically abnormal elastic fibers, which induced a foreign body reaction and subsequently extrusion of altered elastic fibers by transepidermal elimination. We present this case as a combined case of actinic granuloma confined to the sun-exposed skin (face) and perforating pseudoxanthoma elasticum limited to the periumbilical area, and suggest that different mechanisms are responsible for eliminating altered elastic fibers, causing clinically discriminative dermatoses.

REFERENCES

- O'Brien JP. Actinic granuloma: an annular connective tissue disorder affecting sun- and heat-damaged (elastotic) skin. *Arch Dermatol* 1975; 111: 460-466.
- Hanke CW, Bailin PL, Roenigk HH. Annular elastolytic giant cell granuloma: a clinicopathologic study of five cases and a review of similar entities. *J Am Acad Dermatol* 1979; 1: 413-421.
- Hicks J, Carpenter CL Jr, Reed RJ. Periumbilical perforating pseudoxanthoma elasticum. *Arch Dermatol* 1979; 115: 300-303.
- Mehregan AH, Altman J. Miescher's granuloma of the face. *Arch Dermatol* 1973; 107: 62-64.
- Dowling GB, Wilson-Jones E. Atypical necrobiosis lipoidica of the face and scalp. *Dermatologica* 1967; 135: 11-26.
- Ishibashi A, Yokoyama A, Hirano K. Annular elastolytic giant cell granuloma occurring in covered area. *Dermatologica* 1987; 174: 293-297.
- Ragaz A, Ackermann AB. Is specific granuloma a specific condition? *Am J Dermatopathol* 1979; 1: 43-50.
- Steffen C. Actinic granuloma (O'Brien). *J Cutan Pathol* 1988; 15: 66-74.
- Neldner KH, Martinez-Hernandez A. Localized acquired cutaneous pseudoxanthoma elasticum. *J Am Acad Dermatol* 1979; 1: 523-530.
- McGrae JD. Actinic granuloma: a clinical, histologic, and immunohistochemical study. *Arch Dermatol* 1986; 122: 43-47.
- Lund HZ, Gilbert CF. Perforating pseudoxanthoma elasticum: its distinction from elastosis perforans serpiginosa. *Arch Pathol Lab Med* 1976; 100: 544-546.
- Nielsen AO, Christensen OB, Hentzer B, Hentzer B, Johnson E, Kobayasi T. Saltpeter-induced dermal change electron-microscopically indistinguishable from pseudoxanthoma elasticum. *Acta Derm Venereol (Stockh)* 1978; 58: 323-327.