

## Metabolic Carotenemia and Carotenoderma in a Child

ÅKE SVENSSON<sup>1</sup> and ANDERS VAHLQUIST<sup>2</sup>

Departments of Dermatology, <sup>1</sup>County Hospital, Kristianstad, and <sup>2</sup>University Hospital, Linköping, Sweden

**We describe a 3-year-old girl with long-standing yellow discoloration of her skin and a 3-fold increase in the plasma carotenoid concentration compared to normal, but no history of excessive carotene intake or familial carotenemia. When put on a carotene-deficient diet for 8 months she still had some remaining yellow discoloration in the nasolabial folds and on the palms and soles. The results of an oral loading with  $\beta$ -carotene (1 mg/kg) provide indirect evidence that the girl's carotenemia is due to a probably genetic defect in the metabolism of carotenoids.**

(Accepted August 15, 1994.)

Acta Derm Venereol (Stockh) 1995; 75: 70-71.

A. Vahlquist, Department of Dermatology, University Hospital, S-581 85 Linköping, Sweden.

Carotenoderma is usually a trivial sign of excessive intake of vegetables, especially carrots and tomato juice. Rarely, however, carotenoderma and the underlying carotenemia are of metabolic origin (1). For example, hypothyroidism may be associated with decreased ability of the intestine wall to convert carotenoids to vitamin A, and as a result the patients will accumulate carotenoids in the blood and tissues. The enzymes responsible for cleaving  $\beta$ -carotene into two molecules of retinoids (2) may also be genetically abnormal (3). In situations with deficient intake of preformed vitamin A, such a genetic defect may eventually lead to hypovitaminosis A unresponsive to supplementation with pro-vitamin A carotenoids (4, 5). We here report on a healthy child who had asymptomatic yellow discoloration of her skin and was found to have a probably genetically induced carotenemia.

### CASE REPORT

An otherwise healthy 3-year-old girl was referred from a pediatrician because of an unexplained yellow discoloration of the skin. According to the parents she had been tired and had had a poor appetite for about one month, i.e. as long as they had noticed that she had a change in her skin colour. No relatives were known to have had a similar yellow discoloration. Examination revealed a marked yellow discoloration on the palms and soles and to a lesser degree on the knees, on the proximal and medial parts of the thighs, on the abdomen, in the nasolabial folds and on the nose. Mucous membranes including the sclerae were unstained.

Laboratory investigations showed normal values for sedimentation rate, hemoglobin, white blood cell count including differential count, liver function tests (bilirubin, ASAT, ALAT, alkaline phosphatase), creatinine, blood glucose, and thyroid-stimulating hormone. Plasma carotenoids were extracted with hexane after KOH-ethanol saponification and analyzed by spectrophotometry (Fig. 1). In comparison to healthy control plasma, the patient's sample showed three prominent absorption peaks at 430, 450 and 480 nm, similar to those observed when authentic  $\beta$ -carotene was dissolved in hexane. The plasma carotenoid concentration was determined from the absorption value at 450 nm (minus extrapolated background absorption) using an extinction coefficient of 2,500 (6). The girl's plasma carotenoid value was 5.74  $\mu\text{mol/l}$ , i.e. 3

times higher than the mean  $\pm$  SD values for unrelated normal adults (1.49  $\pm$  0.58  $\mu\text{mol/l}$ ;  $n=11$ ) and age-matched controls (1.37  $\pm$  0.11  $\mu\text{mol/l}$ ,  $n=3$ ; age 2-6 years). The carotenoid values of her relatives (parents, grandmothers, and a 1-year-old sister) were in the normal range (0.70 to 1.75  $\mu\text{mol/l}$ ).

In order for us to further investigate the cause of the girl's carotenoderma, her intake of carotene-rich food was restricted for a period of 8 months. At the end of this period her skin discoloration was reduced but still visible in the nasolabial folds and on the palms and soles. The plasma carotenoid concentration had now fallen to 2.47  $\mu\text{mol/l}$ , i.e. 2 times the normal value. We then studied the girl's plasma response to a single dose of oral  $\beta$ -carotene and compared it to that of 11 healthy adults. Each person received one individually dispensed gelatin capsule containing  $\beta$ -carotene (in a 30% solution kindly provided by Roche AB, Sweden), corresponding to 1 mg/kg body weight according to the suggestions by Canfield et al. (7). The capsule was given in the morning together with a fat-containing meal. Blood samples were drawn before and at 3 different time points after dosing. Fig. 2 shows that, whereas the mean plasma carotenoid concentrations of the controls were unchanged after  $\beta$ -carotene loading, the girl's values increased and remained elevated during the study period. Incidentally, the plasma vitamin A concentrations, determined by an HPLC assay (6), were unchanged in both the patient (1.03  $\pm$  0.13  $\mu\text{mol/l}$ ) and the controls (1.69  $\pm$  0.04  $\mu\text{mol/l}$ ) after  $\beta$ -carotene loading.

### DISCUSSION

Carotenoderma is a rare differential diagnosis to jaundice. The patchy distribution of the discoloration, the normal sclerae, and the absence of itching and scratch effects are some clinical findings which should bring this diagnosis into consideration. The yellow discoloration of the skin appearing in any fair-skinned person after excessive intake of carrots tends to appear after 6 to 8 months and fades in 2 to 6 weeks after restricted intake of carotenoids (1). Carotenoids accumulate in the epidermis (6) but there is a 2-week delay in the equilibrium between plasma and skin carotenoid level (8). Carotenoderma is probably a harmless condition, although amenorrhea has occasionally been associated with excessive intake of carotene-rich vegeta-

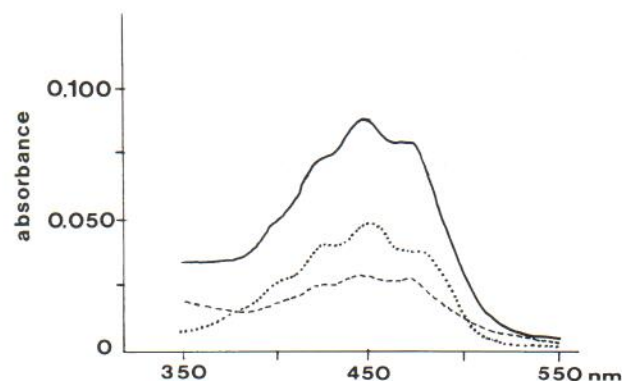


Fig. 1. Absorption spectra (in hexane) of the patient's plasma (full-drawn line), control plasma (interrupted line) and authentic  $\beta$ -carotene (dotted line). The absorbance was recorded in a Perkin Elmer spectrophotometer (model 101).



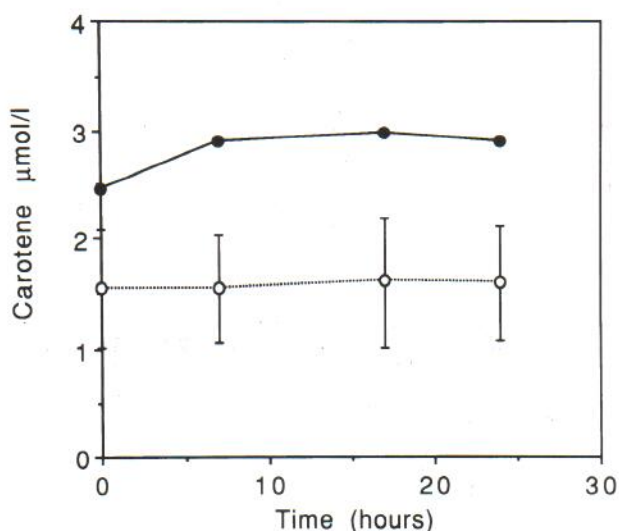


Fig. 2. Plasma carotenoid concentrations in the patient (closed circles) and 11 healthy adult controls (mean  $\pm$  SD; open circles) before and after an oral dose of  $\beta$ -carotene (1 mg/kg) in the morning (time zero).

bles (9). However, the causative relationship is uncertain, since vegetables contain many substances other than carotenoids which may be incriminated.

In our patient a yellow skin discoloration appeared early in childhood and without any history of excessive carotenoid intake. Diabetes, renal disease and hypothyroidism were excluded as cause of the symptoms. Her carotenoderma and carotenemia did not fully normalize despite 8 months of restricted intake of carotene-rich food. When given a standardized dose of oral  $\beta$ -carotene, she responded with an abnormally large increase in the plasma carotenoid concentration, suggesting that she either had a facilitated uptake of  $\beta$ -carotene through the intestinal wall or was unable to convert  $\beta$ -carotene to vitamin A as normally occurs. Although we are unable to discriminate between these two possibilities (the dose of  $\beta$ -carotene (1 mg/kg) was not sufficient to increase the plasma vitamin A levels in the controls

either), there is little doubt that the girl suffers from a genetic defect of carotene metabolism.

Familial hypercarotenemia has been reported previously (4, 5), but its mode of inheritance is unknown. In our case no abnormal plasma carotenoid values were found in the patient's relatives, suggesting that she either has had a dominant new mutation or is homozygotic for an autosomally recessive allele carried by both parents. With modern molecular biology techniques, the gene(s) responsible for familial carotenemia should be possible to identify.

#### ACKNOWLEDGEMENT

The valuable technical assistance of Ms Eva Andersson is gratefully acknowledged.

#### REFERENCES

1. Cohen L. Observations on carotenemia. *Ann Intern Med* 1958; 48: 219-227.
2. Goodman DS, Huan HS, Kanai M, Shiratori T. The enzymatic conversion of all-trans  $\beta$ -carotene into retinal. *J Biol Chem* 1967; 242: 3543-3554.
3. Monk BE. Metabolic carotenemia. *Br J Dermatol* 1982; 106: 485-488.
4. McLaren DS, Zekian B. Failure of enzymatic cleavage of  $\beta$ -carotene. *Amer J Dis Child* 1971; 121: 278-280.
5. Sharvill DE. Familial hypercarotenemia and hypovitaminosis A. *Proc Roy Soc Med* 1970; 63: 605-606.
6. Vahlquist A, Lee JB, Michaëlsson G, Rollman O. Vitamin A in human skin II: concentrations of carotene, retinol and dehydroretinol in components of normal skin. *J Invest Dermatol* 1982; 79: 94-97.
7. Canfield LM, Bulux J, de Serrano JQ, Rivera C, Lima AF, Lopez CY, et al. Plasma response to oral  $\beta$ -carotene in Guatemalan school-children. *Am J Clin Nutr* 1991; 54: 539-547.
8. Prince MR, Frisoli JK. Beta-carotene accumulation in serum and skin. *Am J Clin Nutr* 1993; 57: 175-181.
9. Kemmann E, Pasquale SA, Skaf R. Amenorrhoea associated with carotenemia. *JAMA* 1983; 249: 926-929.