

No Evidence of Human Papillomavirus Infection in Balanitis Circumscripta Plasmacellularis Zoon

Sir,

Balanitis circumscripta plasmacellularis represents an entity first described by Zoon (1) in 1952 and has therefore been named Zoon's disease. Even though it is now regarded as a well-described clinical and histological entity, the pathogenesis of these lesions remains speculative. Chronic bacterial or fungal infections, friction as well as poor hygiene have been postulated as predisposing factors (2-4). Analogous lesions have rarely been observed in women and were reported under a variety of synonyms as "benign plasma cell erythroplasia" "Zoon's vulvitis" and "Vulvitis chronica plasmacellularis" (5-7). To investigate a relationship to human papillomaviruses (HPV), we analysed specimens by the polymerase chain reaction (PCR).

MATERIALS AND METHODS, AND RESULTS

Patients

A total of 22 specimens of Zoon's disease, histologically and clinically diagnosed over a period of 8 years, were employed for immunohistochemical and molecular biology studies. The patient age ranged from 36 to 74 years, with a mean value of 58.2 years at the time of biopsy. The majority of lesions ($n=21$) were solitary and located on the glans penis ($n=15$); others were seen on the mucosal aspect of the prepuce ($n=5$) and only rarely in the coronal sulcus ($n=2$). Clinically the lesions presented as well circumscribed round erythematous and brownish macules with a maximum diameter of 3.5 cm.

Histological and immunohistochemical analyses

Formalin-fixed and paraffin-embedded tissues were stained with hematoxylin-eosin, Giemsa, Gram, PAS and Perl's stain. The histological observations revealed typical changes of the epithelial layer as well as the characteristic plasma cell infiltrate of the upper dermis, mostly distributed in a lichenoid pattern. Immunohistochemical analyses were carried out with anti-kappa light chain (Dako, Hamburg, Germany) and anti-lambda light chain (Dako, Hamburg, Germany) antibodies using the ABC method (Vector Stain, USA) and 3-amino-9-ethyl (AEC) chromogen for the detection of specific immunoreactivity. The staining pattern revealed a bitypical and therefore polyclonal expression pattern of light chain antigens by the plasma cell infiltrate.

Polymerase chain reaction (PCR)

Sections of buffered formalin-fixed, paraffin-embedded specimens were prepared with sterile blades and transferred to sterile tubes. The further procedure included boiling for 15 min according to the chelatin resin method, as previously described (8). Using this method we were previously able to detect HPV sequences in autoptic and bioptic material up to 12 years of age (8). PCR was carried out using Perkin Elmer Cetus reagents as well as human papillomavirus consensus primers (Perkin Elmer Cetus, USA), as described by Manos et al. (9). Primers amplifying a 268 base fragment of the human β -globin genome (Perkin Elmer Cetus, USA) were used to prove the presence of sufficient material for PCR processing within the specimens investigated. After amplification, a portion of the mixture was separated by agarose gel electrophoresis using ethidium bromide staining for the

visualization of DNA by ultraviolet transillumination. In all runs positive and negative controls were included.

The PCR analyses demonstrated sufficient DNA material for amplification by detection of the human β -globin genome, while no specimen revealed evidence of HPV infection, investigated by the "consensus primers" (Fig. 1).

DISCUSSION

Since the first description of a plasmacellular infiltrate in erythematous lesions of the glans penis by Zoon (1) in 1952, who named his findings "Balanoposthite chronique circonscrite b nigne   plasmocytes", these lesions have been recognized as a clinical and histological entity (2, 3). While on clinical presentation erythroplasia of Queyrat has to be taken into the differential diagnosis, the histological features of balanitis circumscripta plasmacellularis are distinct.

Even though the clinical and histological aspects are well defined, the etiology of this condition remains uncertain, and a variety of predisposing factors have been discussed (2-4). Besides poor hygiene, chronic infection has been thought to play a major role in the pathogenesis of this disease, especially because of the low frequency of Zoon's disease in circumcised men and the improvement of lesions after circumcision (10-12). HPV form a group of DNA viruses which have been increasingly investigated over the last years, and their frequent occurrence has not only been noticed in benign lesions such as condylomata acuminata and verruca vulgaris, but also in premalignant and malignant diseases including genital bowenoid lesions or cervical carcinomas (13-16). While some HPV types are associated with benign lesions, others tend to be present in premalignant and malignant tumours. Especially HPV type 16 and 18 infections have been demonstrated in cervical neoplasias in percentages as high as 95% (16, 17), and HPV type 16 has also been found in penile carcinomas and their metastases (18).

Since HPV infection can be latent or display only subclinical symptoms, the detection of "high-risk" HPV infection in men can be useful for determination of patients bearing a risk for

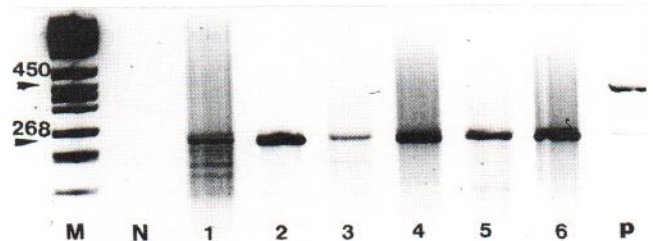


Fig. 1 PCR analysis of paraffin-embedded sections of Zoon's disease. Visualization by ethidium bromide staining. *M*=molecular weight marker (Hae III digested pBR 322 DNA). *N*=negative control. *P*=positive control (condylomata acumin.). Lanes 1-6: 268 amplicon of the β -globin genome. Lane *P*: 450 amplicon of the HPV genome, also a weak but detectable 268 amplicon.

the development of malignant lesions or for transmitting the infection to their sexual partners (19).

Our patients demonstrated typical clinical and morphological features of Zoon's disease as well as a polyclonal pattern of infiltrating plasma cells, findings that correspond with the proposed benign biological nature of this chronic disease.

The investigation of HPV DNA within the specimens demonstrated lacking of associated genital HPV infection in lesional skin of balanitis circumscripita plasmacellularis, a finding that might be explained by the patients average age of 58.2 years in our cohort. Therefore, we conclude that HPV infection and Zoon's disease are not related, a molecular biology result that corresponds with the histological features of Zoon's disease, which are not suspicious for viral infection.

REFERENCES

- Zoon JJ. Balanoposthite chronique circonscrite bénigne à plasmocytes. *Dermatologica* 1952; 105: 1-11.
- Jonquieres EDL, de Lutzky FK. Balanites et vulvites pseudoerythroplasiques chroniques. Aspects histopathologiques. *Ann Dermatol Venereol* 1980; 107: 173-180.
- Souteyrand P, Wong E, MacDonald DM. Zoon's balanitis (balanitis circumscripita plasmacellularis). *Br J Dermatol* 1981; 105: 195-199.
- Montgomery J. *Dermatopathology*. Vol. 2. New York, London: Harper & Row, 1967.
- Zoon JJ. Balanitis and vulvitis plasmacellularis. *Dermatologica* 1955; 11: 157-162.
- Garnier G. Benign plasma cell erythroplasia. *Br J Dermatol* 1982; 106: 585-588.
- Davis J, Shapiro L, Baral J. Vulvitis circumscripita plasmacellularis. *J Am Acad Dermatol* 1983; 8: 413-416.
- Kiene P, Milde-Langosch K, Runkel M, Schulz K, Löning T. A simple and rapid technique to process formalin-fixed paraffin-embedded tissues for the detection of viruses by the polymerase chain reaction. *Virchows Archiv A Pathol Anat* 1992; 420: 269-273.
- Manos MM, Ting Y, Wright DK, Lewis AJ, Broker TR, Wolinsky SM. Use of polymerase chain reaction for the detection of genital human papillomaviruses. *Cancer Cells* 1989; 7: 209-214.
- Sutton RL. In: *Diseases of the skin*. 11th edn. St. Louis: C.V. Mosby Company, 1956.
- Sonnex TS, Dawber RPR, Ryan TJ, Ralfs IG. Zoon's disease (plasma cell) balanitis: treatment by circumcision. *Br J Dermatol* 1982; 106: 585-588.
- Murray WJG, Fletcher MS, Yates-Bell AJ, Pryor JP, Darby AJ, Packham DA. Plasma cell balanitis of Zoon. *Br J Urol* 1986; 58: 689-691.
- De Villiers E. Heterogeneity of the human papillomavirus group. *J Virol* 1989; 63: 4898-4907.
- zur Hausen H, Schneider A. The role of papillomaviruses in human anogenital cancer. In: *The papovaviridae: the papillomaviruses*. Vol. 2. New York: Plenum Press, 1987: 245-264.
- Gissmann L, de Villiers EM, zur Hausen H. Analysis of human genital warts (condylomata acuminata) and other genital tumors for human papillomavirus type 6 DNA. *Int J Cancer* 1982; 29: 143-146.
- Durst M, Gissmann L, Ikenberg H, zur Hausen H. A papilloma virus DNA from a cervical cancer and its prevalence in cancer biopsy samples from different geographic regions. *Proc Natl Acad Sci USA* 1983; 80: 3812-3815.
- Crum CP, Nagai N, Levine R, Silverstein S. In situ hybridization analysis of HPV 16 DNA sequences in early cervical neoplasia. *Am J Pathol* 1986; 123: 174-182.
- Saltzstein D, Orihuela E, Rady P, Scinicariello F, Tyring S, Warren M. Integration of human papillomavirus (HPV) 16 DNA in the genome of primary and metastatic squamous cell cancer (SCC) of the penis. *J Urol* 1992; 147: 368A.
- Barrasso R, de Brux J, Croissant O. High prevalence of papillomavirus associated penile intraepithelial neoplasm in sexual partners of women with cervical intraepithelial neoplasm. *N Engl J Med* 1987; 317: 916-923.

Accepted May 30, 1995.

Petra Kiene and Regina Fölster-Holst
Department of Dermatology, University of Kiel, Schittenhelmstr. 7,
D-24105 Kiel, Germany.