

## Solar Pruritus

NIELS BECH-THOMSEN and KRISTIAN THOMSEN

Department of Dermatology, The National University Hospital, Rigshospitalet, Copenhagen, Denmark

**A case of solar pruritus is reported. Severe pruritus of the back, shoulders and upper lateral aspects of the arms, without any eruption, developed in a 28-year-old outdoor worker during 4 to 6 weeks of intensive solar exposure. The pruritus was intense and described as a burning sensation deep in the skin. Only a few excoriations and slight xerosis were found. Solar pruritus or brachioradial pruritus is a condition primarily seen in Caucasian people living in the tropics or subtropics. Previously the disease has only been reported once outside these areas.**

**Key word: brachioradial pruritus.**

(Accepted May 29, 1995.)

Acta Derm Venereol (Stockh) 1995; 75: 488-489.

N. Bech-Thomsen, Department of Dermatology, The National University Hospital, Rigshospitalet H-5192, Blegdamsvej 9, DK-2100 Copenhagen Ø, Denmark.

Solar pruritus, also known as brachioradial pruritus, is a tropical dermatosis with intense pruritus described as a "crawling under the skin" or a "pins and needles itch" sensation, which has a distinct localization but lacks visible skin changes (1-3). The disease often occurs in patients with a history of chronic sun exposure. Protection of the affected area against further solar exposure and treatment with capsaicin cream may offer relief to these patients (3, 4).

### CASE REPORT

A 28-year-old male, without a history of previous skin disease, was admitted to the department with a 4- to 6-week history of intense pruritus localized to the upper back, shoulders and upper lateral aspects of the arms. The pruritus was located to a well-defined area that the patient could easily point out (Fig. 1). The pruritus was

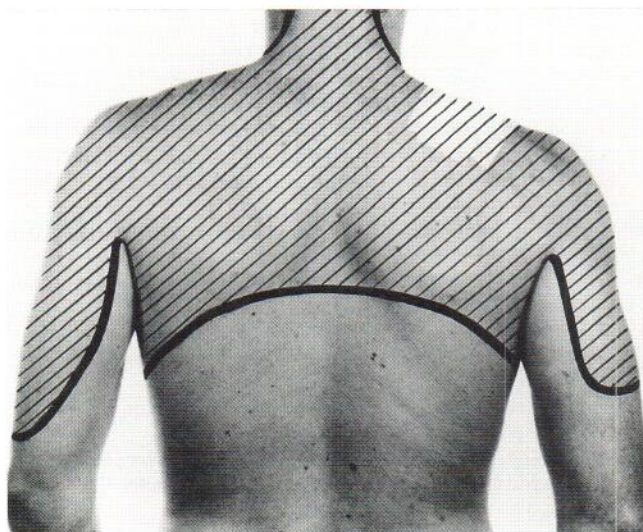


Fig. 1. Localization of pruritus.

described as a burning sensation in the skin. The patient had noticed that it did not help to scratch, but pinching gave some relief. The symptoms were worst in the evening when the patient was not occupied with work. The patient had not noticed any papular reactions or any other skin signs in the pruritic areas. He had been treated with emollients and topical steroids without effect. The patient was a bricklayer and had worked outdoors without clothes on the upper part of the body during the extraordinary warm and sunny summer of 1994. In the previous years he had suffered many severe sunburns, especially on the shoulders, but despite repeated intense solar exposure he had never had a suntan. This year he had not been sunburned.

The patient's hair was reddish brown and his eyes were brown. A careful examination of the pruritic skin showed no sign of papular eruptions or exanthematous reactions. The skin appeared normal, with a few excoriations and a slight xerosis. This was in strong contrast with the severe subjective symptoms. There were solar lentigines on the shoulders but otherwise no sign of actinic damage.

Complete blood counts, erythrocyte rate, alanine-aminotransferase and creatinine were normal. Skin reflectance measurements were performed with a UV-Optimize (Matic, Copenhagen, Denmark), as previously described (5). The skin pigmentation of the buttock area was 11% (Danish mean: 15%), and on the shoulders and the back 16% (Danish mean: 28%). A biopsy taken from the right shoulder showed some hyperkeratosis and a slight non-specific inflammation around the vessels in the upper dermis.

The patient was admitted in early September and treated with 0.05% capsaicin cream (Dolor-Vinci, Pharma-Vinci, Frederiksværk, Denmark) four times a day until his symptoms disappeared, which happened within a couple of weeks. He had a relapse of his pruritus after a travel to Turkey in late September despite the use of a sunscreen with a sun protection factor of 15.

### DISCUSSION

This condition has been named "brachioradial pruritus" because the chronic intermittent pruritus is often localized to the external aspects of the elbow at the proximal heads of the brachioradialis muscles (1). Others prefer the term "solar pruritus" since the pruritus often affects other parts of the body (2). The condition usually appears bilaterally, but often the left side itches alone or predominantly (1). One exception was a locomotive engineer whose chronic solar exposure at the right window of the cab produced pruritus of his right elbow (1). This indicates that the localization of the condition is not confined to a specific anatomic area but may occur at any site which is chronically exposed to sunlight. In our patient the affected area corresponded to the most exposed parts of the body during his outdoor work. Our patient already had signs of chronic solar damage, with solar lentigines (6) and a light hyperkeratosis.

According to the Fitzpatrick classification (7), our patient should be classified as skin type I. This was supported by the skin reflectance measurements. The ability of the patient to respond to solar exposure with melanogenesis was very limited, and massive daily solar exposure from late spring throughout the summer could only induce a skin pigmentation similar to the Danish mean of unexposed buttock skin. Waismann (1) observed that most of his patients were blue-eyed. A large



study comprising 68 patients from Hawaii showed that most patients had skin type III and only half of them had blue eyes (2). The skin type may be of importance anyway, and the occurrence of pruritus may depend both on exposure dose and skin complexion.

The nature of this itch is similar to PUVA-induced pruritus where UV-induced neuropathy is suspected (8). The features of polymorphic light eruption sine eruptione (PLESE) have also been compared with those of solar pruritus (9). However, in PLESE there is no xerosis or excoriation, and the onset of the condition is often in early childhood (9). Finally, psychogenic pruritus is a differential diagnosis, but our patient did not appear to be altered mentally, or especially interested in the disease.

Patients with solar pruritus may be treated with protection of the affected area against further solar exposure and treatment with capsaicin cream (3, 4). Our patient improved a couple of weeks after initiation of therapy with capsaicin cream. However, it is impossible to determine if it was the capsaicin cream, the discontinued solar exposure, or both that stopped the pruritus.

Solar pruritus is common in residents of the tropics and subtropics (2). The cause of solar pruritus remains unknown, but circumstantial evidence implicates chronic solar exposure (2). The condition is at present seldom seen in temperate

regions and has only been reported once before outside the tropics and subtropics (10). This report is to our knowledge the first to describe this condition in northern Europe.

#### REFERENCES

1. Waismann M. Solar pruritus of the elbows (brachioradial summer pruritus). *Arch Dermatol* 1968; 68: 481-485.
2. Knight TE. Solar (brachioradial) pruritus-response to capsaicin cream. *Int J Dermatol* 1994; 33: 206-209.
3. Walczyk PJ, Elpern DJ. Brachioradial pruritus: a tropical dermatopathy. *Br J Dermatol* 1986; 115: 177-180.
4. Goodless DR, Eaglstein WH. Brachioradial pruritus: treatment with topical capsaicin. *J Am Acad Dermatol* 1993; 29: 783-784.
5. Bech-Thomsen N, Angelo HA, Wulf HC. Skin pigmentation as a predictor of minimal phototoxic dose after oral methoxalen. *Arch Dermatol* 1994; 130: 464-468.
6. Hölzle E. Pigmented lesions as a sign of photodamage. *Br J Dermatol* 1992; 127, Suppl 41: 48-50.
7. Fitzpatrick TB. The validity and practicality of sun-reactive skin types I through VI. *Arch Dermatol* 1988; 124: 869-871.
8. Roelandts RS, Stevens A. PUVA-induced itching and skin pain. *Photodermatol Photoimmunol Photomed* 1990; 7: 141-142.
9. Dover JS, Hawk JLM. Polymorphic light eruption sine eruptione. *Br J Dermatol* 1988; 118: 73-76.
10. Kestenbaum T, Kalivas J. Solar pruritus. *Arch Dermatol* 1979; 115: 1368.



## Contact Allergy to Topical Corticosteroids and Systemic Contact Dermatitis from Prednisolone with Tolerance of Triamcinolone

ANDREAS J. BIRCHER<sup>1</sup>, FRANCIS LEVY<sup>1</sup>, SABINE LANGAUER<sup>1</sup> and JEAN-PIERRE LEPOITTEVIN<sup>2</sup>

<sup>1</sup>Allergy Unit, Department of Dermatology, University Hospital, Basel, Switzerland and <sup>2</sup>Laboratoire de Dermatologie, Clinique Dermatologique, Strasbourg, France

**We report the case of a 27-year-old female who had an allergic contact dermatitis to topical corticosteroids belonging to the corticosteroid groups A and D. Upon oral treatment with prednisolone a disseminated exanthema began within 24 h. Patch tests revealed sensitization to corticosteroids of group A, C and D, including prednisolone-21-acetate and betamethasone valerate, but not of group B corticosteroids such as triamcinolone. After intradermal testing of corticosteroids the exanthema flared again and the patient was treated with oral triamcinolone, with rapid improvement of her symptoms. A literature review revealed that exanthematous reactions after systemic treatment with corticosteroids have been rarely reported. Since corticosteroids are essential emergency drugs, a safe corticosteroid should be identified for such patients. Patch and intradermal tests may be used for that purpose. Key words: patch test; lymphocyte transformation test; cross-reactivity.**

(Accepted June 19, 1995.)

Acta Derm Venereol (Stockh) 1995; 75:490–493.

A. J. Bircher, Allergy Unit, Department of Dermatology, University Hospital, Petersgraben 4, CH-4031 Basel, Switzerland.

In the last decade contact hypersensitivity to corticosteroids has been found to be a problem of considerable clinical relevance. Reported prevalences of positive patch tests to corticosteroids range from 0.2 to 5% (1–4). Particularly patients suffering from allergic contact dermatitis after topical use have been observed. In addition, a few patients with exacerbation of local dermatitis or systemic immediate type or generalized delayed type hypersensitivity after systemic application of corticosteroids have been reported (3, 5, 6). For the diagnosis of delayed type hypersensitivity reactions, patch and intradermal tests have been used.

Based on patch test results cross-reactivity between different corticosteroids has been supposed, and based on the substitution of the D ring four groups (A–D) of structurally related corticosteroids have been suggested (7). Statistical analysis of patch test results and conformational analysis of the electronic shape of the molecules have confirmed correlations in between the members of groups A, B and D (8). We report on a patient who suffered initially from an allergic contact dermatitis to topical corticosteroids and then from a generalized exanthema to oral prednisolone. Skin tests made it possible to identify a safe corticosteroid. Similar cases from the literature are reviewed.

### CASE REPORT

A 27-year-old woman developed a facial dermatitis after application of a cosmetic cream. Despite a 3-day treatment with topical prednisolone-21-acetate (Hexacorton<sup>®</sup> cream), the symptoms increased. The treatment was changed to betamethasone valerate (Betnovate<sup>®</sup> cream) but her dermatitis further deteriorated. Finally she was given oral

prednisolone 40 mg/day. Twenty-four hours later she felt generally sick and developed oral enanthema, angioedema of the face, erythematous patches of the great folds, and maculopapular exanthema of the trunk. Oral antihistamines (terfenadine and clemastine) and intramuscular tetracosactid (Synacthen<sup>®</sup>=synthetic ACTH) were given, and symptoms improved markedly within a week.

She had a history of asthma, flexural eczema and contact allergy to jewellery. Earlier treatments with inhaled budesonide and several topical corticosteroids, including betamethasone valerate, prednisolone acetate and triamcinolone acetonide, had been tolerated. Skin prick tests were positive to grass and rye pollens. Two months after the incidence patch tests were performed with a standard series, a preservative series including the preservatives benzyl alcohol, butylhydroxyanisole, chlorhexidine, chlorocresol and triclosan, contained in the respective corticosteroids, and a corticosteroid series (Table I). She had positive results to nickel, palladium chloride and colophony. The results of the corticosteroid series are shown in Table I. In order to exclude an immediate hypersensitivity reaction intradermal tests with hydrocortisone succinate (Solu-Cortef<sup>®</sup>, 10 mg/ml), prednisolone hemisuccinate (Solu-Dacortin<sup>®</sup>, 2.5 mg/ml), methylprednisolone succinate (Solu-Medrol<sup>®</sup>, 4 mg/ml) and triamcinolone acetonide (Kenakort A<sup>®</sup>, 1 mg/ml) were performed. As positive control histamine hydrochloride 0.1 mg/ml and as negative control the diluent 0.9% NaCl were employed. The tests with the corticosteroids were negative in 2 controls who had been treated with systemic corticosteroids. A wheal and flare reaction was present at 20 min to the three former substances. Eight hours later generalized pruritus and a flare-up of the facial and flexural dermatitis began. After 24 h a generalized maculopapular exanthema was present and the three earlier positive skin test sites were infiltrated. A biopsy of the skin tests was denied. Based on the skin test results oral triamcinolone (12 mg per day) was given, which resulted in a rapid improvement of symptoms. A lymphocyte transformation test (9) with methylprednisolone acetate, methylprednisolone succinate and triamcinolone acetonide was negative.

### DISCUSSION

Contact allergy to topical corticosteroids is now a frequent problem, whereas immediate type hypersensitivity and generalized delayed type hypersensitivity reactions upon local (10, 11) or systemic application of corticosteroids are rare (3, 5, 6). We found more than 25 patients reported in the literature who had delayed, generalized exanthematous reactions to oral or parenteral corticosteroids. The clinical signs most often observed were maculopapular exanthemas, generalized erythema or widespread eczema. In cases of oral administration, most often prednisolone and its derivatives (12–25) or prednisone (26–29) were involved. Only rarely were oral betamethasone and its derivatives (24, 30), dexamethasone (30), triamcinolone (19), and hydrocortisone (24, 25) the causing agents. Five patients reacted to both oral and parenteral administration (22, 24, 26, 29), and several patients with exanthematous reactions to parenteral corticosteroids such as prednisolone and its derivatives (14, 29, 31–35), and dexamethasone (11) have been reported. With some exceptions (13, 28) these patients have been diagnosed by patch or intradermal tests with the respective corticosteroids. More