

Psoriasis and Hepatitis C Virus

TOSHIYUKI YAMAMOTO, ICHIRO KATAYAMA and KIYOSHI NISHIOKA

Department of Dermatology, Tokyo Medical and Dental University, School of Medicine, Tokyo, Japan

We have analyzed 8 patients (6 men and 2 women, aged 52 to 70 years) with psoriasis associated with hepatitis C virus (HCV) infection among 79 psoriatic patients. Psoriasis preceded in 6 cases. One patient had generalized pustular psoriasis (GPP), and the others had psoriasis vulgaris (PV). The psoriasis area and severity index (PASI) score ranged from 2.7 to 32.4. Two of the patients were treated with interferon- γ . Anti-HCV antibodies were detected in all cases by second generation enzyme-linked immunosorbent and recombinant immunoblot assay. HCV messenger RNA was demonstrated by reverse transcriptase polymerase chain reaction in the tissue sections of the lesions of 1 of the patients with PV and the patient with GPP, providing evidence for active viral replication in the skin lesion. HCV-related chronic active hepatitis might cause several immunological abnormalities. It is suggested that this infection might be one of the triggering factors of psoriasis. *Key word: HCV mRNA.*

(Accepted May 8, 1995.)

Acta Derm Venereol (Stockh) 1995; 75: 482-483.

T. Yamamoto, Department of Dermatology, Tokyo Medical and Dental University, School of Medicine, 5-45, Yushima 1-chome, Bunkyo-ku, Tokyo, Japan.

Psoriasis has recently been suggested to be one of the immunological skin diseases in which a variety of cytokines released from keratinocytes and inflammatory cells contribute to the induction and persistence of the inflammatory process. An association of immune complexes, cryoglobulinemia, or low complement level and vasculitis has been demonstrated in several patients infected with hepatitis C virus (HCV) (1-4). Lichen planus has also been suggested to be related to HCV infection (5-8). We have studied 8 patients with the combination of psoriasis and HCV infection.

MATERIAL AND METHODS

Patients

Seventy-nine psoriatic patients at our out-patient clinic were enrolled. Eight patients with psoriasis and chronic type C hepatitis were examined. They consisted of 6 men and 2 women, with a mean age of 63 years (age range 52-70 years). The diagnosis of psoriasis was based on clinical and histopathological findings. One had generalized pustular psoriasis (GPP) and the others had psoriasis vulgaris (PV). The psoriasis area and severity index (PASI) score of each patient was determined according to the method described by Frederiksson & Pettersson (9). Anti-HCV antibodies were detected by second-generation enzyme-linked immunosorbent assay (ELISA) and recombinant immunoblot assay (RIBA) (MBL Co. Ltd., Tokyo, Japan). Liver biopsies were not performed.

RT-PCR

Total RNA was extracted from fifty 5- μ m frozen tissue sections of the lesions of 5 patients with PV and the patient with GPP using RNAzol (Biotex CS 101), and then reversely transcribed to cDNA by RAV-2 reverse transcriptase (Takara 2610B). PCR analysis of HCV was accompanied by using oligonucleotide primers specific for HCV (5'-ACTCCACCATAGATCATCCC-3' and 5'AACACTACTCGGCTAGCAGT-3') (10) for 40 cycles. PCR products were electrophoresed in 1% agarose gel. The gel was stained with 1% ethidium bromide and visualized under ultraviolet light.

RESULTS

The results of the clinical and laboratory findings are summarized in Tables I and II. Liver cirrhosis was detected in 3 cases. The 8 patients presented PASI scores ranging from 2.7 to 32.4. Lichen planus was found in 1 patient and purpura in 2 patients. Positive anti-nuclear antibody was noted in 2 patients and positive rheumatoid factor in 4 patients. Cryoglobulinemia was noted in 3 patients. Chronic hepatitis C was treated with interferon- γ in 2 patients, without exacerbation of psoriasis. Anti-HCV antibodies were detected in all the patients by ELISA and RIBA assay. HCV mRNA was detected by means of RT-PCR in

Table I. Results of clinical and laboratory findings

Patient No/ Age/Sex	Psoriasis/ Skin eruption	PASI score	ANA	RA/ RAHA	Cryc- globulin	IgG (1025-2070 mg/dl)	Complement			IFN treatment
							C 3	C 4	CH 50	
1/64/M	PV/Lichen Planus	8.7	$\times 40$	-/ < 40	+	2351	\downarrow	\downarrow	\downarrow	-
2/65/M	PV	13.5	-	-/ $\times 40$	ND	2255	\downarrow	\downarrow	\downarrow	-
3/57/F	PV	2.7	-	2+/ $\times 80$	ND	1698		ND		IFN
4/68/M	PV/Purpura	4.2	-	2+/ $\times 80$	-	3292		w. n. l		-
5/70/F	GPP	32.4	-	-/ < 40	+	2352	w. n. l		\downarrow	-
6/59/M	PV	26.0	$\times 40$	2+/ $\times 80$	+	2318		w. n. l		-
7/52/M	PV	7.5	-	ND	-	ND		ND		-
8/68/M	PV/Purpura	10.2	-	2+/ < 40	-	1728		w. n. l		IFN

PV = Psoriasis vulgaris, GPP = Generalized pustular psoriasis, ND = Not done, PA = RA latex test, RAHA = Rheumatoid arthritis hemagglutination test, w. n. l = within normal limit, IFN = Interferon

Table II. Results of laboratory findings

Patient No/ Age/Sex	LDH (269–467 U/l)	GOT (10–34 U/l)	GPT (5–46 U/l)	γ-GTP (M 8–61 U/dl) (F 5–24 U/dl)	Al-P (M 102–249 U/dl) (F 82–211 U/dl)	TTT (0–5 U)	ZTT (3–14 U)
1/64/M	527	93	55	39	209	ND	ND
2/65/M	540	178	291	141	267	11.2	22.4
3/57/F	544	126	214	150	138	ND	ND
4/68/M	417	95	91	99	333	ND	ND
5/70/F	732	73	41	27	375	6.8	19.1
6/59/M	692	279	276	299	489	6.8	16.2
7/52/M	562	130	106	45	239	ND	ND
8/68/M	423	31	30	53	299	ND	ND

the skin sample from 1 of the 5 patients with PV and the patient with GPP, providing active viral replication (Fig. 1).

DISCUSSION

Eight cases of psoriasis associated with HCV-related chronic active hepatitis were analyzed. The diagnosis of psoriasis was preceded by that of HCV in 6 cases.

Psoriasis has recently been suggested to be one of the immunological skin diseases in which a variety of cytokines released from keratinocytes and inflammatory cells contribute to the induction and persistence of the inflammatory process. HCV was recently isolated from a chimpanzee chronically infected with a contaminated human factor VIII concentrate (11). A high prevalence of immunological abnormalities has been reported in patients with chronic HCV infection. A link between lichen planus and HCV has been reported (5–8). Urticaria, erythema nodosum or purpura have also been reported in association with HCV infection (12–13).

In our study, the presence of mRNA for HCV in the lesion of psoriasis may suggest that HCV is one of the triggering causes

of psoriasis. Further studies are needed to clarify the induction of psoriasis.

REFERENCES

- Durand JM, Lefevre P, Harle JR, Boucrat J, Vitvitski L, Soubeyrand J. Cutaneous vasculitis and cryoglobulinaemia type associated with hepatitis C virus infection. *Lancet* 1991; 337: 499–500.
- Hearth-Holmes M, Zahardka SL, Baethge BA, Wolf RE. Leucocytoclastic vasculitis associated with hepatitis C. *Am J Med* 1991; 90: 765–766.
- Pascual M, Perrin L, Giostra E, Schifferli JA. Hepatitis C virus in patients with cryoglobulinemia type II. *J Infect Dis* 1990; 162: 569–570.
- Ferri C, Greco F, Longombardo G, Palla P, Moretti A, Marzo E, et al. Antibodies to hepatitis C virus in patients with mixed cryoglobulinemia. *Arthritis Rheum* 1991; 34: 1606–1610.
- Mokni M, Rybojad M, Puppini D Jr, Catala S, Venezia F, Djian R, et al. Lichen planus and hepatitis C virus. *J Am Acad Dermatol* 1991; 24: 792.
- Doutre MS, Beylot C, Couzigou P, Long P, Royer P, Beylot J. Lichen planus and virus C hepatitis: disappearance of the lichen under interferon alfa therapy. *Dermatology* 1992; 184: 229.
- Divano MC, Parodi A, Rebori A. Lichen planus, liver kidney microsomal (LKM1) antibodies and hepatitis C virus antibodies. *Dermatology* 1992; 185: 132–133.
- Jubert C, Pawlotsky JM, Pouget F, Andre C, DeForges L, Bretagne S, et al. Lichen planus and hepatitis C virus-related chronic active hepatitis. *Arch Dermatol* 1994; 130: 73–76.
- Fredriksson T, Petterson U. Severe psoriasis: oral therapy with a new retinoid. *Dermatologica* 1978; 21: 511–525.
- Okamoto H, Okada S, Sugiyama Y, Totsumoto S, Tanaka T, Yoshizawa H, et al. The 5'-terminal sequence of the hepatitis C virus genome. *Jpn J Exp Med* 1990; 60: 167–177.
- Choo QL, Kuo G, Weiner A, Overby LR, Bradley DW, Houghton M. Isolation of a cDNA clone derived from a blood-borne non-A, non-B viral hepatitis genome. *Science* 1989; 244: 359–362.
- Reichel M, Mauro TM. Urticaria and hepatitis C. *Lancet* 1990; 336: 822–823.
- Domingo P, Ris J, Martinez E, Casas F. Erythema nodosum and hepatitis C. *Lancet* 1990; 336: 1377.

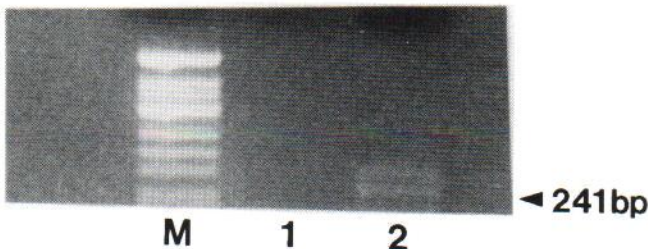


Fig. 1. Detection of PCR-amplified products showing base pairs (bp) encoding HCV on lesional psoriatic skin. M: marker. Lane 1: patient with psoriasis vulgaris showing negative finding; Lane 2: patient with generalized pustular psoriasis showing positive finding.