

Quantitative Description of Echographic Images of Morphea Plaques as Assessed by Computerized Image Analysis on 20 MHz B-scan recordings

STEFANIA SEIDENARI, ANDREA CONTI, PATRIZIA PEPE and ALBERTO GIANNETTI

Department of Dermatology, University of Modena, Modena, Italy

In order to find image descriptors enabling the characterization of sclerotic skin of morphea plaques and their objective differentiation from normal skin, we studied 52 lesions in 35 patients affected by plaque type morphea. Echographic evaluations were carried out using a 20 MHz B-scanner, providing cross-sectional images of the skin. Images were processed by a program providing a numerical representation of the picture data, based on the following parameters, which were considered for 7 different amplitude intervals: 1) the extension of image areas marked by amplitude bands of interest, 2) the percentage of the image surface reflecting within a homogeneous amplitude band, 3) the number of objects composing the image, 4) the average object size, and 5) the "density" of the objects. For all parameters considered, marked differences between sclerotic skin and normal tissue were observable. When assessment is performed with amplitude bands covering the lower part of the scale, the image referring to sclerotic tissue appears relatively homogeneous with few, large objects within a thickened skin block, which occupy a more extended image surface in comparison to images of normal skin, characterized by spots, which are small and closely packed. On the contrary, binary images of morphea plaques transformed by intermediate to high amplitude intervals appear with fewer objects of approximately the same size or smaller, which are less compressed in respect to healthy skin images. *Key words: localized scleroderma; ultrasound; image analysis.*

(Accepted May 2, 1995.)

Acta Derm Venereol (Stockh) 1995; 75: 442–445.

S. Seidenari, Department of Dermatology, University of Modena, via del Pozzo 71, I-41100 Modena, Italy.

Diagnosis of localized scleroderma is generally performed on the basis of clinical examination or on histological findings. As a supplement to subjective evaluation, non-invasive skin thickness determination has been employed for characterizing morphea plaques and monitoring the course of the disease (1–3).

The recently developed high-resolution 20 MHz B-mode ultrasound scanners, providing cross-sectional imaging of the skin, also enable morphological information, which can be related to histopathological aspects of skin diseases (4). In a study on 34 patients with localized scleroderma, Hoffmann et al. (3) reported enhanced reflexes in the lower corium and hyper-echoic, widened bands of connective tissue traversing the subcutaneous fatty tissue from the corium-subcutis border in the direction of the muscle fascia, as characteristic aspects of sclerotic skin.

However, the subjective description of the echographic features of morphea plaques does not provide an unambiguous

comparison between contemporary or consecutive recordings, representing the basis for follow-up studies.

As a digitalized image, an echographic picture is a visual representation of arrays of numbers, each picture element representing the amount of reflected ultrasound. Intuitive information obtained by looking at an echographic image can be turned into an objective diagnostic tool by means of image processing procedures, which achieve the numerical description of the image, the quantification of the echographic data and their statistical elaboration (5). It has been demonstrated that processing of B-scan images allows the characterization of the cutaneous echostructure according to skin site, age and sex, the objective evaluation and the quantification of the intensity of allergic and irritant reactions and an assessment of the response to therapy in inflammatory skin diseases (6–12).

The aim of our study was to find image descriptors enabling the characterization of sclerotic skin of morphea plaques and its differentiation from normal skin, using processing methods for elaborating 20 MHz B-scan images.

MATERIAL AND METHODS

Patient population

Thirty-five untreated patients with a clinical diagnosis of plaque type scleroderma were studied. The average age of the patients was 37.5 years, and the average duration of the disease was 5.2 years. In each patient 1–2 morphea plaques were considered (total = 52 lesions). Images were recorded on the abdomen (11 cases), the front part of the chest (11 cases), the groin (10 cases), the back (8 cases), the arms (4 cases), the legs (4 cases), the face (2 cases), the hands (1 case) and the buttocks (1 case).

In 40 cases contralateral control measurements of seemingly normal skin were performed. In patients showing symmetrical lesions, ipsilateral measurements of adjacent, apparently normal skin were used as controls.

Ultrasound equipment

Echographic evaluations were carried out using a 20 MHz B-scanner (Dermascan C, Cortex Technology, Denmark), which produces images representing a cross-section of the skin. Equipment and calibration methods have already been described in detail elsewhere (13). Evalua-

Table I. Digital parameters employed for the evaluation of 20 MHz B-scan images of morphea plaques

1. extension of image areas marked by homogeneous amplitude bands (in number of pixels)
2. percentage of the image surface reflecting within a homogeneous amplitude band
3. number of objects composing the image
4. average object size = extension/number of objects
5. density of objects = number of objects/skin thickness

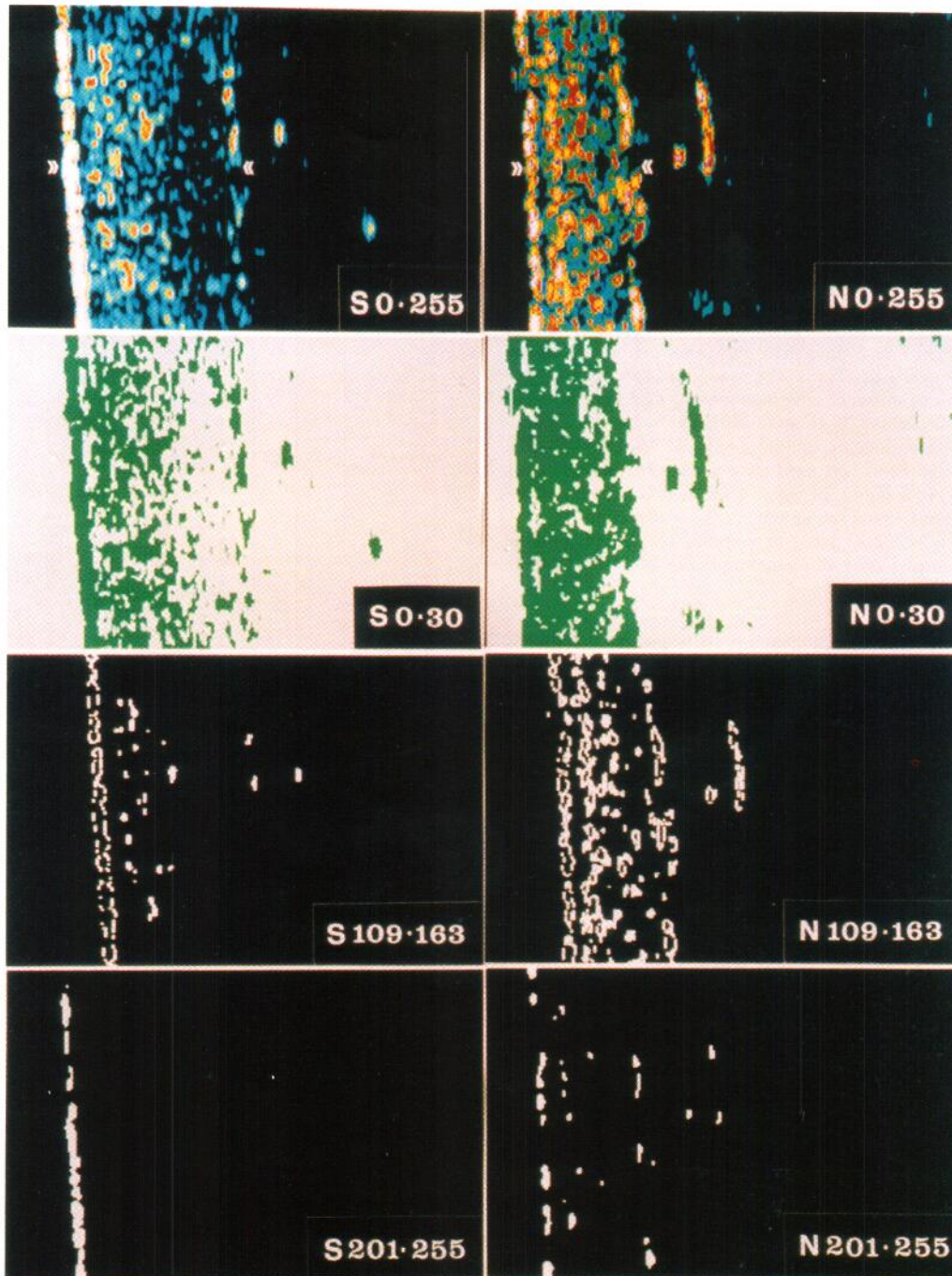


Fig. 1. Echographic images of normal skin (on the right = *N*) and of sclerotic skin (on the left = *S*). *S 0-255* and *N 0-255*: pseudocolor images: the whole amplitude scale is represented; high amplitude values correspond to white, low amplitude values to blue and black. The entrance echo, referring to the epidermis and appearing as a white band, has been marked with \gg ; black areas in the right part of the pictures represent the subcutaneous fatty tissue; the dermis-hypodermis boundary has been marked with \ll . *S 0-30* and *N 0-30*: binary images after selection of a 0-30 band: image areas of interest are marked in green. *S 109-163* and *N 109-163*: binary images after selection of a 109-163 band: image areas of interest are marked in white. The number of objects is easily assessable. *S 201-255* and *N 201-255*: binary images after selection of a 201-255 band: image areas of interest are marked in white.

tions were performed by employing the B-probe assessing a tissue section with a length of 12.13 mm. Skin thickness was assessed in B mode (13).

Software for image analysis

The echographic images were processed by a software, which was developed as a prototype according to our suggestions and is now

commercially available (DermaVision 2D, Cortex Technology). This program enables a numerical representation of the picture data, based on the attribution of fictional values to the amplitudes of the echoes, the possibility of an interactive selection of amplitudes of interest, the segmentation of the image, i.e. the subdivision of the image into areas of uniform appearance, and the calculation of the extension of areas reflecting within the chosen amplitude range (in number of pixels). After segmentation, the program also allows the transformation into a

Table II. Skin thickness values (mm)

	Plaque	Healthy skin
Mean	2.56	1.97
Standard deviation	0.92	0.67
Minimum	1.21	0.69
Maximum	4.81	3.54
Number of observations	52	52

binary image, and the calculation of the number of objects reflecting within the chosen band of interest. Thus, a picture can be transformed on the screen into an image, in which only meaningful regions are enhanced and numerically described. The sonographic recordings were evaluated by means of different amplitude bands, marking the hypo-reflecting parts of the dermis (0–10 and 0–30), and by intervals identifying intermediate to high echoamplitudes (31–75, 76–126, 127–255, 109–163). A 201–255 band was used for evaluating hyper-reflecting dermal structures. As a region of interest the whole skin block appearing on the screen without the entrance echo was chosen.

For characterizing sclerotic tissue of morphea plaques, 5 different parameters were considered for different amplitude intervals (Table I).

Statistics

Each area of sclerotic skin was compared to its respective control site (contralateral or surrounding skin). Differences were analyzed by Student's *t*-test for paired values. Correlations between thickness values of healthy skin and of morphea plaques were calculated according to Pearson.

RESULTS

Fig. 1 represents the echographic images of normal skin and of sclerotic skin of a morphea plaque in the same patient.

Skin thickness measurement. The results of skin thickness measurements appear from Table II. The skin thickness of the sclerotic area is more pronounced compared to the contralateral area of healthy skin or the surrounding skin. The percentage increase in corium thickness varies from 0 to 54%; however, the correlation between the thickness of healthy skin and the corresponding value of sclerotic skin is high ($r=0.8410$).

Results of image elaborations are presented in Table III.

0–10 band elaboration. In respect to apparently normal skin, at sclerotic skin sites a significant increase of the values of all 5 parameters can be observed.

0–30 band elaboration. In respect to healthy skin, images of sclerotic skin areas show a significant absolute and relative increase in the extension of hypo-reflecting dermal areas, with fewer objects which are greater in size. Referring the number of objects to skin thickness values, the ratio is lower for sclerotic skin pictures. Differences between objects of normal skin and those of sclerotic skin are significant for number, size and "density".

31–75 band elaboration. 31–75 values of normal and sclerotic skin differ significantly only in the relative extension of areas (% of image area) covered by this amplitude interval and in the "density" of objects (data not shown).

76–126, 109–163 and 127–255 band elaborations. In respect to control measurements, absolute and relative extension of areas reflecting within these bands is lower at morphea plaques; objects are fewer, but smaller in size, whereas "density" values are lower. Differences are statistically significant.

Table III. Image processing of echographic pictures of sclerotic skin of morphea plaques and of normal skin (52 lesions in 35 subjects) by means of different amplitude bands of interest

Amplitude band of interest	0–10		0–30		76–126		109–163		127–255		201–255	
	N	M	N	M	N	M	N	M	N	M	N	M
Area extension	3274.15 (4059.71)	13995.98* (11785.31)	13912.37 (9584.64)	35470.44* (17152.47)	9530.00 (3140.23)	4163.69* (2350.82)	4394.19 (2081.87)	1165.96* (882.47)	3656.81 (2341.54)	728.92* (764.92)	538.42 (616.69)	88.67* (164.63)
Area %	6.39 (7.25)	21.68* (15.39)	27.54 (14.62)	56.41* (17.20)	21.36 (7.45)	7.74* (5.02)	10.21 (5.43)	2.28* (2.16)	8.89 (6.83)	1.71* (2.21)	1.42 (2.01)	0.18* (0.36)
Object number	93.35 (66.91)	150.13* (53.35)	130.81 (64.97)	60.25* (45.73)	207.44 (91.11)	110.52* (65.25)	136.02 (71.26)	45.83* (39.20)	59.15 (32.76)	19.77* (17.93)	14.46 (11.59)	2.88* (4.57)
Object size	36.27 (43.81)	109.63* (133.41)	305.35 (941.15)	2798.10* (6998.17)	49.70 (16.38)	38.21* (13.09)	33.70 (10.26)	26.01* (10.22)	83.99 (148.50)	35.42* (28.52)	33.13 (24.31)	31.36 (24.93)
Object density	44.65 (23.33)	61.48* (18.76)	67.47 (27.77)	25.41* (17.84)	110.87 (52.35)	46.23* (25.89)	75.76 (51.40)	19.01* (15.77)	31.17 (16.11)	8.18* (6.96)	8.61 (9.11)	1.14* (1.73)

Values are expressed as mean ± (s.d.). N = normal skin; M = sclerotic skin. * = statistically significant ($p < 0.05$).

201–255 band elaboration. At sclerotic skin sites, absolute and relative extension of 201–255 areas, and number and “density” of 201–255 objects are significantly lower in respect to normal skin, whereas object size appears unchanged.

DISCUSSION

Ultrasound examination has so far been used to determine the thickness of sclerotic skin both in morphea and in progressive systemic sclerosis (1–3, 14–16). Lesions in the patients with plaque-type localized scleroderma were found to show an increase in skin thickness between 2 and 310%, originally thin skin showing a greater degree of sclerosis than the comparatively thicker skin (1, 3). Regarding our measurements, we observed a skin thickening between 0 and 54%, and a high correlation between thickness of healthy skin and corresponding values of sclerotic skin, with a more homogeneous distribution of skin thickening, the entity of which was not connected with the site of the disease.

B-mode scanning, providing a two-dimensional image, permits clear identification of physiological and pathological skin structures and assignment of the ultrasound phenomena to histological features.

Processing of 20 MHz B-scan images improves the recognition of attributes corresponding to tissue structures or evolutive phases of processes to be studied and provides numerical image descriptors, which can be used to objectively characterize the echostructure of the tissue in inflammatory skin diseases (5–12). In this study we also showed that image analysis represents a descriptive procedure enabling the objective differentiation between morphea plaques and normal skin, by using five different parameters. Extension and percentage of areas of interest describe the area in the picture marked by a certain amplitude level; the number of objects and their size describe the distribution of certain amplitude bands, whereby a small number of large objects signifies a relatively homogeneous picture with large or confluent image areas, while few, small objects characterize a picture consisting of little spots with an unhomogeneous distribution. By referring the number of objects to skin thickness, information about the distance between the different objects can be obtained.

At morphea plaque sites, absolute and relative extension of image areas are increased, when evaluating with 0–10 and 0–30 amplitude intervals; slight changes are observed with the 31–75 band, whereas a decrease is shown for intermediate to high amplitude intervals. Most images of scleroderma plaques were devoid of hyper-reflecting (201–255) areas. Thus, we were not able to confirm other authors' description of enhanced reflexes in the lower corium, which, however, could be characteristic of sclerotic tissue at particular skin sites.

Regarding the characteristics of the objects, their number decreased when evaluating by amplitude values between 10 and 255, whereas their size increased when considering low-reflecting bands and was reduced for intermediate to high amplitude intervals. Thus, when assessing with bands covering the lower part of the scale, the image referring to sclerotic tissue appears comparatively homogeneous with few, large objects

within a thickened skin block, which occupy a more extended image surface in comparison to images of normal skin, characterized by spots, which are small, closely packed and unhomogeneously distributed. On the contrary, binary images of morphea plaques transformed by intermediate to high amplitude intervals appear with fewer objects of approximately the same size or smaller, which are less compressed in respect to healthy skin images.

In conclusion, image processing of 20 MHz B-scan recordings provides parameters for the characterization and numerical description of morphea plaques and for their differentiation from normal skin, as a first step towards an objective assessment of the spontaneous course of the disease and of response to therapy.

REFERENCES

1. Serup J. Localized scleroderma (morphoea): thickness of sclerotic plaques as measured by 15 MHz pulsed ultrasound. *Acta Derm Venereol (Stockh)* 1984; 64: 214–219.
2. Serup J. Assessment of epidermal atrophy in localized scleroderma (morphea). *Dermatologica* 1986; 172: 205–208.
3. Hoffmann K, Gerbaulet U, el-Gammal S, Altmeyer P. 20-MHz B-mode ultrasound in monitoring the course of localized scleroderma (morphea). *Acta Derm Venereol (Stockh)* 1991; Suppl. 164: 3–16.
4. Altmeyer P, el-Gammal S, Hoffmann K, eds. *Ultrasound in dermatology*. Berlin, Heidelberg: Springer Verlag, 1992.
5. Gonzalez RC, Wintz P, eds. *Digital image processing*. 2nd edn. USA: Addison-Wesley Publishing Company, 1987.
6. Seidenari S, Di Nardo A. B scanning evaluation of allergic reactions with binary transformation and image analysis. *Acta Derm Venereol (Stockh)* 1992; Suppl. 175: 3–7.
7. Seidenari S, Di Nardo A. B scanning evaluation of irritant reactions with binary transformation and image analysis. *Acta Derm Venereol (Stockh)* 1992; Suppl. 175: 9–13.
8. Di Nardo A, Seidenari S, Giannetti A. B-scanning evaluation with image analysis of psoriatic skin. *Exp Dermatol* 1992; 1: 121–125.
9. Seidenari S, Di Nardo A, Giannetti A. Assessment of topical corticosteroid activity on experimentally induced contact dermatitis: echographic evaluation with binary transformation and image analysis. *Skin Pharmacol* 1993; 6: 85–91.
10. Seidenari S. Echographic evaluation with image analysis of irritant reactions induced by nonanoic acid and hydrochloric acid. *Contact Dermatitis* 1994; 31: 146–150.
11. Seidenari S. Reactivity to nickel sulfate at sodium lauryl sulfate pre-treated skin sites is higher in atopics: an echographic evaluation by means of image analysis performed on 20 MHz B-scan recordings. *Acta Derm Venereol (Stockh)* 1994; 74: 245–249.
12. Seidenari S, Pagnoni A, Di Nardo A, Giannetti A. Echographic evaluation with image analysis of normal skin: variations according to age and sex. *Skin Pharmacol* 1994; 7: 201–209.
13. Seidenari S, Di Nardo S, Pepe P, Giannetti A. Ultrasound B scanning with image analysis for assessment of allergic patch test reactions. *Contact Dermatitis* 1991; 24: 216–222.
14. Serup J. Quantification of acrosclerosis: measurement of skin thickness and of skin-phalanx distance in females with 15 MHz pulsed ultrasound. *Acta Derm Venereol (Stockh)* 1984; 64: 35–40.
15. Åkesson A, Forsberg L, Hederström E, Wollheim F. Ultrasound examination of skin thickness in patients with progressive systemic sclerosis (scleroderma). *Acta Radiol Diagnosis* 1986; 27: 91–94.
16. Myers SL, Cohen JS, Sheets PW, Bies JR. B-mode ultrasound evaluation of skin thickness in progressive systemic sclerosis. *J Rheumatol* 1986; 13: 577–580.