

Successful Treatment of Papillomatosis Cutis Lymphostatica with Acitretin

Sir,

Papillomatosis cutis lymphostatica is a chronic hyperproliferative verrucous skin disorder, localized on lower legs or feet. It is caused by chronic lymphatic congestion and relapsing infections. We have recently treated a 53-year-old man suffering from this disorder with acitretin.

CASE REPORT

A 53-year-old man presented with a 12-year history of papillomatosis cutis lymphostatica complicated by ulceration. Chronic oedema due to venous insufficiency and venous thrombosis, lymphoedema and relapsing erysipelas had been present for many years. The medical history revealed long-standing obesity (body weight 160–200 kg). He suffered from hypertension, with right- and left-sided heart failure. His medication at the time consisted of captopril 25 mg bid and furosemide 80 mg once daily.

On examination, brownish grey discolouration with indurated skin areas, verrucous hyperkeratoses and desquamation were observed on both lower legs. At the pretibial parts of the lower legs ulcerations were observed; these were surrounded by a fiercely red erythema and oozing because of lymph leakage. Both lower legs showed a non-pitting oedema. Peripheral arterial pulses were palpable. On physical examination we saw a severely overweight middle-aged man, not in acute distress, with a body weight of 190 kg and 176 cm height, and a blood pressure of 170/95 mm mercury. Laboratory examination – clinical chemistry, haematology and urinalysis – showed no abnormality apart from a creatinine of 120 micromol/l.

The treatment started with a dosage of 60 mg once daily. The patient was immobilized completely and compression of the legs commenced. Within 7 weeks the ulcers and the papillomatosis cutis had disappeared completely. A compressing hosiery (class 4) was applied as maintenance treatment of the oedema. Acitretin was continued for 15 months. Four weeks after cessation of acitretin a new traumatic ulcer appeared on the left leg. It healed within 4 weeks. The papillomatosis cutis had not relapsed. Acitretin treatment was without side-effects.

DISCUSSION

The pathogenesis of papillomatosis cutis involves cutaneous inflammation, epidermal proliferation and abnormal keratinization (1–4). The lymphatic disorder which underlies the cutaneous response can be visualized and diagnosed with a non-directive lymphogram. Such an examination reveals pathologically widened lymphatics with valvular insufficiency (5).

The classical therapeutical approach consists of decongestion therapy, using compression bandages and/or a decompression pump. Superinfections are treated with antibiotics (6). Topical treatment with urea-containing keratolytics improves the hyperkeratotic aspect of the papillomatosis (7).

The present case demonstrates the remarkable therapeutical potential of acitretin for this condition. Within 2 months of treatment with acitretin, the severe expression of papillomatosis cutis lymphostatica with ulcerations remitted to a normal skin appearance. This excellent condition was maintained during 15 months' maintenance treatment with acitretin. So far, i.e. 7 months after discontinuation of acitretin treatment, no relapse of the papillomatosis has been observed.

It is feasible that acitretin interferes with papillomatosis cutis lymphostatica by modulating proliferation and differentiation characteristics. Indeed, it has been well established that acitretin inhibits epidermal proliferation and terminal differentiation and modulates various aspects of cutaneous inflammation (8–10).

So far this communication is the first report on the therapeutical effect of acitretin in papillomatosis cutis lymphostatica. Further studies on patient groups are required to substantiate the position of acitretin as treatment for this condition.

REFERENCES

1. Stöberl Ch, Partsch H. Lymphostatische Stauungspapillomatose. *Hautarzt* 1988; 39: 441–446.
2. Balda B, Kilhelm K. Verruca vulgaris gigantea unter dem Bilde einer Papillomatosis cutis carcinoides. *Hautarzt* 1970; 12: 550–553.
3. Bürgstein A. Elephantiasis und Papillombildung: *Deutsche Zeitschrift für Chirurgie* 1942; 256: 369–376.
4. Zabel R. Behandlungserfolg bei monströser Pachydermia vegetans mit partiellen Periostosen bei Ulcera crurum. *Dermatol Wochenschr Leipzig* 1959; 32: 874–877.
5. Partsch H, Urbanek A, Wenzel-Hora B. The dermal lymphatics in lymphoedema visualized by indirect lymphography. *Br J Dermatol* 1984; 110: 431–438.
6. Michael J, Redmond MD. Mossy leg. An unusual therapeutic success. *Angiology: J Vasc Dis* 1986; 37: 642–646.
7. Lindemayr H. Therapieerfolg mit harnstoffhaltigen Externa bei Papillomatosis cutis verrucosa. *Hautarzt* 1993; 78–79.
8. Kopan R, Traska G, Fuchs E. Retinoids as important regulators of terminal differentiation: examining keratin expression in individual epidermal cells at various stages of keratinization. *J Cell Biol* 1987; 105: 427–440.
9. Ponc M. Retinoids-induced modulation of differentiation, keratin and lipid composition in reconstructed skin. *Basel, Karger*, 1989 vol. 3, 45–51.
10. Orfanos CE, Eklert R, Gallnick H. The retinoids. A review of their clinical pharmacology and therapeutic use. *Drugs* 1987; 34: 459–503.

Accepted April 3, 1995.

A. Feind-Koopmans and P. C. M. van de Kerkhof.
Department of Dermatology, University Hospital Nijmegen, Nijmegen, The Netherlands.

¹Department of Dermatology, Osaka City University Medical School, ²Central Research Center, Osaka University Faculty of Dentistry, ³Department of Pathology, Osaka University Medical School, Osaka and

⁴Department of Biochemistry, Okayama University Dental School, Okayama, Japan.

Isotretinoin-induced Pemphigus

Sir,

A 17-year-old male patient came to us with vesicles, bullae and crusted erosions on his face, trunk, back, arms and legs. The patient also had lesions, typical of cystic acne, on his back.

Due to his cystic acne, the patient was treated initially with HCl-tetracycline and minocycline, but as he had no improvement, he started treatment with isotretinoin at a dosage of 1 mg/kg/day (a total of 90 mg/day was administered). Sixty days after the start of this treatment, blisters began to develop, first on his trunk and then on his face, arms, back and legs. The eruption was asymptomatic. After this we examined the patient. Examination revealed blisters and crusted erosions, widespread with no symptoms. Nikolsky sign was positive. The oral membrane showed no signs of the disease. The patient's general health was excellent.

A skin biopsy specimen showed intraepidermal bullae, severe acantholysis, suprabasal clefts with papillomatous projections of the dermis, typical of pemphigus (Fig. 1). Indirect immunofluorescence studies demonstrated circulating antibodies of IgG class, directed against the intercellular substance, at a titre of 1:160.

The diagnosis of drug-induced pemphigus was made and isotretinoin therapy was discontinued immediately, while treatment with prednisolone, at a dose of 75 mg/day, and azathioprine, at a dose of 200 mg/day, was started. Improvement of skin lesions was obvious within 3 weeks, with signs of healing, while complete recovery was achieved within 3 months.

The improvement of the antibody titre was also rather quick, it was negative about 6 months after the disease had started.

Prednisolone was discontinued gradually over a period of 7 months and azathioprine was administered to the patient, in total, for 9 months.

At a follow-up 52 months after the discontinuance of isotretinoin, the patient was still free of any sign of pemphigus and the antibody titre was negative.

A possible mechanism for the acantholysis in our case could be that retinoids may affect membranes, because of their lipophilic character (1). Our clues for the diagnosis of drug-induced pemphigus have been based on the following: a) the first signs of the bullous disease appeared a short period after the administration of the drug (isotretinoin); b) quick improvement (3rd week) and quick complete resolution (3rd month) of the disease, which is not very common in pemphigus; and c) despite the quick discontinuance of prednisolone and azathioprine, the patient has been free of clinical symptoms for almost 5 years and the titre of the antibodies still remains negative.

REFERENCES

1. Chytil F, Sherman DR. How do retinoids work? *Dermatologica* 1987; 175 (Suppl 1): 8-12.

Accepted March 14, 1995.

Sofia Georgala, M.D., University of Athens, Dimitrios Rigopoulos, M.D., Kalli Gourgiotou, M.D., Eleftheria Christofidou, M.D. "A. Sygros" Hospital, 5, I. Dragoumi, Athens, 116 21, Greece.

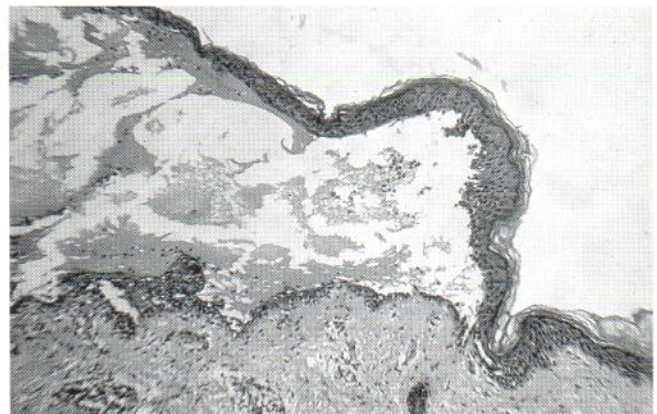


Fig. 1. Light microscopy of skin lesion ($\times 160$).

ANNOUNCEMENTS

British Society for Investigative Dermatology Meeting will be held in Glasgow, United Kingdom on **March 28–29, 1996**. For further information please contact Dr Graham Sharpe, Dept of Dermatology, University of Liverpool, P.O. Box 147, Liverpool L69 3BX, UK. Tel: +44-151 706 4033. Fax: +44-151 706 5842.

The 23rd Annual Meeting of the Society for Cutaneous Ultrastructure Research will be held in Gardone Riviera, Brescia, Italy on **April 11–13, 1996**. For further information please contact Prof G. De Panfilis, Department of Dermatology, Brescia University Hospital, I-25125 Brescia, Italy. Tel: +39-30 3995302/7. Fax: +39-30 3995015/6.

International Symposium on Pediatric Dermatology will be held in Rome, Italy on **April 18–20, 1996**. For further information please contact Professor Giuseppe Fabrizi, Department of Dermatology, Catholic University of Sacred Heart, Largo Gemelli, 8, I-00168 Rome, Italy. Tel: and Fax: +39-6 3013250.

Fourth annual Summit on Cutaneous antifungal Therapy: Update on Management and New Therapy for the Clinician will be held in Vancouver, Canada on **May 26–28, 1996**. For further information please contact The Organizing Secretariat, CCT Healthcare Communication Limited, 50–52 Union Street, London Bridge, London SE1 1TD, UK. Tel: +44-171 407 9731. Fax: +44-171 403 5938.

Clinical Dermatology 2000 Vancouver will be held in Vancouver, Canada on **May 28–31, 1996**. For further information please contact The Organizing Secretariat, CCT Healthcare Communication Limited,

50–52 Union Street, London Bridge, London SE1 1TD, UK. Tel: +44-171 407 9731. Fax: +44-171 403 5938.

17th Colloquium of the International Society of Dermatopathology (ISD) and Swiss Group of Dermatopathology (SGDP) will be held in Zürich, Switzerland on **July 18–20, 1996**. For further information please contact Conference management: Dermatopathology '96, c/o AKM Congress Service, Clarastr. 57, CH-4005 Basel, Switzerland. Tel: +41-61 691 5511. Fax: +41-61 691 8189.

XV. Fortbildungswoche für Praktische Dermatologie und Venereologie 1996 will be held in München, Germany on **July 21–26, 1996**. For further information please contact Prof. Dr Gerd Plewig, Dermatologische Klinik und Poliklinik der Ludwig-Maximilians-Universität München, Frauenlobstr. 9–11, D-80337, München. Tel: +49-89-5160-4600. Fax: +49-89-5160-4527.

11th International Symposium on Bioengineering and the Skin will be held in Zurich, Switzerland on **October 2–5, 1996**. For further information please contact Prof Peter Elsner, Department of Dermatology, Univ Hospital Zürich, Gloriastr. 31, CH-8091 Zürich, Switzerland. Tel: +41-1 255 3305. Fax: +41-1 255 4412.

Fifth Congress of the European Academy of Dermatology will be held in Lisbon, Portugal on **October 13–17, 1996**. For further information please contact Prof A Cabral Ascensão, Clínica Universitária de Dermatologia e Venereologia, Hospital Pulido Valente, Al. Linhas de Torres, P-1700 Lisboa, Portugal.

BOOKS RECEIVED

Patch Testing. Test Concentrations and Vehicles for 3700 Chemicals, 2nd edn, by A. C. de Groot, 1994. 334 pages. ISBN 0-444-81911-8. Hardcover. Price Dfl 290.00, US\$ 165.75. Elsevier Science B. V., Amsterdam.

The first edition of "Patch testing" appeared in 1986 and contained a presentation of 2800 allergens with patch test concentrations, vehicles and references. This book has been a "must" for everybody engaged in patch testing during the past 10 years. Anton C. de Groot is also the co-author of another highly appreciated reference for patch testing: "Unwanted Effects of Cosmetics and Drugs used in Dermatology",

third edn, 1994, by Jan Willem Weyland, John Nater and Anton C. de Groot.

In this second edition of "Patch testing", Anton C de Groot has updated his book to include detailed descriptions of test conditions and references for 3700 allergens. The layout of the text is still as comprehensive as in the first edition and as the content has been updated and includes references up to 1994, the book is strongly recommended to be used by everybody performing patch testing with more than the standard series.

Magnus Lindberg, MD, PhD
Department of Dermatology, University Hospital
Uppsala, Sweden

ERRATUM

R. Baran & C. Perrin: Pseudofibrokeratoma of the nail apparatus with melanocytic pigmentation. Acta Derm Venereol (Stockh) 1994; 74: 449–450.

Table I is incorrect. The correct table is shown here.

Table I. Incidence and interval of melanocytes compared in previous and present studies
PFK: pseudo-fibrokeratoma; max: maximum; min: minimum.

	Normal matrix (Higashi's studies)	Matrix of PFK	Nail bed of PEK
Interval of melanocytes on vertical sections	77,3 to 170,5 μ	90,7 μ (min. 25, max. 150)	112,5 μ (min. 75, max. 125)
Melanocyte incidence			
First cell layer of epithelium		266 \pm 26 mm ²	40 \pm 5 mm ²
Four lower layers of epithelium	334 \pm 98 mm ²	126 \pm 20 mm ²	16 \pm 3 mm ²