

LETTERS TO THE EDITOR

Histopathology of Nail Sarcoidosis

Sir,

Cutaneous lesions are a prominent feature in sarcoidosis, being present in approximately 25% of all cases. One of the more unusual clinical presentations is nail dystrophy. We had the opportunity to study 3 patients with chronic sarcoidosis and nail affection, which proved to be specific in nail biopsy.

CASE REPORTS

Case 1

A 56-year-old Caucasian woman had chronic sarcoidosis characterized by lupus pernio (LP) and arthritis of fingers and toes, nodular lesions on forearms, and lung disease with subcarinal and right mediastinal adenopathies. She had a variety of nail changes including thickening, rugosity, longitudinal ridging, colour changes, splinter haemorrhages, shortening, onychorrhexis, onycholysis, pterygium and subungual hyperkeratosis. Biopsies of a left forearm lesion and the fourth finger nail (lateral-longitudinal) were performed.

Case 2

A 63-year-old woman had chronic sarcoidosis with disseminated subcutaneous nodules, LP of nose and toes, and enlarged bilateral hilar and mediastinal lymph nodes. Onychodystrophy with a longitudinal groove was seen on the big toe (Fig. 1) and discolouring and thickening of toe-nails. A central-longitudinal biopsy of the first right toe nail was performed.

Case 3

An 80-year-old man had LP of fingers and feet, malar areas, nose and ear helix. The toe-nails showed thickening, lateral deviation and brown hue. In both thumbs the nails showed lateral and distal onycholysis, splinter haemorrhages and infiltration of proximal folds. A biopsy punch of the matrix just beyond the proximal nail fold was done.

Laboratory

A raised ACE (case 1:62 U/l, case 2:88 U/l, case 3:98 U/l) and urine calcium (case 1: 340 mg/24 h, case 3: 244 mg/24 hs) were contributory. The tuberculin test was negative. X-ray films of hands and feet showed cystic radiolucencies and occasional scalloping and acroosteolysis of affected phalanges. Nail clippings for fungus were negative.

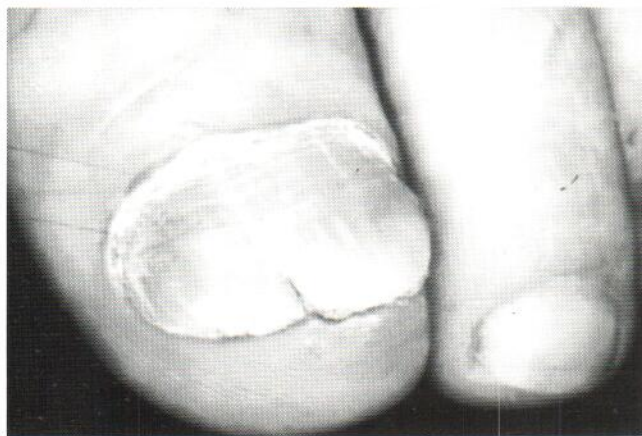

Fig. 1. Onycholysis, subungual hyperkeratosis and fissuring (case 2).

Nail histopathology

The matrix was of normal thickness (cases 1 and 3) or slightly atrophic (case 2), and focally a granular layer and parakeratosis were present. The rete ridges were partially flattened by the presence in the sub-matrix dermis of a dense non-caseating granulomatous infiltrate. The epidermis of the nail bed (cases 1 and 2) showed irregular focal acanthosis alternating with moderately atrophic areas and papillomatosis with digitated prolongations (Fig. 2). There was focal hypergranulosis with thick coarse keratohyalin granules. The nail plate was distorted with a sinuous arrangement of the corneal layers, which showed loss of cohesion and alternating basophilic and eosinophilic areas. In the nail bed the dermis was extensively occupied by the granulomatous infiltrate, surrounded by thin collagen tracts. Distally there were areas of detachment of the nail plate and hyperkeratosis.

DISCUSSION

Since Pautrier, in 1940, stated that "the chapter on nail lesions in the Besnier-Boeck-Shaumann disease is to be described", only about 30 patients with onychodystrophy attributable to sarcoidosis have been reported (1-9); 2 of these cases have been histopathologically confirmed, and in the remainder diagnosis was

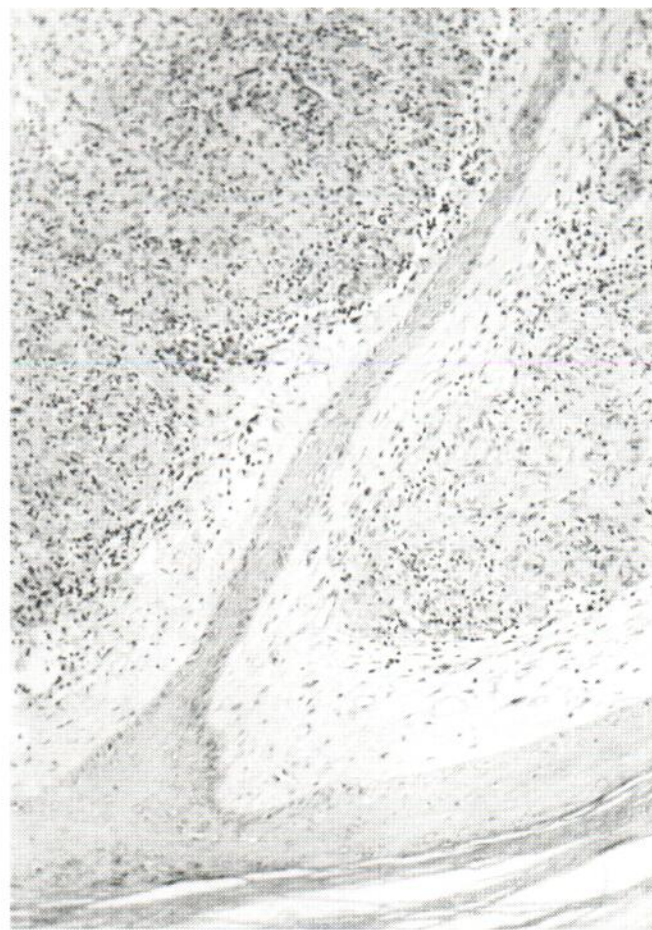


Fig. 2. Non-caseating granulomatous dermal infiltrate and papillomatosis in nail bed (case 1).

one of exclusion, after discarding other possibilities such as onychomycosis, psoriasis, trauma and drug eruption, in patients with proved sarcoidosis elsewhere.

A punch biopsy in the proximal fold is enough for diagnostic purposes; yet to establish an appropriate study of the nail unit pathology, a longitudinal biopsy would be more adequate, since – as our cases have demonstrated – all their structures were affected. The most remarkable finding is the strong granulomatous dermal infiltrate, from the proximal nail fold to the hyponychium, particularly dense in the nail bed. The epidermal changes were also prominent at this level, and both facts explain the colour changes and contributed to the thickening, irregularity and roughening of the nail plate. The atrophy in the matrix (significantly more intense in the case 2, associated with clinical fissuring) and the distortion of the rete ridges cause longitudinal grooves, and their progression could lead to pterygium formation and nail loss. Splinter haemorrhages are in relation to minimal trauma in a matrix in close contact with dermal capillaries. All these findings can be explained on the basis of the microcompressing effect by sarcoid granulomas in a dermal compartment limited by two rigid structures: the phalanx and the nail plate. Furthermore, disorders of keratinization were observed, expressed as parakeratosis, coarse keratohyalin granules, loss of cohesion, staining disturbance and distal hyperkeratosis and detachment, which clinically manifested as thickening, fragility, onycholysis, and subungual hyperkeratosis. Since spe-

cific disorders of keratinization are not attributable to sarcoidosis, these will also be secondary to granulomatous compression.

REFERENCES

1. Patel KB, Sharma OP. Nails in sarcoidosis: response to treatment. *Arch Dermatol* 1983; 119: 277–278.
2. De Sablet M. Sarcoidose avec maladie de Perthes-Jungling et onyxis. *Bull Dermatol Syphil* 1971; 78: 289–291.
3. Mann RJ, Allen BR. Nail dystrophy due to sarcoidosis. *Br J Dermatol* 1981; 195: 599–601.
4. Pitt P, Hamilton EBD, Innes EH, Morley ED, Monk BE, Hughes GRV. Sarcoid dactylitis. *Ann Rheum Dis* 1983; 42: 634–639.
5. Kalb RE, Grossman ME. Pterygium formation due to sarcoidosis. *Arch Dermatol* 1985; 121: 276–277.
6. Leibowitz MR, Essop AR, Shamroth CL, Blumshon D, Smith EH. Sarcoid dactylitis in black South African patients. *Sem Arth Rheum* 1985; 14: 232–237.
7. Cox NH, Gawkrödger DJ. Nail dystrophy in chronic sarcoidosis. *Br J Dermatol* 1988; 118: 697–701.
8. Chang A, Koopman RJJ. Sarcoidosis. Proceedings of the 260th scientific meeting of the Netherlands society for dermatology and venereology, Nijmegen, 26 Sep. 1992. *Br J Dermatol* 1993; 129: 212.
9. Morrison JGL. Sarcoidosis in the Bantu. Necrotizing and mutilating forms of the disease. *Br J Dermatol* 1974; 90: 649–655.

Accepted January 13, 1995.

A. Losada-Campa¹, C. De la Torre-Fraga¹, A. Gomez de Liaño², M.J. Cruces-Prado¹, ¹Service of Dermatology, Hospital Provincial de Pontevedra. ²Dermatology Clinic, Hospital Montecelo, Pontevedra, Spain.

Epidermolytic Hyperkeratosis of the Nails in Keratosis Palmoplantaris Nummularis

Sir,

Patients with localized palmoplantar keratoderma (PPK) may exhibit nail changes that are more commonly associated with diffuse PPK (1, 2). We report here the pathological evidence of epidermolytic hyperkeratosis (EH) of the nails in a patient affected with localized epidermolytic PPK.

CASE REPORT

A 25-year-old male carpenter consulted us because of painful palmoplantar hyperkeratosis associated with psoriasiform nail abnormalities involving both fingernails and toenails.

The clinical history revealed that the patient had been affected with plantar keratoderma since the age of 3 and palmar keratoderma since the age of 18. The patient had first noticed thickening and discoloration of his fingernails and toenails 1 year before our examination. During the last 3 years plantar and palmar lesions had considerably enlarged and become painful. The family history revealed that his mother and sister were also affected by nummular painful PPK.

Clinical examination revealed numerous nummular thick yellow keratotic patches over the pressure areas of the patient's palms and soles. His toenails were dark-yellow in colour and markedly thickened because of subungual hyperkeratosis. His fingernails showed mild subungual hyperkeratosis associated with onycholysis and distal splinter haemorrhages. The cuticles of fingernails and toenails were markedly

hyperkeratotic (Fig. 1). The rest of the skin was normal, including the dorsal aspect of the hands and feet. The teeth and hair were also normal.

The patient had no local hyperhidrosis of the palms and soles. KOH preparations and cultures of nail and skin scrapings were negative.

A biopsy from a keratotic plantar lesion revealed massive orthohyperkeratosis, with irregular hypergranulosis, acanthosis and vacuolization of the upper malpighian layers.

A longitudinal nail biopsy from the fifth right toenail revealed marked hyperkeratosis of the ventral portion of the proximal nail fold, distal nail bed and hyponychium. The ventral portion of the proximal nail fold (Fig. 2), the distal nail bed and the hyponychium showed perinuclear vacuolization of suprabasal keratinocytes and a thickened granular layer containing irregular basophilic keratohyalin granules. The nail matrix was not involved.

Since the patient refused oral retinoids, a local treatment with keratolytic agents was prescribed, with mild improvement of the keratoderma.

DISCUSSION

The clinical and pathological features of our patient are consistent with a diagnosis of keratosis palmoplantaris nummularis (KPPN). This name was coined by Wachters et al. (3) to describe a dominant inherited circumscribed type of PPK associated with the pathological features of EH. Clinically, KPPN is characterized by focal keratoses located on the plantar pressure