

Pseudoallergic Hepatitis after a Single Intake of 10 mg Acitretin (Neotigason®) for Treatment of Psoriasis Pustulosa

Sir,

Using synthetic retinoids has become a well established treatment for severe forms of psoriasis and the different types of ichthyosiform disorders during the past decade (1). Acitretin, the first metabolite of etretinate, has advantages over etretinate due to the same profile of effect and a half-life period half as long as etretinate (1). The most frequent side-effects known are dry mucous membranes, alopecia, elevation of triglycerides in serum and teratogenicity (2). According to our knowledge a hepatotoxic reaction in the sense of an idiosyncrasy within 2 h after a single intake of 10 mg acitretin has not yet been described.

CASE REPORT

A 25-year-old female patient with histologically proven psoriasis pustulosa of 6 months' duration displayed a generalized exanthema with

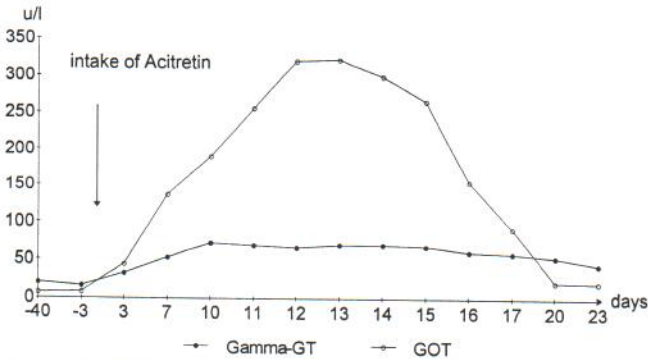


Fig. 1. Follow-up of liver enzymes (γ -GT and GOT) before and after a single intake of 10 mg acitretin.

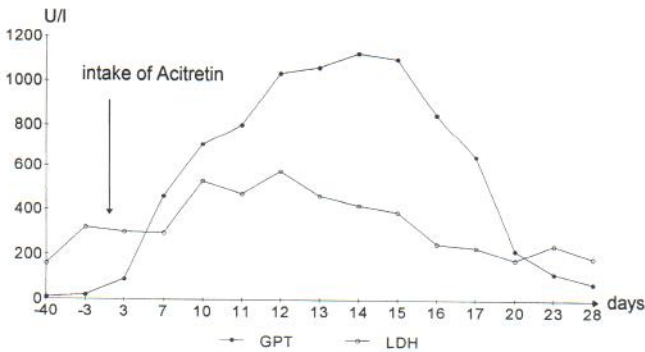


Fig. 2. Follow-up of liver enzymes (GPT and LDH) before and after a single intake of 10 mg acitretin.

pruritus about 90 min after the first and final intake of acitretin. Subsequently a hepatotoxic reaction developed, with the peak of liver enzymes at the 14th day (Figs. 1, 2). Four weeks later the liver enzymes returned to normal levels. A viral hepatitis (tests in part repeated several times: IgG anti-HA positive; negative were: IgM anti-HA, HB_sAg, anti-HB_s, HB_cAg, herpes simplex, varicella zoster, cytomegalovirus infection, infectious mononucleosis, coxsackie-virus B₁₋₅ and HIV) or a cholestase of different causes (controlled by ultrasound and CT of the abdomen) were excluded, as well as a focus in the otolaryngological, dental, thoracical, abdominal or gynecological area. No drug-related allergy could be found. The combination oral contraceptive Triquilar® (Levonorgestrel and Ethinylestradiol) had been taken regularly for about 5 years. The patient had never taken any other retinoids (e.g. etretinate or isotretinoin). There was no alcohol consumption in the same period as the intake of acitretin. A biopsy of the liver was refused by the patient.

DISCUSSION

Acitretin is a monoaromatic retinoid and the most important metabolite of etretinate. According to Sanchez et al. (3) hepatitides caused by long-term intake of retinoids (acitretin and etretinate) are known but not common. The latency between onset of treatment and incidence of hepatitis ranged from 3 weeks to more than 5 years, the average being about 3–6 months. Ten cases of unspecific reactive hepatitis, 4 acute hepatitides, 6 chronic active hepatitides as well as 3 cases of fibrosis and cirrhosis could be established by liver biopsy. A similar fast and pronounced hepatotoxic reaction following a single intake of 10 mg acitretin has not been previously described. Hepatitides in the sense of an idiosyncrasy have been reported in connection with the intake of etretinate, but in these cases changes of liver enzymes occurred 1–18 weeks after application of the substance (4).

REFERENCES

1. Fritsch PO. Retinoids in psoriasis and disorders of keratinization. *J Am Acad Dermatol* 1992; 27: 8–14.
2. Vahlquist A. Long-term safety of retinoid therapy. *J Am Acad Dermatol* 1992; 27: 29–33.
3. Sanchez MR, Ross B, Rotterdam H, Salik J, Brodie R, Freedberg IM. Retinoids hepatitis. *J Am Acad Dermatol* 1993; 28: 853–858.
4. Kano Y, Shiohara T. Cholestatic hepatitis occurring shortly after etretinate therapy. *J Am Acad Dermatol* 1994; 31: 133–134.

Accepted February 10, 1995.

Andreas Blum, Christian Scherwitz, and Gernot Rassner, Department of Dermatology, University of Tübingen, Liebermeisterstrasse 25, D-72076 Tübingen, Germany.