

## LETTERS TO THE EDITOR

### Urticaria Pigmentosa in Identical Male Twins

Sir,

Although rare, there are well documented reports of familiar mastocytosis. In 50 families various forms of mastocytosis affected more than one member, from which in 22 families two or more generations were affected; in 20 families mastocytosis occurred only in female members and in 17 families in both sexes (1). Urticaria pigmentosa has been reported in 10 pairs of identical twins, two pairs of fraternal twins and one set of triplets (1, 2 for ref). We here describe a pair of twins with urticaria pigmentosa.

#### CASE REPORT

The patients were monozygotic twin boys (A<sub>2</sub>B Rh-negative), born in 1972 with one placenta. It was not known if the amniotic sac or chorion had been single or double. At the age of 4 months both boys had developed multiple reddish-brown macular lesions, 2–3 mm in diameter, on the trunk, extremities, palms and soles. After they had been eating certain foods (especially fruits), urticaria developed at the sites of the above described lesions. Their parents were not related, and there was no family history of mastocytosis.

At the age of 14 both patients had multiple 2–3 mm permanent reddish-brown macules on the trunk, extremities, palms and soles, but not on the scalp and face (Fig. 1). Biochemical, immunological, haematological and coagulation studies were normal. There was no lymphadenopathy or splenomegaly. In one patient abdominal ultrasonography revealed hepatomegaly with no focal changes (5 cm below the right costal margin with hyperechogenic structure). Six years later ultrasono-

graphy of the liver was normal. Bone-marrow scintigraphy using 99 m Tc-Lyocol (Sorin) as the tracer (3) showed in both patients an abnormal peripheral expansion of the active bone-marrow to the tibial and antebrachial region, with normal uptake of the tracer. In both cases small localized accumulations of the tracer were found in the ribs and collarbone. Histological examinations of skin biopsies taken from lesions showed a superficial dermal infiltrate of mast cells.

The patients have been on long-term therapy with ketotifen (3–4 mg daily) and clemastinum (2 mg daily). Their disease remains stable.

#### REFERENCES

1. Anstey A, Lowe DG, Kirby JD, Horton MA. Familiar mastocytosis: a clinical, immunophenotypic, light and electron microscopic study. *Br J Dermatol* 1991; 125: 583–587.
2. Soter NA. The skin in mastocytosis. *J Invest Dermatol* 1991; 96: 32S–39S.
3. Sollberg S, Holzmann H, Marseh WCh, Altmeyer P, Hor G. Urticaria pigmentosa – eine obligate Systemerkrankung? Nuklearmedizinische Untersuchungsergebnisse und ihre ätiopatogenetische Deutung. *Hautartz* 1987; 38: 583–588.

Accepted October 10, 1994.

J. Pec<sup>1</sup>, E. Palencarova<sup>1</sup>, S. Malisova<sup>1</sup>, D. Dobrota<sup>2</sup>, A. Hajtman<sup>3</sup>, M. Pec<sup>4</sup> and J. Lepej<sup>5</sup>

Departments of <sup>1</sup>Dermatology, <sup>2</sup>Biochemistry, <sup>3</sup>Otorhinolaryngology, <sup>4</sup>Pharmacology and <sup>5</sup>Nuclear Medicine, Jessenius Medical School, Comenius University, Martin, Slovak Republic.

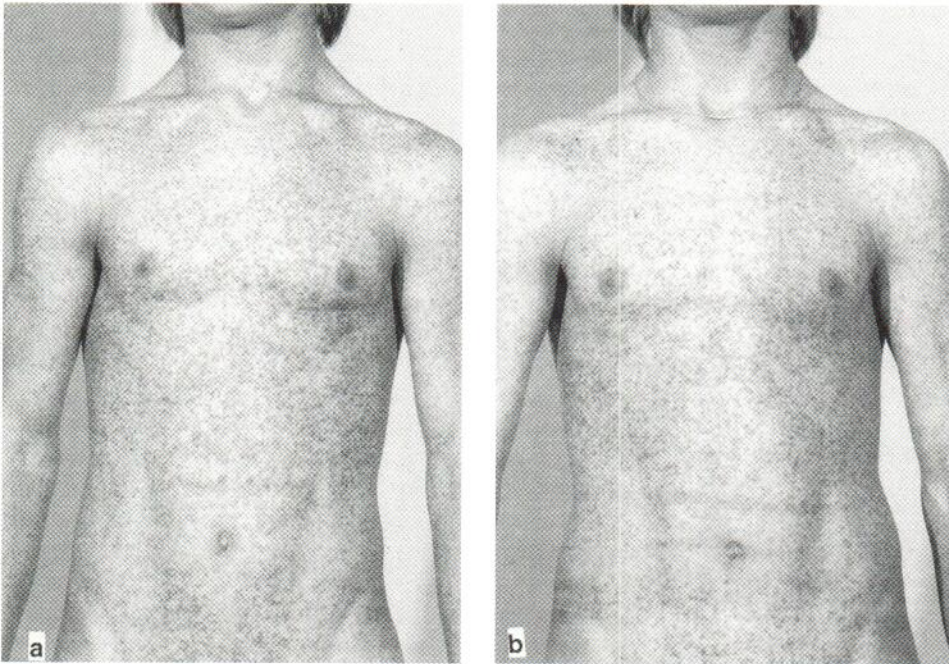


Fig. 1. Multiple brown macular lesions of urticaria pigmentosa from identical twins. a) Twin 1, b) Twin 2.