

# Photoirritation: A New Photobiologic Phenomenon Induced by Long Wavelength UVA Radiation in Hairless Mice Treated with Broad-spectrum Sunscreens

LORRAINE H. KLIGMAN, PEISHU ZHENG\* and ALBERT M. KLIGMAN

Department of Dermatology, University of Pennsylvania School of Medicine, Philadelphia, PA, USA

While assessing the protective effect of broad-spectrum sunscreens against chronic UVA radiation, we observed a paradoxical worsening of skin damage with one product. To further examine this finding, five proprietary broad-spectrum sunscreens were applied to albino hairless mice irradiated thrice weekly for 32 weeks with a UVASUN lamp (>340 nm). Appropriate age-matched controls were included. After ~12 weeks, two sunscreens induced a marked dermatitis. Biopsies showed damage greatly exceeding that found in UVA-irradiated, unprotected controls. Histologically, elastic fibers were hyperplastic, coalescing into elastotic clumps. Glycosaminoglycans also increased. Collagen damage was notable since UVA alone does not induce a histologic change. Electron microscopy confirmed these findings. Two other sunscreens provided nearly complete protection. Against chronic UVB radiation, the two UVA photoirritating sunscreens provided substantial protection. Since the UVA sunfilter, oxybenzone, was the same in all sunscreens, we postulate that an irritating component of the vehicle was responsible for the UVA-induced photoirritation. The fifth sunscreen produced severe damage with UVB and UVA. **Key words:** inflammation; photodamage; connective tissue; skin.

(Accepted October 25, 1994.)

Acta Derm Venereol (Stockh) 1995; 75: 205–211.

L.H. Kligman, Department of Dermatology, University of Pennsylvania, School of Medicine, Clinical Research Building, Room 227-415 Curie Blvd., Philadelphia, PA 19104-6142, USA.

The sun protection factor (SPF) is defined as the ability of a sunscreen to prevent erythema induced by UVB radiation, an acute effect. We demonstrated, previously, that broad-spectrum SPF 15 sunscreens protected the skin of hairless mice against chronic irradiation with UVB alone or with solar-simulating radiation and its large UVA component (1, 2). Other workers have reported similar findings (3–5).

To be considered broad-spectrum, the sunscreen must contain a UVA-absorbing component. In our studies and in those of Bissett et al. (3), the UVA absorber was oxybenzone, a benzophenone, with peak absorption at 320 nm. Subsequently, a new molecule was introduced with peak absorption at 360 nm (avobenzone: 4-tert. butyl-4'-methoxydibenzoyl-methane: Parsol 1789®). We compared its protective effect against chronic UVA with that of an oxybenzone sunscreen. We found that the avobenzone-containing sunscreen was highly effective, whereas with the oxybenzone product, the histologic photodamage

greatly exceeded that induced by UVA in the absence of sunscreens (6). Clinically, a severe chronic dermatitis was induced with this particular oxybenzone product. This finding, which we have termed "photoirritation", was surprising because concurrent studies with another oxybenzone product showed excellent protection against chronic UVA exposure (L.H. Kligman, unpublished observations). We began the current series of investigations in an attempt to confirm our earlier observation and to identify the component(s) responsible for this unexpected phenomenon.

## MATERIALS AND METHODS

### Animals and sunscreens

Female albino Skh-hairless-1 mice were obtained from Charles River Laboratories (Wilmington, MA). Animals were housed, two per cage, with room lighting by General Electric F40 GO gold fluorescent lamps, which emit no UV Radiation (12 h on/off cycle). Each treatment group contained eight mice.

The sunscreens tested with UVA radiation were: Shade® SPF 15 (Schering-Plough Corp., Memphis, TN), Pre Sun® SPF 15 Cream\* (Westwood-Bristol Myers, Buffalo, N.Y.), Sundown® SPF 15 (Johnson and Johnson, Skillman, N.J.), Bain de Soleil Creme® SPF 15\* (Procter and Gamble, Cincinnati, Ohio) and Bullfrog® SPF 36 (Chattem, Inc., Chattanooga, TN). The latter two sunscreens were chosen because they were acutely irritating to the skin of hairless guinea pigs (see below). Control groups included UVA-irradiated, unprotected mice and age-matched unirradiated mice. In a subsequent study, the following sunscreens were tested with UVB: Sundown®, Bain de Soleil® and Bullfrog®. Separate groups of mice were treated with the same sunscreens and UVA. All agents were applied to the dorsum, at a surface dose of 2.5 µl/cm<sup>2</sup>, 5 min prior to each exposure.

\* No longer available in the formulation tested.

Table I. Hairless guinea pig inflammation assay

Sunscreen	SPF	Inflammation Grade*
Sunseekers Children's Block	15	1
Water Babies Sunblock Lotion	15	0
Coppertone	15	0
Bain de Soleil	15	3
Sundown Water Proof	15	0
Eclipse	15	1
Sol Bar	15	0
Super Shade	15	1
Pre Sun	29	2
Bain de Soleil	30	3
Bullfrog	36	3

\* Inflammation grading system: 0 = none; 1 = slight; 2 = moderate; 3 = severe.

\* Present address: Department of Pathology, Hahnemann University, Broad &amp; Vine Streets, Philadelphia, PA 19102.



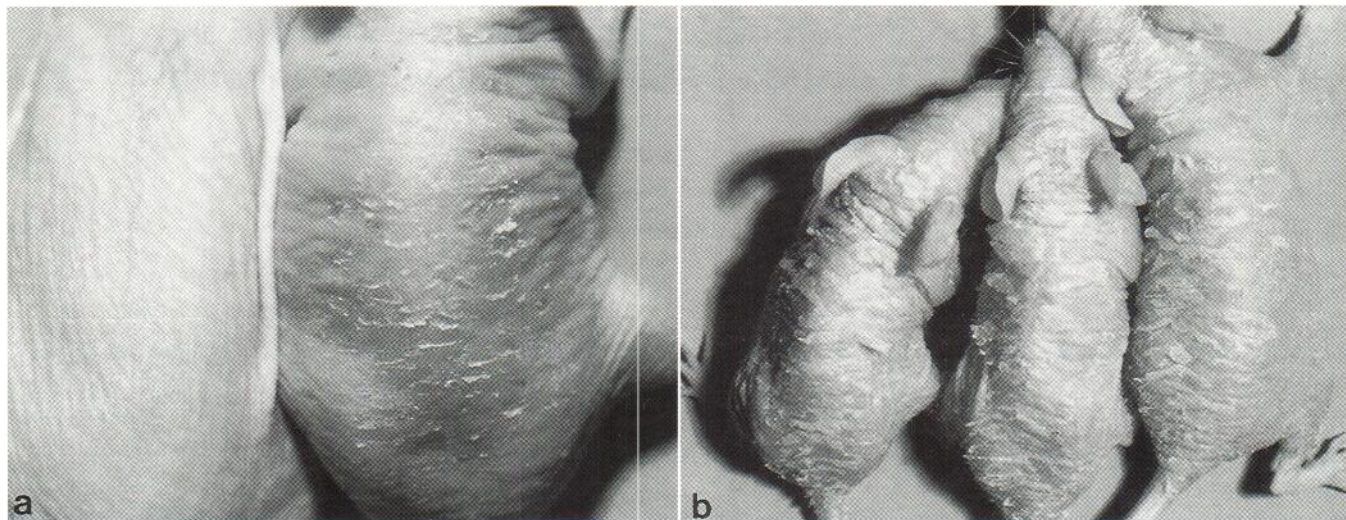


Fig. 1. Clinical appearance. A. Thirty-two weeks of UVA radiation. The mouse treated with a non-phototoxic sunscreen (*left*) has normal-appearing skin. The mouse treated with a phototoxic sunscreen (*right*) exhibits scaling and pin-point ulcers. The dorsal trunk skin is thickened and has lost the fine skin markings seen on the mouse to the left. Mag. X2. B. Two weeks of thrice weekly UVA radiation with Bullfrog<sup>®</sup> applied prior to each exposure. Large, thick scales cover the entire treated area. Mag. X1.

We also examined, with UVA, some pure chemicals which are frequently present in sunscreens, namely triethanolamine, stearyl alcohol and 5.0% sodium lauryl sulfate. These were applied in 100  $\mu$ l amounts 5 min prior to exposure. A control group was treated with one of the previously non-irritating sunscreens (Sundown<sup>®</sup> SPF 15).

#### UVA source and schedule

A UVASUN 3000 lamp (Mutzhas Productions, Munich, Germany) provided long wavelength UVA (340–400 nm). The spectral output of this lamp has been published (7). Mice were irradiated in groups of eight in a specially designed cage that prevented them from shielding each other. Exposures were thrice weekly (M.W.F.) for 32 weeks to a total dose of 8,000 J/cm<sup>2</sup>. Each exposure of 100 J/cm<sup>2</sup>, achieved gradually by 25 J/cm<sup>2</sup> increments over the first 3 weeks, was marginally erythemic in unprotected mice. The irradiance at skin level was  $\sim$ 15 mW/cm<sup>2</sup>, as measured with an IL 700A research radiometer (International Light, Inc., Newburyport, MA). The UVA sensor had a peak sensitivity at  $\sim$ 360 nm. To ensure that no wavelengths shorter than 340 nm were emitted by the lamp, filters were changed after 400 h of use. Previous spectral radiometric measurements have shown that the filters

begin to emit shorter wavelengths after 500 h (unpublished observations). Ambient temperature at mouse level was kept at  $\sim$ 27°C by two small fans.

#### UVB source and schedule

A bank of 8 Westinghouse FS-40 tubes, filtered with cellulose triacetate film to attenuate UVC, provided UVB radiation over the range of 290–320 nm, with peak emission at  $\sim$ 313 nm. The small amount of UVA emitted by this source has been shown to be non-injurious to hairless mouse connective tissue (8). UVB mice were irradiated thrice weekly for 20 weeks. Each exposure was 0.15 J/cm<sup>2</sup> or 10 minimal erythema doses (MED). At skin level, the irradiance was  $\sim$ 0.12 mW/cm<sup>2</sup> as measured with the IL 700A radiometer using a UVB sensor (peak sensitivity: 290 nm). No unprotected UVB controls were included because 10 MEDs could not be tolerated. Baseline data is available for a chronic 6 MED dose (1).

#### Histology and ultrastructure

Mice were sacrificed by CO<sub>2</sub> inhalation. Biopsies from the central dorsum (2  $\times$  1/2 cm) were processed for light microscopy and stained

Fig. 2. Full thickness skin. Hematoxylin and eosin stain.

A. UVA (8,000 J/cm<sup>2</sup>): no protection. The skin is greatly thickened, a result, mainly, of dermal cyst proliferation (\*). The epidermis is hyperplastic and sebaceous glands ( $\rightarrow$ ) are enlarged. Inflammation, although exacerbated, is confined to the cyst area, as it is in normal hairless mice. Mag. 95X.

B. UVA (8,000 J/cm<sup>2</sup>): non-phototoxic sunscreen. Overall thickness is normal, as is cyst content (\*). The only evidence for the UVA exposure are the slightly hyperplastic epidermis and enlarged sebaceous glands. The mild inflammation is confined to the cyst area ( $\rightarrow$ ). Mag. 95X.

C. UVA (8,000 J/cm<sup>2</sup>): phototoxic sunscreen. The epidermis is irregularly hyperplastic, with focal dyshesion ( $\rightarrow$ ). Cysts are moderately proliferated, contributing to the considerable thickening of the skin. Upper dermis is diffusely infiltrated with inflammatory cells, which also extend into the cyst area. Mag. 95X.

D. UVA (4,400 J/cm<sup>2</sup>): Bullfrog<sup>®</sup>. A higher magnification illustrates the compact, thickened, parakeratotic stratum corneum and diffuse, severe inflammatory infiltrate. Subcorneal pustules (\*) are present, and only remnants of sebaceous glands remain ( $\rightarrow$ ). Mag. 150X.

Fig. 3. Elastic fibers. Luna's stain.

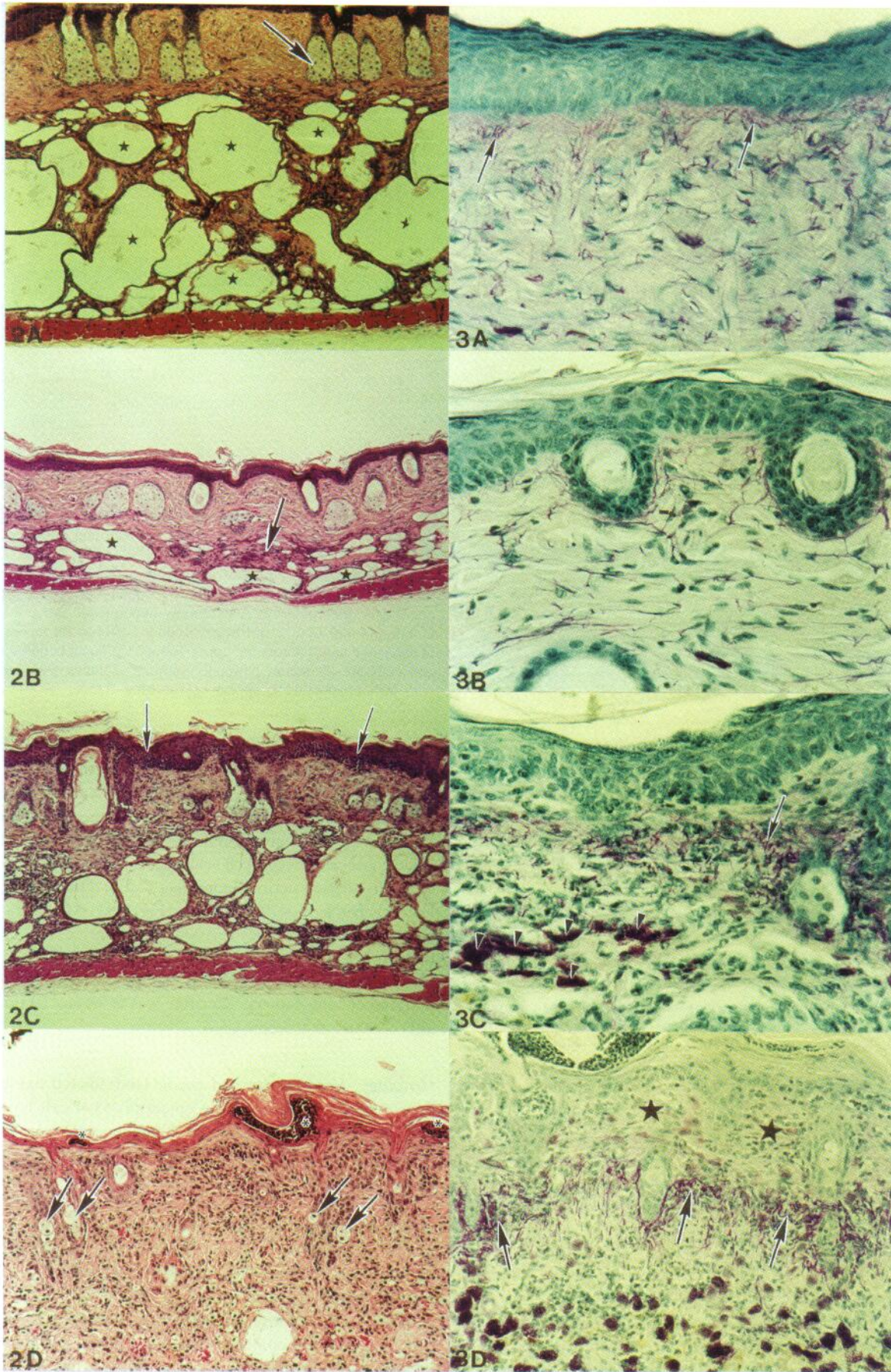
A. UVA (8,000 J/cm<sup>2</sup>): no protection. Elastic fibers are mildly hyperplastic, especially near the dermal-epidermal junction ( $\rightarrow$ ). Mag. 380X.

B. UVA (8,000 J/cm<sup>2</sup>): non-phototoxic sunscreen. Elastic fiber content is similar to that in normal skin. Mag. 380X.

C. UVA (8,000 J/cm<sup>2</sup>): phototoxic sunscreen. Inflammatory cells are abundant in the upper dermis and elastotic clumps are forming ( $\rightarrow$ ). Mast cells are large and numerous ( $\blacktriangleright$ ). Mag. 380X.

D. UVA (4,400 J/cm<sup>2</sup>): Bullfrog<sup>®</sup>. Lower power reveals the severe dermal inflammation, elastosis ( $\rightarrow$ ) and the inflamed subepidermal, collagen-sparse region (\*). Large, purple staining mast cells are abundant in the lower dermis. Mag. 150X.







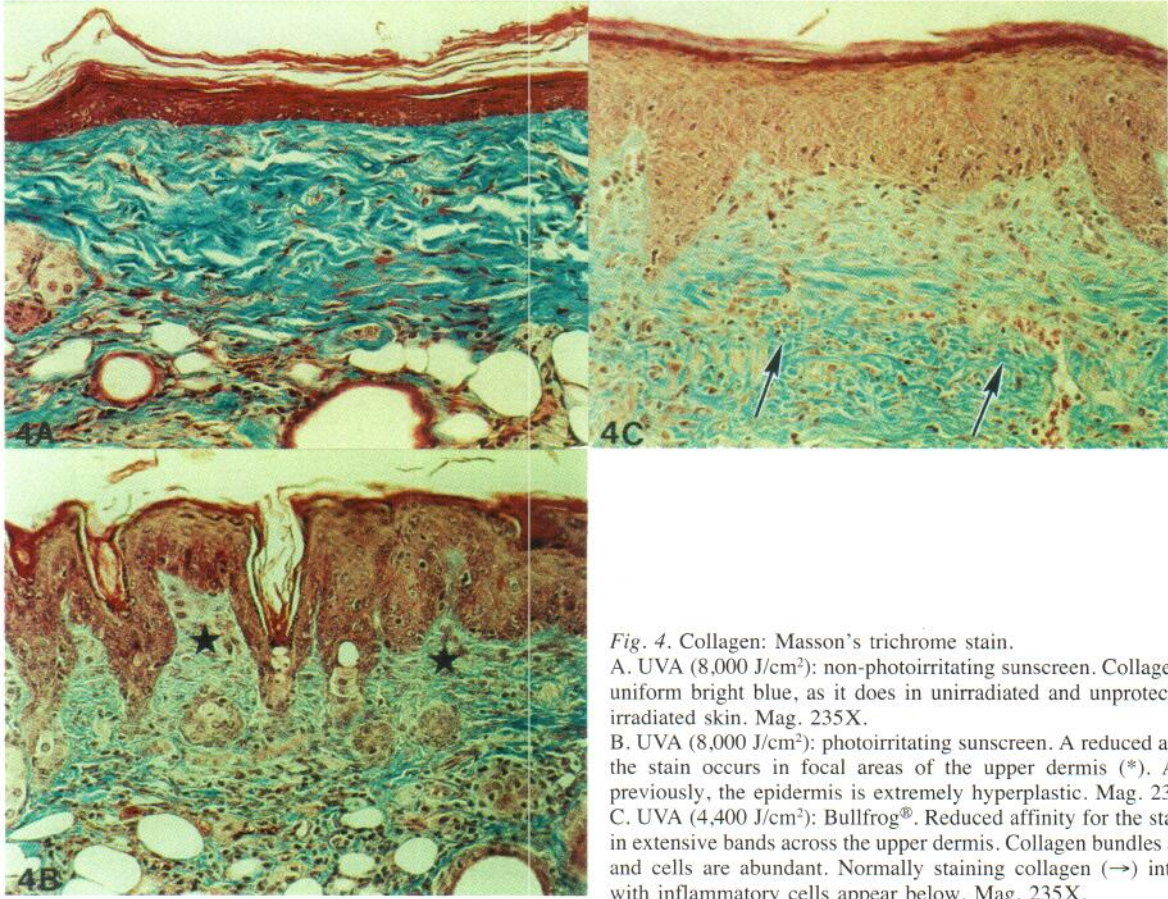


Fig. 4. Collagen: Masson's trichrome stain.

A. UVA (8,000 J/cm<sup>2</sup>): non-photoirritating sunscreen. Collagen stains a uniform bright blue, as it does in unirradiated and unprotected UVA-irradiated skin. Mag. 235X.

B. UVA (8,000 J/cm<sup>2</sup>): photoirritating sunscreen. A reduced affinity for the stain occurs in focal areas of the upper dermis (\*). As shown previously, the epidermis is extremely hyperplastic. Mag. 235X.

C. UVA (4,400 J/cm<sup>2</sup>): Bullfrog<sup>®</sup>. Reduced affinity for the stain occurs in extensive bands across the upper dermis. Collagen bundles are sparse and cells are abundant. Normally staining collagen (→) interspersed with inflammatory cells appear below. Mag. 235X.

with hematoxylin and eosin, Luna's aldehyde fuchsin for elastic fibers (9), Van Gieson's and Masson's trichrome for collagen and Mowry's colloidal iron for glycosaminoglycans (GAGs). The slides were examined in a coded manner.

Adjacent specimens were taken from two sunscreen-treated UVA-irradiated groups for electron microscopy. Specimens were fixed in Karnovsky's solution, followed by 1% osmium tetroxide, and were embedded in Epon 812. Ultrathin sections (70 nm) were stained with a tannic acid-uranyl acetate solution (10), followed by lead citrate, each for 10 min. These were examined with a Hitachi model H 700 electron microscope.

#### Guinea pig irritancy assay

Because the hairless guinea pig is unusually susceptible to chemical irritants, this assay is used routinely in our laboratories to identify substances having the potential to irritate human skin. Female animals, age ~10 weeks, were obtained from Charles River Laboratories (Wilmington, MA). Six 12 mm metal chambers (Hilltop Laboratories, Cincinnati, Ohio) were filled with different proprietary sunscreens. These were applied to the lateral flanks and held in place by wrapping the trunk with occlusive surgical tape. Two animals were treated in duplicate. After 24 h, biopsy specimens were processed for light microscopy. With hematoxylin and eosin stain, inflammation was judged on an ordinal scale of 0–3. By this assay, Bullfrog<sup>®</sup> and Bain de Soleil<sup>®</sup> were strongly irritating (Table I).

## RESULTS

### UVA irradiation

**Clinical appearance.** At the end of the irradiation period, unprotected UVA-exposed mice had the thickened, yellowed, sag-

ging skin typically induced by this waveband (3). Mice protected with Shade<sup>®</sup> or Sundown<sup>®</sup> (non-irritating sunscreens) showed only slightly thickened skin, which was pale but not distinctly yellow and had a normal texture (Fig. 1A). Mice treated with Pre Sun<sup>®</sup> or Bain de Soleil<sup>®</sup> (photoirritating sunscreens) developed marked scaling after ~12 weeks. By the end of the irradiation period, more than half had thickened, scaling, leathery patches on the dorsum (Fig. 1A). Mice treated with Bullfrog<sup>®</sup> were so excessively scaly after only 2 weeks (Fig. 1B) that exposures were reduced to twice weekly. These mice continued to shed large thick scales, but the skin beneath the scales did not become leathery. Sacrifice was at weeks 20 through 26 after 3,800–5,000 J/cm<sup>2</sup> UVA.

**Histology. Hematoxylin and eosin:** Unirradiated hairless mice (age ~40 weeks) have a thin epidermis (3–4 cell layers). The collagen is mainly concentrated in the upper dermis. The lower dermis contains a single to double row of keratinizing cysts, which are typical for this animal, and a thin patchy adipose tissue (1, 2). After 8,000 J/cm<sup>2</sup> of long wavelength UVA, the skin became more than twice as thick with a hyperplastic epidermis of ~7 cell layers, but without atypia. Occasional foci of parakeratosis were present. Dramatically enlarged dermal cysts had proliferated up to 3 rows (Fig. 2A).

Skin protected with non-irritating sunscreens was nearly normal (Fig. 2B). The epidermis was slightly hyperplastic (~5 cell layers). There was no loss of order, atypia or parakeratosis and



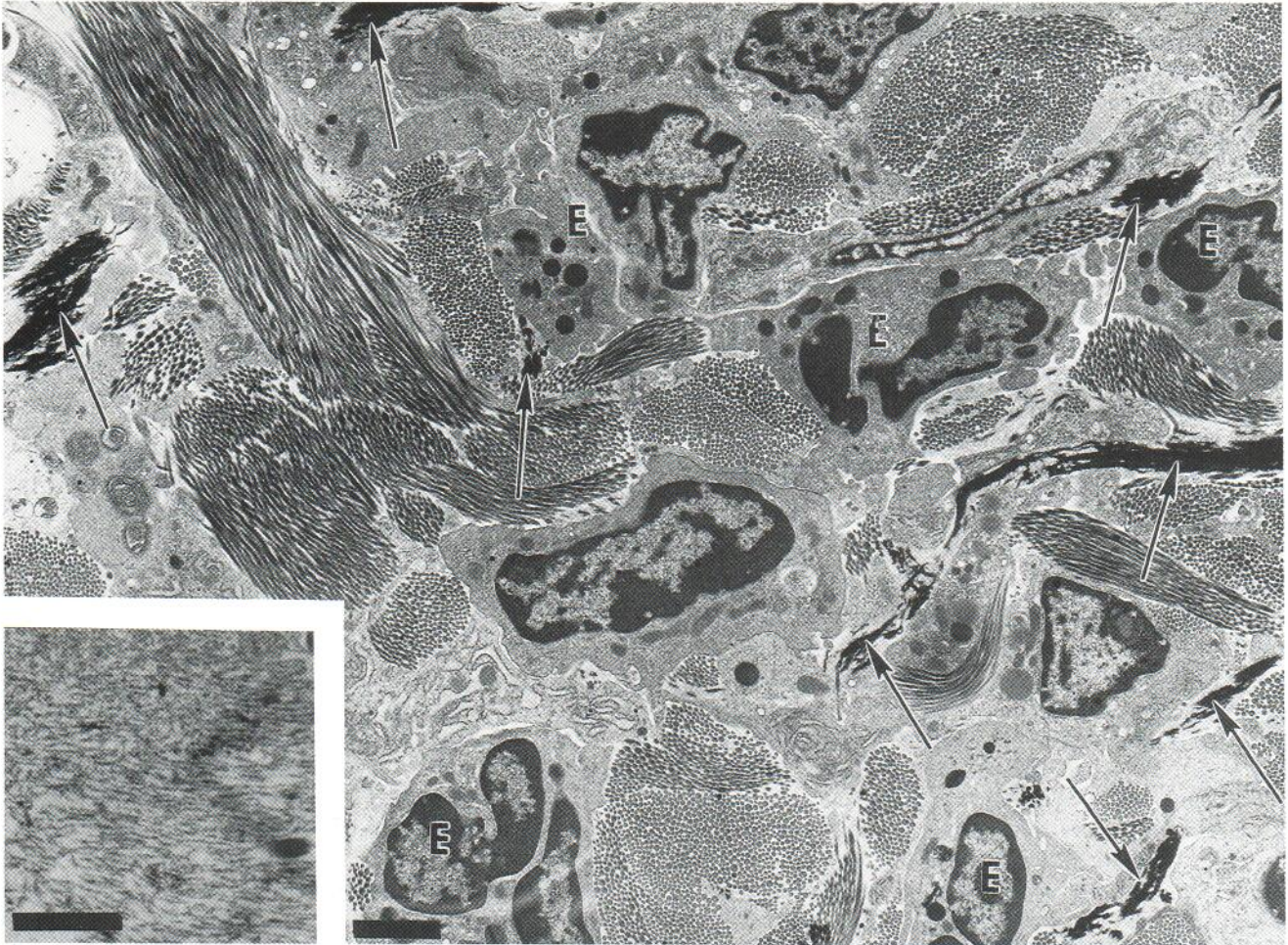


Fig. 5. UVA (8,000 J/cm<sup>2</sup>): photoirritating sunscreen. Elastic fibers (→), heavily coated with electron-dense elastin, are numerous as are eosinophils (E), which are rarely seen in normal or UVA-irradiated mouse skin. Mag. 7500X. Bar = 2 μ. Insert. Masses of well-formed microfibrils lacking elastin coating were often present. Mag. 37,500X. Bar = 0.5 μ.

little or no inflammatory infiltrate. Dermal cysts were within the normal range.

Skin treated with the photoirritating sunscreens was more damaged than the UVA-irradiated, unprotected skin. The epidermis was acanthotic, and keratinocytes were abnormal in size, shape and staining properties (atypia). Lymphocytic inflammatory infiltrates were present in the dermis, with some exocytosis in the epidermis (Fig. 2C). Dermal cysts ranged from one to three rows.

Bullfrog<sup>®</sup>-treated specimens showed the greatest degree of damage. The thickened stratum corneum was extensively parakeratotic. Sub-corneal pustules were abundant. The severely hyperplastic epidermis (~10 cell layers with several thicker downgrowths) had foci of atypia, pronounced dyshesion, and necrosis. Follicles were often elongated, with a hyperplastic epithelium. Sebaceous glands, enlarged in all other groups, were almost totally ablated (Fig. 2D). The very severe dermal infiltrate encompassed lymphocytes, eosinophils and neutrophils. Vessels were dilated and the granulomatous reaction that is normally present in mild form amidst the dermal cysts was greatly accentuated.

**Elastic tissue:** Elastic fibers in unirradiated mice are thin and very sparse (1). After UVA radiation, most specimens had mild to moderate elastic fiber hyperplasia (Fig. 3A). Fibers were also slightly thickened and tortuous. With the non-irritating sunscreens, elastic fibers were mostly unaffected, showing only a mild focal hyperplasia which was within the range of normal age-matched controls (Fig. 3B). The elastic fiber hyperplasia with photoirritating sunscreens was more severe than that in unprotected irradiated skin (Fig. 3C). Elastotic clumps were present in areas of severe inflammation. Bullfrog<sup>®</sup>-treated specimens had large amounts of elastosis which were often surmounted by a highly cellular region containing sparse collagen. Large mast cells were extremely abundant in the mid and lower dermis (Fig. 3D).

**Collagen:** Normal collagen stains a bright blue with the trichrome stain. Confirming earlier studies (2, 7), in which Van Gieson's stain was used, chronic UVA irradiation did not alter the staining properties. Normal staining was also maintained by the non-irritating sunscreens (Fig. 4A). Specimens from photoirritating sunscreens showed occasional small foci with reduced



staining (Fig. 4B). With Bullfrog<sup>®</sup>, these foci were increased and often coalesced into long stretches of non-staining sub-epidermal dermis that were almost devoid of collagen. Below these areas were bands of collagen heavily interspersed with cells that appeared to be a mixture of fibroblasts, mast cells and macrophages (Fig. 4C). Van Gieson's staining of all the specimens showed comparable results.

*Glycosaminoglycans:* Normal hairless mouse skin contains minute amounts of the blue-staining material identified as GAGs by histochemistry (1). After UVA irradiation, dermal GAGs were increased and the normally red-staining collagen acquired a bluish tone as if coated with GAGs (2). With non-irritating sunscreens, the GAG content was as in unirradiated mice, whereas with photoirritating sunscreens, foci of GAGs were increased in number. Bullfrog<sup>®</sup>-treated specimens had greatly increased intercellular epidermal GAGs and abundant subepidermal GAGs.

*Ultrastructure:* The diverse effects of UVA radiation on the ultrastructure of mouse skin have been described previously (6, 11).

The photoirritating sunscreens induced notable ultrastructural changes, many of which were also seen in unprotected UVA-irradiated skin (6, 11). Marked elastic fiber hyperplasia was present (Fig. 5) along with masses of uncoated microfibrils (Fig. 5, insert). Mast cells often appeared to be degranulating. Vascular basement membranes were greatly reduplicated and there were signs of endothelial cell damage (6, 11). Collagen fiber diameters were shifted to smaller sizes as in unprotected UVA irradiated skin (6). Dermal neutrophils, macrophages and especially eosinophils were abundant (Fig. 5).

Skin protected with non-irritating sunscreens showed none of these changes and appeared similar to normal skin (11, 12) or to skin protected with the avobenzone sunscreen (6).

#### *UVB irradiation*

To determine whether photoirritation was UVA-specific, we tested three of the sunscreens with either chronic UVA or UVB irradiation. The non-irritating sunscreen (Sundown<sup>®</sup>) was highly protective, by histologic examination, against both UVB and UVA. Except for a slightly hyperplastic epidermis, the specimens appeared normal. With one of the photoirritating sunscreens (Bain de Soleil<sup>®</sup>) a mild, but unremarkable inflammatory infiltrate was induced by UVB. Stains for elastin and GAGs revealed only slight increases that were within the range of age-matched controls. With UVA, the same sunscreen caused a severe inflammation, marked epidermal atypia and the drastic connective tissue changes described above (Figs. 2C, 3C, 4B).

The other irritating sunscreen (Bullfrog<sup>®</sup>) produced such severe skin damage with UVB that the mice had to be sacrificed after only 10 weeks. The histologic changes were similar to those described for UVA exposure. Severe scaling was apparent after only 2 weeks, suggesting a pure irritant reaction rather than photoirritation. This was confirmed by applying the sunscreen twice weekly to unirradiated mice. Although not as extreme as in irradiated mice, scaling developed after 2 weeks. After 10 weeks, biopsies revealed damage similar to that seen in irradiated

mice, namely epidermal hyperplasia, necrosis, exocytosis and sebaceous gland destruction. The dermis was severely inflamed with vasodilation, elastic fiber hyperplasia and foci of elastosis.

#### *Non-sunfiltering components of sunscreens*

We failed to identify the component(s) responsible for photoirritation. Triethanolamine, stearyl alcohol and sodium lauryl sulfate did not enhance the damage caused by UVA radiation. In this experiment, the control group of mice treated with one sunscreen shown earlier to be non-irritating (Sundown<sup>®</sup>) now, unexpectedly, developed photoirritation accompanied by all the clinical and histologic changes described previously. It was subsequently discovered that the formulation had been changed since the earlier experiments. During the preparation of this manuscript, we have applied the newly photoirritating product to unirradiated mice. After 20 weeks there is no sign of clinical irritation.

## DISCUSSION

The non-irritating, broad-spectrum, oxybenzone-containing sunscreens were surprisingly effective against long wavelength UVA (>340 nm), whereas photoirritating sunscreens were far more damaging than UVA irradiation alone. This result could not be correlated with the SPF. Furthermore, oxybenzone was present in all sunscreens at 3% and can therefore be ruled out as the photoirritant.

We failed to identify the ingredient responsible for photoirritation. Since sunscreens contain numerous ingredients which are not on the label, identification of the responsible component(s) is a formidable task. Only one manufacturer of a photoirritating sunscreen (Procter and Gamble) was willing to provide ingredient information, with others arguing that the sunscreens were no longer on the market in the formulation we tested. It is interesting to note that the sunscreen which proved non-irritating in earlier studies and later became photoirritating had undergone a change in formulation and site of manufacture.

Adverse reactions to sunscreens generally relate to allergic reactions, either contact or photocontact allergy. For example, Kathon CG, a mixture of chloromethyl isothiazolinone and methyl isothiazolinone, has been reported to be a frequent contact allergen (13). It is usually incorporated as a preservative and was in the PreSun<sup>®</sup> product used in this study but not in Bain de Soleil<sup>®</sup>. It could not be ascertained whether Kathon was present in any of the other sunscreens.

It is unlikely that UVA-induced photoirritation is a manifestation of either phototoxicity or photoallergy. Both of these reactions occur acutely either in hours or a few days. Moreover, the histologic picture is very different. The increasing reports of photoallergic contact dermatitis to oxybenzone describe time courses strikingly different from our findings (14). Likewise, irritancy can be excluded since UVB gave quite different results. Neat triethanolamine, although moderately irritating, did not produce photoirritation.

The excessive Bullfrog<sup>®</sup> reaction seemed to be a special case. The severe shedding of thick scales within 2 weeks of either



UVB or UVA exposure was probably due to its high intrinsic irritancy. In fact, it provoked scaling and severe histologic damage in unirradiated hairless mice. Chronic irritation alone is capable of causing elastic fiber hyperplasia in hairless mice (A. M. Kligman, unpublished results).

We are aware that these reactions in the hairless mouse might not be applicable to humans, although previous studies attest to the relevance of this model to human photoaging (15). Nevertheless, manufacturers of sunscreens might be well advised to include an assay for photoirritation as part of the toxicologic work-up of new sunscreens.

## REFERENCES

1. Kligman LH, Akin FJ, Kligman AM. Prevention of ultraviolet damage to the dermis of hairless mice by sunscreens. *J Invest Dermatol* 1982; 78: 181-189.
2. Kligman LH, Akin FJ, Kligman AM. The contributions of UVA and UVB to connective tissue damage in hairless mice. *J Invest Dermatol* 1985; 84: 272-276.
3. Bissett DL, Hannon DP, Orr TV. An animal model of solar aged skin: histologic, physical and visible changes in UV-irradiated hairless mouse skin. *Photochem Photobiol* 1987; 46: 367-378.
4. Plastow SR, Harrison JH, Young AR. Early changes in dermal collagen of mice exposed to chronic UVB irradiation and the effect of a UVB sunscreen. *J Invest Dermatol* 1988; 91: 590-592.
5. Bissett DL, McBride JF, Hannon DP, Patrick LF. Time-dependent decrease in sunscreen protection against chronic photodamage in UVB-irradiated hairless mouse skin. *J Photochem Photobiol B: Biol* 1991; 9: 323-334.
6. Kligman LH, Zheng P. The protective effect of a broad spectrum sunscreen against chronic UVA radiation in hairless mice: a histologic and ultrastructural assessment. *J Soc Cosmet Chem* 1994; 45: 21-33.
7. Kligman LH, Kaidbey KH, Hitchins VM, Miller SA. Long wavelength (>340 nm) ultraviolet-A induced skin damage in hairless mice is dose dependent. In: Passchier WF, Bosnjakovic BFM, eds. *Human exposure to ultraviolet radiation: risks and regulations*. Amsterdam: Elsevier, 1987: 77-81.
8. Kligman LH, Akin FJ, Kligman AM. The contributions of UVA and UVB to connective tissue damage in hairless mice. *J Invest Dermatol* 1985; 84: 272-276.
9. Kligman LH. Luna's technique: a beautiful stain for elastin. *Am J Dermatopath* 1981; 3: 199-200.
10. Kajikawa K, Yamaguchi T, Katsuda S, Miwa A. An improved electron stain for elastic fibers using tannic acid. *J Electron Microsc* 1975; 24: 287-289.
11. Zheng P, Kligman LH. UVA-induced ultrastructural changes in hairless mouse skin: a comparison to UVB-induced damage. *J Invest Dermatol* 1993; 100: 194-199.
12. Hirose R, Kligman LH. An ultrastructural study of ultraviolet-induced elastic fiber damage in hairless mouse skin. *J Invest Dermatol* 1988; 90: 697-702.
13. Rastogi SC. Kathon CG and cosmetic products. *Contact Dermatitis* 1990; 22: 155-160.
14. Collins P, Ferguson J. Photoallergic contact dermatitis to oxybenzone 1994; 131: 124-129.
15. Kligman LH. The hairless mouse and photoaging. Yearly review. *Photochem Photobiol* 1991; 54: 1109-1118.