

Tyrosine Hydroxylase Immunoreactive Fibres in the Skin of Hemodialysed Patients

Sir,

Pruritus is one of the most disturbing symptoms in patients with end-stage renal failure, of which the majority of hemodialysed patients suffer (1). Although there are several theories concerning the development of itch in these patients, the etiopathogenesis of pruritus still remains unclear. A neurogenic explanation has been proposed (2), but only a few studies of skin innervation in patients with impaired renal function have been reported.

Fantini et al. (3) demonstrated that neuron-specific enolase fibres, as well as several neuropeptides, are decreased in the skin of patients with chronic renal failure. Their results are in contrast to the study of Johansson et al. (4), who were unable to show any differences in the density of structural and functional markers of skin innervation in uremic patients, compared to healthy controls.

We studied tyrosine hydroxylase, a marker of noradrenergic innervation, immunoreactivity (TH-IR) in the skin of 20 hemodialysed patients. The patients, age range 23–71 years, were hemodialysed for periods varying from 12 to 102 months. Of these patients 11 suffered from mild to severe pruritus. Punch biopsies (3 mm) were taken from the forearms with arteriovenous fistula under local anesthesia, using 2% lignocaine without adrenalin. Tissue samples were snap frozen, and 8 μ m sections were cut on a freezing microtome. After fixation in 100% acetone, immunohistochemistry was performed. Monoclonal mouse antisera to tyrosine hydroxylase (Incstar, USA) were applied in a 1:50 dilution. Biopsies from the side-matched skin of 4 healthy volunteers were stained as control.

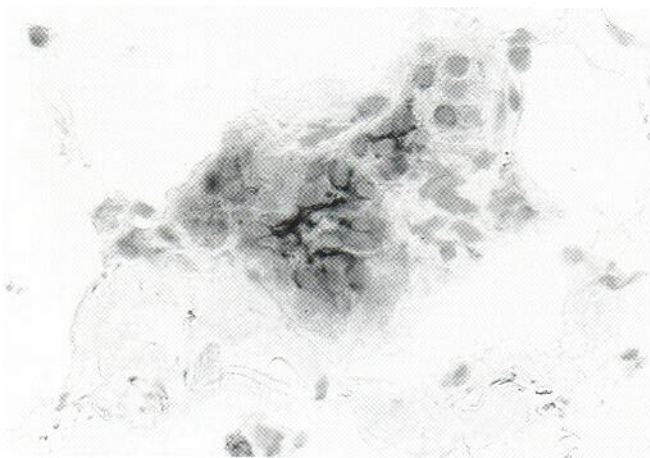


Fig. 1. Immunoreactive TH fibres in the reticular dermis of a hemodialysed patient.

TH-IR was found in the skin of both hemodialysed patients and healthy controls. In the reticular dermis, strong TH-IR was observed, especially around sweat glands and blood vessels (Fig. 1). In the papillary dermis, a lower density of TH-IR fibres was detected, while intra-epidermally, fibres were only sporadically present. No correlation between density of TH-IR fibres and pruritus or dialytic age was found in the patient group. Moreover, no difference between patients and healthy controls was observed with regard to either distribution or density of TH-IR fibres.

The distribution pattern of TH-IR fibres found in our study did not differ from that described previously in healthy individuals (5). Other studies have also failed to demonstrate a correlation between immunohistochemical and clinical data (3, 4).

Although Fantini et al. did not analyse the TH immunoreactivity, they showed decreased density of neuropeptide Y (NPY), which is also regarded as a marker of noradrenergic innervation (3). They demonstrated only some NPY-IR fibres in 3 out of 24 studied patients.

Our preliminary results are similar to the study of Johansson et al. (4) and may suggest that noradrenergic skin innervation is not diminished in hemodialysed patients. However, further studies are necessary to clarify this subject.

REFERENCES

1. Ståhle-Bäckdahl M, Hägermark Ö, Lins L-E. Pruritus in patients on maintenance hemodialysis. *Acta Med Scand* 1988; 224: 55–60.
2. Rosen T. Uremic pruritus: a review. *Cutis* 1979; 23: 790–792.
3. Fantini F, Baraldi A, Sevigiani C, Spattini A, Pinceli C, Giannetti A. Cutaneous innervation in chronic renal failure patients. An immunohistochemical study. *Acta Derm Venereol (Stockh)* 1992; 72: 102–105.
4. Johansson O, Hilliges M, Han SW, Ståhle-Bäckdahl M, Hägermark Ö. Immunohistochemical screening for neurochemical markers in uremic patients on maintenance hemodialysis. *Skin Pharmacol* 1988; 1: 265–268.
5. Tobin D, Nabarro G, Baart de la Faille H, van Vloten WA, van der Putte SCJ, Schuurman HJ. Increased number of immunoreactive nerve fibres in atopic dermatitis. *J Allergy Clin Immunol* 1992; 90: 613–622.

Received August 2, 1993.

Jacek Szepietowski¹, Theo Thepen¹, Willem A. van Vloten¹ and Tomasz Szepietowski². ¹Department of Dermatology, University Hospital, Utrecht, The Netherlands and ²Department of Nephrology, Medical University, Wrocław, Poland.