

LETTERS TO THE EDITOR

Eruptive Satellite Angiomas of the Oral Mucosa

Sir,

In the last years, satellitosis occurring in eruptive angiomas or pyogenic granulomas has been well documented (1-5). In 1990, a review by Weyers and co-workers (4) presented 36 cases and since then more case reports have been published (2, 6). Recurrent satellitosis commonly occurs after a free interval of weeks to months after the removal of an eruptive angioma. Usually, they occur in younger patients and are localized on the trunk. Other localizations have only been described in single cases, that is on the sole of the feet (2), on the lower arm (1), and on the chin (5).

CASE REPORT

In a 76-year-old woman a salivary gland adenoma of the mucosa of the upper lip was excised under local anesthesia. Due to wound infection,

oral antibiotics had to be administered. Four weeks after the excision the patient noted red nodules on skin and mucosa of the upper lip increasing slowly in size and number and sometimes bleeding spontaneously.

On clinical examination the right side of the upper lip showed dark red aggregated papules and nodules up to 5 mm in diameter. On the mucosa of the upper lip and on the intraoral and extraoral gingiva there were aggregated, partially exophytic and partially erosive papules and nodules up to 7 mm in diameter (Figs. 1a and 2a).

Histologic examination of mucosal lesion revealed normal mucosal epidermis, edema in the upper corium with multiple capillaries partly filled with erythrocytes, marked proliferation of the capillary walls and patchy inflammatory infiltration with lymphocytes and neutrophils.

The lesions of the upper lip were coagulated with an argon ion laser (DL 5000 Aesculap Meditec, Heroldsberg) with the following irradiation parameters: spot size 2 mm, power 2.5 W, pulse time 0.3 s. The smaller lesions were coagulated homogeneously, whereas in bigger nodules repeated treatment was necessary until complete resolution. Small angiomas on the mucosa were also coagulated with the argon ion laser. Bigger mucosa lesions were coagulated with a Nd:YAG-laser

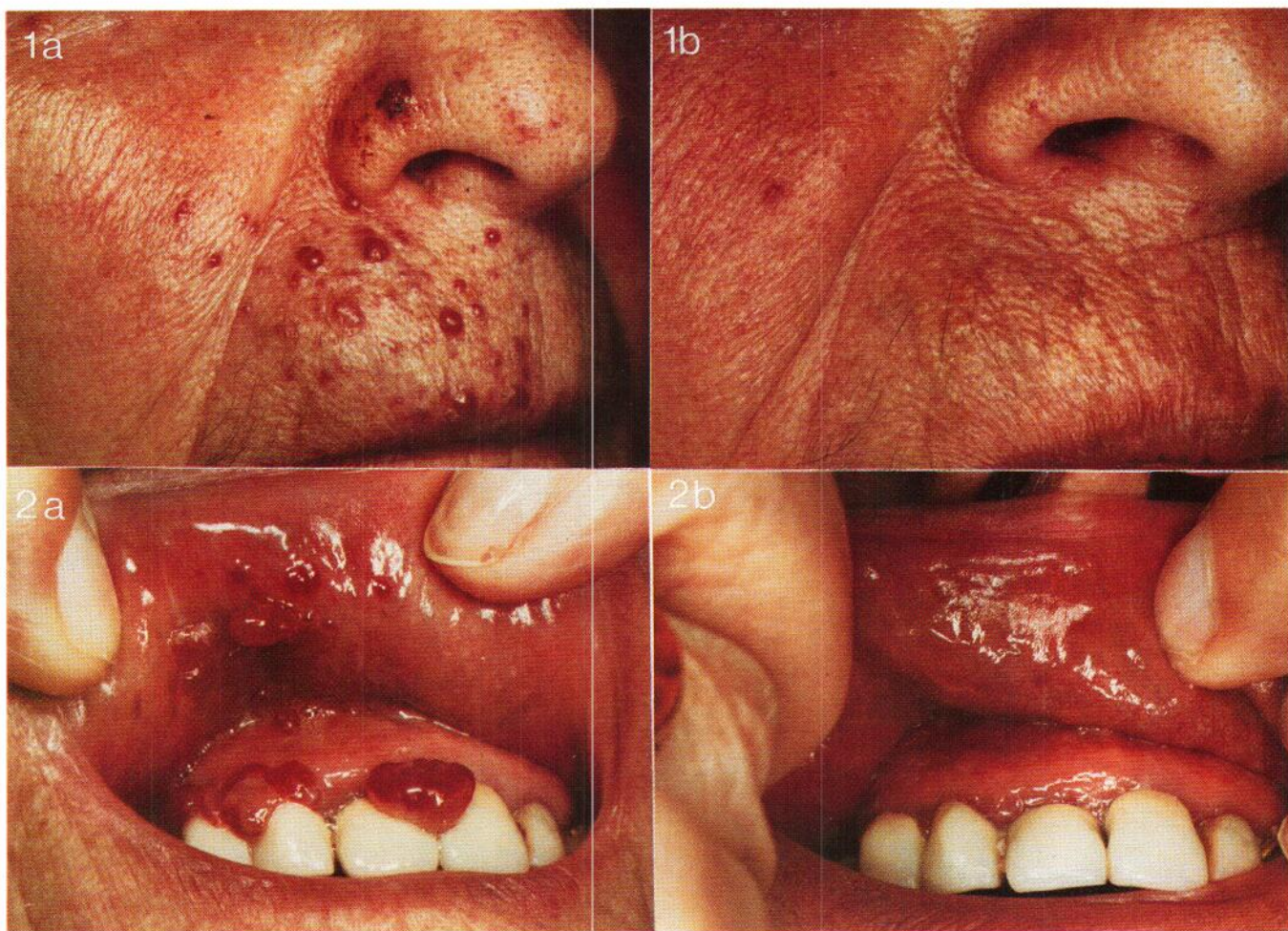


Fig. 1(a). Multiple aggregated angiomas on the upper lip and the right side of the nose.

Fig. 2(a). Partially exophytic angiomas of oral mucosa.

Fig. 1(b). Complete resolution without scars after five treatments with argon laser.

Fig. 2(b). Complete resolution of the oral lesions after coagulation with the argon and Nd:YAG-laser.

(MediLas 40, MMB-AT, Munich, spot size 2 mm, pulse time up to 0.5 s, output up to 20 W). Treatment of the lip was performed without local anesthesia; on the mucosa lidocain spray was used for superficial anesthesia. Complete resolution of the lesions without scar formation was achieved by eight treatment sessions with an average interval of 5 days (Figs. 1b and 2b). The patient is still free of recurrence.

DISCUSSION

Due to the typical history and the clinical picture, the diagnosis of eruptive satellite angiomas was simple and was confirmed by the typical histology of eruptive angiomas.

In our patient, the localization of the satellite angiomas was atypical, as not only the skin of the upper lip but also the oral mucosa and even the gingiva were involved. To our knowledge, mucosal involvement in eruptive satellite angiomas has not been described yet whereas single pyogenic granulomas of the oral mucosa have been well documented (7).

The atypical occurrence of satellite angiomas on skin and mucosal regions with a good vascularization poses the question of the pathogenesis of these satellites. According to Weyers and co-workers (4) a circumscribed disruption of the vascular system may lead to the development of satellite angiomas. Remaining arterial vessels not eradicated with the excision of the first lesions may be responsible for new vessel proliferations and thus for satellite recurrence.

On the trunk, the skin is relatively poor in capillary loops and capillary shunts, so that single arterial vessels supply larger skin areas than in other body regions. Therefore, the hypothetic disorder of one single arterial vessel could lead to the formation of eruptive satellite angiomas in a larger area on the trunk, whereas in other localizations this area is limited due to the presence of other multiple capillary loops and shunts that secure the blood supply. This would be an explanation for the fact that satellite angiomas most commonly occur in truncal localizations.

This explanation is not feasible in our patient as the localization of the satellite angiomas is in a very well vascularized area. In our case, an angiogenic factor presumed in generalized eruptive angiomas might rather be responsible (6, 8). This angiogenic factor might have been produced during secondary wound healing after the excision of the mucosal adenoma and has led to the formation of the intraoral satellitosis due to local spread and contact distribution.

Summarizing the theories of the pathogenesis of satellite angiomas, three forms of pathogenesis should be discussed:

- localized lesions on the trunk due to localized disorders of blood supply
- generalized forms due to a systemic angiogenic factor
- localized forms when the angiogenic factor is only locally effective.

Because of our patient's age a gentle therapy for the recurrently bleeding angiomas had to be found. Argon laser therapy (9), with its limited coagulation depth, was used for smaller angiomas, the thicker lesions were coagulated with a Nd:YAG-laser, which is a common therapeutic tool for hemangiomas (10).

REFERENCES

1. Blickenstaff RD, Roenigk RK, Peters MS, Goellner JR. Recurrent pyogenic granuloma with satellitosis. *J Am Acad Dermatol* 1989; 21: 1241–1244.
2. Shall L, Stevens A, Saihan EM. Recurrent erythematous nodule on the sole of the foot. *Arch Dermatol* 1991; 8: 1219–1220, 1222–1223.
3. Warner J, Wilson J. Pyogenic granuloma recurring with multiple satellites. *Br J Derm* 1968; 80: 218–227.
4. Weyers W, Eberhard P, Paul E, Alles J-U, Hundeiker M. Satellitenrezidive eruptiver Angiome. Eine klinische, histologische und immunzytochemische Studie. *Hautarzt* 1990; 41: 220–225.
5. Zala L. Satellitenförmige Rezidive bei teleangiektatischem Granulom. *Dermatologica* 1973; 147: 18–21.
6. Strohal R, Gillitzer R, Zonzits E, Stingl G. Localized vs generalized pyogenic granuloma. A clinicopathologic study. *Arch Dermatol* 1991; 127: 856–861.
7. Vilmann A, Vilmann P, Vilmann H. Pyogenic granuloma: evaluation of oral conditions. *Br J Oral Maxillofacial Surg* 1986; 24: 376–382.
8. Braunstein-Wilson B, Greer KE, Cooper PH. Eruptive disseminated lobular hemangioma (pyogenic granuloma). *J Am Acad Dermatol* 1989; 21: 391–394.
9. Landthaler M, Dorn M, Haina D, Klepzig K, Waidelich W, Braun-Falco O. Morphologische Untersuchungen zur Behandlung von Naevi flammei mit dem Argonlaser. *Hautarzt* 1983; 4: 548–554.
10. Landthaler M, Haina D, Brunner R, Waidelich W, Braun-Falco O. Neodymium-YAG laser therapy for vascular lesions. *J Am Acad Dermatol* 1986; 14: 107–117.

Received July 20, 1993.

Talal Ahmed Abd-El-Raheem^{1,3}, Ulrich Hohenleutner¹, Otto Braun-Falco² and Michael Landthaler¹. ¹Department of Dermatology, University of Regensburg, Regensburg, ²Department of Dermatology, Ludwig-Maximilian-University of Munich, Munich, Germany and ³Department of Dermatology/STD & Andrology, El-Menia University, El-Menia, Egypt.