

Porokeratosis of Mibelli Associated with Active Chronic Hepatitis and Vitiligo

EDGAR DIPPEL, NORBERT HAAS and BEATE M. CZARNETZKI

Department of Dermatology, Clinics Rudolf Virchow, Free University Berlin, Germany

A patient with porokeratosis Mibelli is reported who suffered from long-standing chronic active hepatitis and rapidly expanding vitiligo of more recent onset. This type of disease association has never been reported before, although it is in line with several reports of porokeratosis in association with immunoregulatory disorders, mostly after drug-induced immunosuppression. The lesions of the present patient responded well to treatment with topical 5-fluorouracil. *Key words: humoral immunity; immunosuppression; 5-fluorouracil.*

(Accepted May 16, 1994.)

Acta Derm Venereol (Stockh) 1994; 74: 463-464.

E. Dippel, Hautklinik, Universitätsklinikum Rudolf Virchow, FU Berlin, Augustenburgerplatz 1, D-13344 Berlin, Germany.

The classical form of porokeratosis Mibelli, characterized by annular plaques with a raised horny border and central atrophy, is considered to be transmitted by an autosomal dominant gene with irregular penetrance which becomes manifest in childhood or adolescence. In the last decade, induction and exacerbation of

porokeratosis have been reported in association with immunoregulatory disorders, mostly after drug-induced immunosuppression. In this paper, an unusual case of porokeratosis Mibelli is reported. The disease started in conjunction with active chronic hepatitis and progressive vitiligo.

CASE REPORT

History

A 62-year-old woman presented with a 2-year history of multiple hyperkeratotic lesions on the gluteal region on the lower extremities. She had a 30-year history of hepatitis after a blood transfusion and a 4-year history of rapidly expanding vitiligo.

Physical examination

On physical examination, numerous (>20) plaque-like, cornified lesions of 5 to 50 mm in diameter with an atrophic center and a keratotic ridge were present on both legs (Fig. 1). None of these lesions were located within the vitiligo lesions, which covered primarily the hands, face, neck and breast.

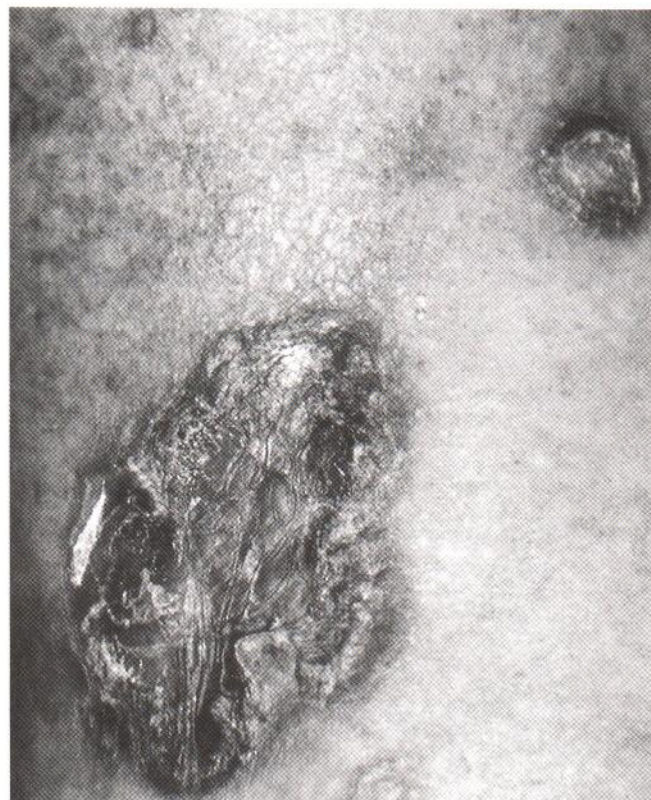

Fig. 1. Lesions of porokeratosis Mibelli on the leg, showing central areas of atrophy and hyperkeratotic borders.

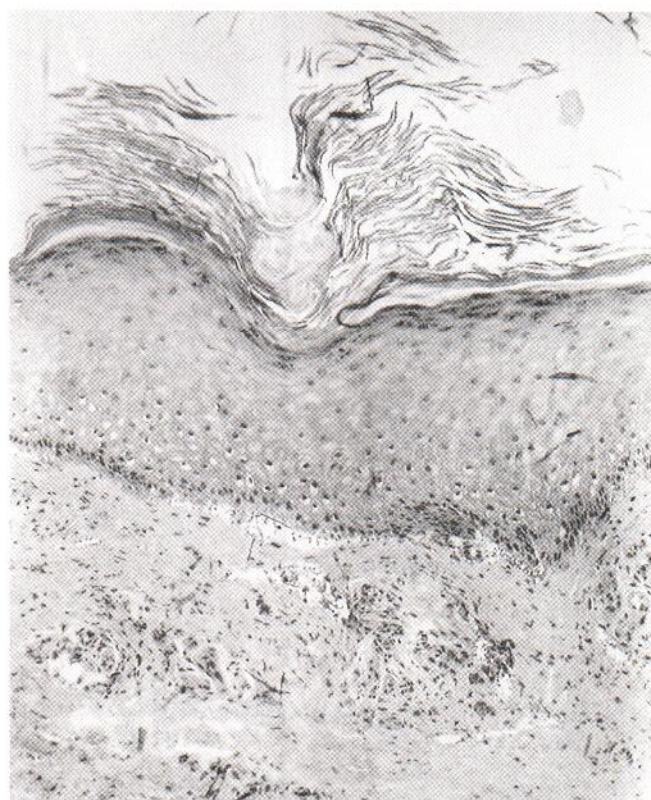


Fig. 2. Porokeratosis of Mibelli showing typical cornoid lamella (hematoxylin-eosin stain; 400x).

Histology

Histopathology of a biopsy from a hyperkeratotic lesion of the leg showed the typical features of porokeratosis: there was an indentation of the epidermis with an overlying cornoid lamella, while the basal layer showed vacuolated keratinocytes (Fig. 2). On immunohistology, deposits of complement C3 were noted in the upper dermal vascular plexus.

Laboratory findings

Laboratory examination revealed signs of chronic active hepatitis, including an elevated S-GOT (27 U/l) (normal values: 5–18 U/l), S-CPT (37 U/l) (normal values: 5–19 U/l), γ -glutamyltranspeptidase (84 U/l) (normal values: 4–18 U/l), γ -globulins (20.5%), and ESR (16/46), with decreased serum albumine (54%), thrombopenia (102.000) and a hypochromic, poikilocytic anemia (hemoglobin 10.9 g/dl, hematocrit 32.5 ml/dl, MHC 23.2 pg, and MCV 69.4 fl). Serologic studies for hepatitis C and for cytomegaly virus were positive and titers for hepatitis A and B negative. Ultrasonography showed hepatomegaly, a beginning liver cirrhosis and splenomegaly. A diagnosis of active chronic hepatitis was established.

Treatment

Several attempts at topical therapy, such as the application of salicylic acid in vaseline or local treatment with corticosteroids and retinoic acid, failed to yield satisfactory results. Systemic therapy with etretinate was not attempted because of the liver cirrhosis. The lesions improved after topical treatment with 5-fluorouracil cream within 2 months.

DISCUSSION

Porokeratosis has mostly been seen in conjunction with a genetic predisposition and actinic damage. Since the report of the first case in 1974 after renal transplantation, several others have appeared in the literature where the condition was associated with immunosuppressive therapy (1–5).

More recently, it has been proposed that antibody-related autoimmune disease may trigger the onset of porokeratosis, with individual cases of porokeratosis being reported with associated immune complex glomerulonephritis (6), primary biliary liver cirrhosis (7) and end-stage liver disease (8). A recent review of porokeratosis in immunosuppressed and non-immunosuppressed patients showed that only a few patients with autoimmune diseases and porokeratosis Mibelli have been documented (9).

We present here a patient with two associated autoimmune

diseases, namely active chronic hepatitis and progressive vitiligo, who had not received immunosuppressive treatment. In patients with active chronic hepatitis, the association with autoimmune diseases, like insulin-dependent diabetes, autoimmune thyroid disease and vitiligo, is commonly found. In the sera of patients with chronic active hepatitis, organ-specific autoantibodies have been reported (10), and in the sera of patients with active vitiligo, antikeratinocyte antibodies have recently been identified (11). Thus, one may speculate that the impairment of humoral immunity might play a role in the pathogenesis of porokeratosis Mibelli.

REFERENCES

1. MacMillan AL, Roberts SOB. Porokeratosis of Mibelli after renal transplantation. *Br J Dermatol* 1974; 90: 45–54.
2. Lederman JS, Sober AJ, Lederman GS. Immunosuppression: a cause of porokeratosis? *J Am Acad Dermatol* 1985; 13: 75–79.
3. Neumann RA, Knobler RM, Metz D, Jurecka W. Disseminated superficial porokeratosis and immunosuppression. *Br J Dermatol* 1988; 119: 375–380.
4. Manganoni AM, Facchetti F, Gavazzoni R. Involvement of epidermal Langerhans cells in porokeratosis of immunosuppressed renal transplant recipients. *J Am Acad Dermatol* 1989; 21: 799–800.
5. Tsambaos D, Spiliopoulos T. Disseminated superficial porokeratosis: complete remission subsequent to discontinuation of immunosuppression. *J Am Acad Dermatol* 1993; 28: 651–652.
6. Foulds IS, Slater DN. Porokeratosis of Mibelli and immune complex glomerulonephritis. *Clin Exp Dermatol* 1983; 8: 69–73.
7. Venencie PY, Verola O, Puissant A. Porokeratosis in primary biliary cirrhosis during plasmapheresis. *J Am Acad Dermatol* 1986; 15: 719–720.
8. Hunt SJ, Sharra WG, Abell E. Linear and punctate porokeratosis associated with end-stage liver disease. *J Am Acad Dermatol* 1991; 25: 937–939.
9. Raychaudhuri SP, Smoller BR. Porokeratosis in immunosuppressed and non-immunosuppressed patients. *Int J Dermatol* 1992; 31: 781–782.
10. Homberg JC, Abuaf N, Bernard O, Islam S, Alvarez F, Khalil SH, et al. Chronic active hepatitis associated with antiliver/kidney microsome antibody type 1: a second type of "autoimmune" hepatitis. *Hepatology* 1987; 7: 1333–1339.
11. Hsin-Su Y, Chao-Hsing K, Chia-Li Y. Coexistence and relationship of antikeratinocyte and antimelanocyte antibodies in patients with non-segmental-type vitiligo. *J Invest Dermatol* 1993; 100: 823–828.