

IgG-Fc Receptors in Stratum Granulosum: An Immunological Defence in Human Skin?

JENS R. BJERKE¹, MAYA TIGALONOVA¹ and ROALD MATRE²

¹Department of Dermatology, Ullevaal Hospital, Oslo and ²Department of Microbiology and Immunology, The Gade Institute, University of Bergen, Norway

Receptors for the Fc-part of IgG (Fc γ R) in stratum granulosum of normal human skin were examined using cryosections and indirect immunofluorescence staining with 1) soluble immune complexes and 2) monoclonal antibodies (MoAbs) against different types of Fc γ R, i.e. 32.2 (anti-Fc γ I-CD64), IV.3 (anti-Fc γ RII-CD32) and Leu 11b (anti-Fc γ RIII-CD16). The immune complexes gave staining corresponding to stratum granulosum in sections from all skin specimens. Inhibition experiments showed that pre-incubation of the sections with monomeric and heat-aggregated human IgG, periodic acid and formaldehyde inhibited the immune complex binding. F(ab')₂ containing immune complexes did not bind to the skin sections. The MoAb 32.2 gave granular and Leu 11b linear staining corresponding to stratum granulosum. In addition, both IC, 32.2 and Leu 11b gave weaker staining of keratinocytes in other parts of the epidermis. IV.3 stained epidermal Langerhans' cells and were unreactive with other epidermal cells. Indirect immunofluorescence staining with MoAbs against IgG subclasses showed the presence of all IgG subclasses in stratum granulosum. The results show that granulosum cells express both high- and low-affinity IgG receptors and *in vivo* bound IgG. The data point to a role for stratum granulosum in cutaneous immunity. **Key words:** Fc γ -receptors; epidermis; skin barrier.

(Accepted April 18, 1994.)

Acta Derm Venereol (Stockh) 1994; 74: 429–432.

J.R. Bjerke, Department of Dermatology, Ullevaal Hospital, N-0407 Oslo, Norway.

Receptors for the Fc-part of IgG (Fc γ R) are present on most immunocompetent cells and constitute important links between humoral and cellular immunity. The receptors are involved in antibody-dependent cell-mediated cytotoxicity (1), in the release of cytokines (2) and in phagocytosis and endocytosis (1). Soluble Fc γ R is a mediator of immunomodulation (3). In addition, Fc γ R may be involved in active transcytosis of IgG across epithelia (4).

In the skin there are Fc γ R both on dermal and epidermal cells. The dermal macrophages express the strongest Fc γ R activity (5). In the epidermis, both Langerhans' cells (LC) and keratinocytes express weak Fc γ R activity that can be demonstrated *in situ* (6, 7) and in single cell suspension (8). The use of monoclonal antibodies (MoAbs) showed that the Fc γ R of LC and keratinocytes are of different types. The MoAb IV.3 against Fc γ RII (low-affinity type of Fc γ R, CD32) (2) reacts with LC (8), while Leu 11b against Fc γ RIII (low-affinity Fc γ R type, CD16) (2) and 32.2 against Fc γ RI (high-affinity Fc γ R, CD64) (2) react with keratinocytes (7). Leu 11b reacted particularly strongly with the stratum granulosum (7), indicating the presence of Fc γ RIII.

The aim of the present study was to further characterize Fc γ R

in stratum granulosum. The data obtained using MoAbs to various classes of Fc γ R and soluble immune complexes indicate that cells of stratum granulosum express Fc γ R, both the high- and low-affinity type (9). The possible role for stratum granulosum Fc γ R in the skin immune system is discussed.

MATERIAL AND METHODS

Tissues

Normal skin specimens, without any clinical sign of skin infection, were obtained from 8 healthy individuals undergoing surgical corrections in the retroauricular areas and upper eyelids. The specimens were kindly provided by the Department of Plastic Surgery. Normal placental tissue at term was provided by the Department of Gynecology and Obstetrics. The specimens were washed for 10 min in phosphate-buffered saline, pH 7.2 (PBS), embedded in Tissue-Tek II O.C.T compound (Lab-Tek Products, Naperville, Ill., USA) and quick-frozen in isopentane pre-chilled with liquid nitrogen. Cryostat sections were cut at 4–6 μ m and stored unfixed at –20°C until use. Some sections were washed in PBS for 1 h at room temperature before use.

Immunoglobulins

Antiserum to horseradish peroxidase (Type IV, Sigma, St. Louis, Mo., USA) was raised in rabbits, and IgG antibody to horseradish peroxidase was purified as described elsewhere (10). Rabbit F(ab')₂ was prepared as described by Stewart et al. (11). The MoAbs 32.2 (IgG1) against Fc γ RI (CD64) and IV.3 (IgG2b) against Fc γ RII (CDw32) were kind gifts from Dr. Anderson, Ohio State University, USA (12). The MoAb Leu 11b (IgM) against Fc γ RIII (CD16) was purchased from Becton and Dickinson, Sunnyvale, CA, USA. A murine MoAb (B1D6), isotypic as IgG1, against a placental Fc γ R was prepared according to the method described by Köhler & Milstein (13). This antibody reacts with a 40 kD low-affinity Fc γ R (14). MoAbs against IgG subclasses were purchased from Calbiochem, La Jolla, CA, USA. Fluorescein isothiocyanate (FITC)-conjugated IgG F(ab')₂ preparation of goat anti-mouse Ig, FITC-conjugated F(ab')₂ of goat anti-rabbit Ig and rabbit anti-human C1q were purchased from Behringwerke, Marburg-Lahn, Germany. Pooled native human IgG (Fraction II, 16.5% solution) was purchased from Kabi AB, Stockholm, Sweden. To remove aggregates the immunoglobulin preparations were centrifuged at 100 000 \times g for 1 h before use. Aggregation of IgG was performed by heating at 63°C for 15 min.

Immune complexes (IC)

IC were prepared by adding either dilutions of IgG-anti-horseradish peroxidase or the preparation of F(ab')₂ fragments to equal amounts of four-fold dilutions of horseradish peroxidase from 1 mg/ml in PBS. The mixtures were incubated for 2 h at room temperature before use. Complexes prepared at slight antigen excess were used (10).

Immunofluorescence staining

Cryostat sections were incubated with IC of horseradish peroxidase-anti-horseradish peroxidase for 45 min at room temperature followed by FITC-conjugated IgG F(ab')₂ of goat anti-rabbit IgG diluted 1:30 in PBS with 10% pooled human serum. Staining with MoAbs was performed by incubating the sections overnight at 4°C with the MoAbs diluted in PBS followed by incubation with FITC-conjugated F(ab')₂ of goat anti-mouse Ig diluted 1:32 in PBS for 45 min. The dilutions of anti-Fc γ R MoAbs mostly used were 32.2 1:32, IV.3 1:16, Leu 11b 1:64 and

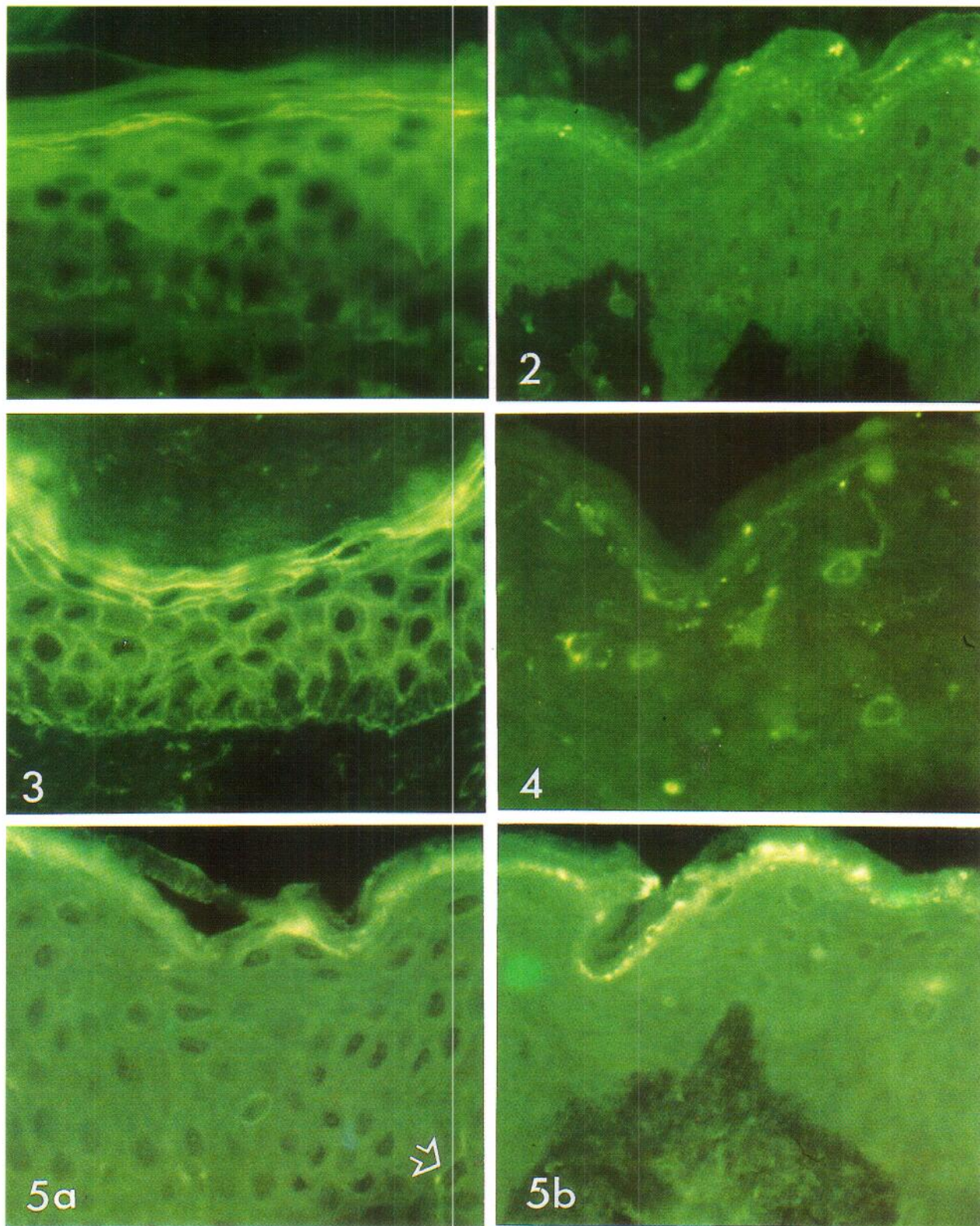


Fig. 1. Section of normal skin stained with immune complexes of horseradish peroxidase-anti-horseradish peroxidase. Staining localized to stratum granulosum. $\times 350$. - Fig. 2. Section of normal skin stained with MoAb against Fc γ RI (32.2). Granular staining is strongest in stratum granulosum but is also present in stratum corneum. $\times 350$. - Fig. 3. Section of normal skin stained with MoAb against FcRIII (Leu 11b). Strong linear staining in stratum granulosum and the upper part of stratum spinosum. $\times 350$. - Fig. 4. Section of normal skin stained with MoAb against Fc γ RII (IV.3). Staining localized to epidermal Langerhans' cells and to macrophage in the papillary dermis. $\times 350$. - Fig. 5. Sections of normal skin stained with MoAbs against IgG subclasses. (a) Anti-IgG1 staining stratum granulosum and also weakly dendritic epidermal cell (arrow). (b) Anti-IgG3 staining stratum granulosum. $\times 350$.

Table I. Binding of soluble immune complexes to stratum granulosum in cryostat sections of normal skin pre-incubated with human IgG (mg/ml), periodic acid (mM) and formaldehyde (%)

Pre-incubation with	Concentrations					PBS
	1	2	4	8	16	
IgG						
heat-aggregated	3+ ^a	2+	2+	1+	1+	3+
native	3+	3+	3+	2+	2+	3+
Periodic acid	2+	2+	1+	-	n.t.	3+
Formaldehyde	2+	2+	1+	-	n.t.	3+

^aStaining intensity

3+ = moderate

2+ = weak

1+ = very weak

- = not stained

n.t. = not tested

BID6 1:64. The MoAbs against IgG subclasses were used in dilution 1:200–500. In some experiments the MoAbs were diluted in PBS containing 1% rabbit IgG. Each incubation was followed by two gentle washings for 10 min in PBS at room temperature. The sections were finally mounted in PBS-glycerol with 0.1% paraphenylenediamine, pH 8.6, as anti-fading agent (15), and examined in a Zeiss fluorescence microscope with an 150 W Xenon lamp.

Control sections were incubated with IC containing F(ab')₂ fragments of IgG anti-horseradish peroxidase or horseradish peroxidase alone and further processed as described above. In other control experiments the sections were incubated with PBS instead of either IC of horseradish peroxidase anti-horseradish peroxidase or MoAb. Cryostat sections were also incubated with other mouse MoAbs or with normal mouse serum (1:16) as isotypic controls. As positive control the reactivity of IC with cryostat sections of placental tissue was examined (10).

Characterization experiments

Cryostat sections were first incubated with two-fold dilutions (1–16 mg/ml) of either heat-aggregated or native IgG at room temperature for 60 min and washed in PBS at room temperature for 30 min. Then the sections were incubated with IC. Some sections were pre-incubated for 1 h at room temperature with rabbit antiserum to human C1q diluted 1:4 in PBS before staining with IC.

Cryostat sections were also pre-treated with 0.5, 1, 2, 4 and 8 mM periodic acid in PBS for 30 min at room temperature, or with 0.5, 1, 2, 4 and 8% formaldehyde in PBS for 10 min. Control sections were treated with PBS. The treated sections were washed in PBS for 20 min before being examined for FcR activity as described above.

RESULTS

IC of horseradish peroxidase-anti-horseradish peroxidase gave staining corresponding to stratum granulosum in sections from all skin specimens (Fig. 1). IC prepared with F(ab')₂ fragments of IgG anti-horseradish peroxidase did not bind, indicating that the binding of IC is dependent on an intact Fc portion of the antibody molecule.

32.2 gave granular and Leu 11b mainly linear staining corresponding to stratum granulosum in all sections (Figs. 2 and 3). There was only a minor difference in staining intensity between sections from the 8 biopsies studied. The staining was strong, present up to a dilution of 1:256 of 32.2 and 1:2048 of Leu 11b.

In addition, the IC and MoAbs stained other parts of the epidermis, as previously described (7). IC stained LC and a few keratinocytes, and both 32.2 and Leu 11b gave a moderate

strong staining of keratinocytes in the spinous and basal layer. In the epidermis IV.3 stained LC only (Fig. 4). BID6 gave membrane staining of keratinocytes in the lower part of the epidermis, but only weak staining in the stratum granulosum.

There was reduced binding of IC to sections pre-incubated with human IgG (Table I). Heat-aggregated IgG had a stronger inhibiting effect than native IgG. However, neither of the IgG preparations gave complete inhibition. Incubation with anti-C1q did not affect the binding of IC. The IC binding was completely inhibited by pre-treating the skin sections with periodic acid or formaldehyde at concentrations of 8 mM and 8%, respectively (Table I). Both 32.2 and Leu 11b gave weaker staining with sections pre-treated with 4 mM periodic acid or with 4% formaldehyde.

There was no staining of cryosections incubated with PBS instead of IC. Nor was there any staining of sections incubated with PBS or normal mouse serum instead of MoAbs. None of the isotype control MoAbs gave epidermal staining. In sections from human normal placenta IC bound to trophoblasts and to endothelial cells of fetal stem vessels, as previously described (10).

All MoAbs against IgG subclasses stained the subcorneal layer. Anti-IgG1 gave the strongest staining, followed by anti-IgG3 (Fig. 5). In addition, all anti-IgG subclass MoAbs gave some staining in stratum corneum and occasional staining of epidermal cells with a dendritic pattern. MoAbs diluted in PBS with 1% rabbit IgG gave similar staining.

DISCUSSION

The results presented strongly indicate that the subcorneal layer of normal skin expresses Fc τ R. This was shown by two different methods: first, the binding of soluble IC, which is a functional assay, and second, the use of MoAbs detecting epitopes on Fc τ R. The receptors have antigenic similarities with both the high- and low-affinity type of Fc τ R, since there was staining with 32.2 (anti-Fc τ RI) and Leu 11b (anti-Fc τ RIII).

Human IgG did not completely inhibit the IC binding, indicating that human IgG and IC of horseradish peroxidase-anti-horseradish peroxidase have different binding affinity to Fc τ R in stratum granulosum or partly bind to different receptor molecules. Results of experiments with periodic acid and formaldehyde showed that Fc τ R in the subcorneal layer share physicochemical properties with Fc τ R in other parts of the skin (6, 16, 17) and other organs (18–20).

Fc τ R mediate several biological functions in the immune system (21), and their presence close to the skin surface may have important functional consequences. The receptors may be involved in several ways under physiological as well as pathological conditions:

First, it is possible that with the capacity to bind IC and IgG against harmful antigens the receptors are protective. This would make the stratum granulosum not only a physicochemical but also an immunological barrier preventing infection and the penetration of microbial antigens and in particular superantigens that may induce skin inflammation. Though the specificity of IgG demonstrated in stratum granulosum of clinically non-infected skin is unknown, the *in vivo* presence of all IgG sub-

classes in this skin layer favours the hypothesis of stratum granulosum Fc γ R as a front line of immune defence in human skin.

Circulating auto-antibodies against stratum corneum normally occur (22). Normal skin is protected against potentially detrimental stratum corneum antibodies probably because the stratum corneum antigens are hidden (23). The stratum granulosum Fc γ R might be part of this physiological barrier between IgG stratum corneum antibodies and stratum corneum antigens. An impaired stratum granulosum barrier caused by small traumata would permit IgG stratum corneum antibodies to reach stratum corneum and trigger the development of early pin-point lesions in a skin disorder like psoriasis.

Bacteria and fungi from the surface of normal skin are covered by immunoglobulins (24). Both IgA and secretory component are probably brought to the surface through the eccrine system (24). How IgG reaches the surface of normal skin has not been determined. As Fc γ R are probably involved in IgG transport over other epithelial structures, e.g. trophoblasts in placenta (19) and choroid plexus (20), it is also possible that the epidermal Fc γ R, most strongly expressed in stratum granulosum, may play a role in transport of IgG through epidermis.

Fc γ R binding may give unwanted staining in stratum granulosum unless F(ab')₂ fragments are used or other precautions are taken in order to avoid Fc γ R binding. The presence of high- and low-affinity Fc γ R in stratum granulosum may be of significance for the affinity of stratum granulosum for antibody-fluorescein conjugates (25). The detection of Fc γ R activity in stratum granulosum offers an explanation of the well-known antigen-nonspecific affinity for labelled antibodies to the stratum granulosum often found in routine immunofluorescence testing (25). The dendritic epidermal cells positive for IgG probably represent LC.

IgG binding to Fc γ R can mediate the release of cytokines (2). In addition to cells in stratum granulosum, there is Fc γ R activity also on LC and keratinocytes. IgG binding to Fc γ R could be of importance in the secretion of cytokines by these cells. The wide distribution of receptors for IgG in normal epidermis, with the strongest activity in the subcorneal layer, points to an active physiological role of IgG and its receptors in the skin immunity system. The surface IgG and the stratum granulosum Fc γ R could comprise a humoral defence system in normal skin, with a parallel to the IgA secretory component system in the gut. How the interaction between IgG isotypes and cytokines, connecting humoral and cellular immunity, is co-ordinated is an important question for further work.

ACKNOWLEDGEMENT

This work was supported by grants from The Norwegian Psoriasis Association and Leo Pharmaceutical Products Trading, Norway. Thanks are due to Dr. C. L. Anderson, Ohio State University, USA, for the kind gifts of the monoclonal antibodies 32.2 and IV.3.

REFERENCES

- Fanger MW, Shen L, Graziano RF, Guyre PM. Cytotoxicity mediated by human Fc receptors for IgG. *Immunol Today* 1989; 10: 92–99.
- Van de Winkel JGJ, Capel PJA. Human IgG Fc receptor heterogeneity: molecular aspects and clinical implications. *Immunol Today* 1993; 14: 215–221.
- Fridman WH, Teillaud JL, Bouchard C, et al. Soluble Fc γ -receptors. *J Leuk Biol* 1993; 54: 504–512.
- Matre R, Tønder O, Endresen C. Fc receptors in human placenta. *Scand J Immunol* 1975; 4: 741–745.
- Bjerke JR, Krogh HK, Matre R. Fc γ -receptors in normal and lesional skin. In: Mac Donald DM, ed. *Immunodermatology*. London: Butterworths, 1984: 75–77.
- Tigalonowa M, Bjerke JR, Matre R. Fc γ -receptor as a functional marker on Langerhans' cells *in situ*. *Acta Derm Venereol (Stockh)* 1989; 69: 477–481.
- Tigalonowa M, Bjerke JR, Livden JK, Matre R. The distribution of Fc γ RI, Fc γ RII and Fc γ RIII on Langerhans' cells and keratinocytes in normal skin. *Acta Derm Venereol (Stockh)* 1990; 70: 385–390.
- Tigalonowa M, Bjerke JR, Matre R. Fc γ -receptors on Langerhans' cells and keratinocytes in suspension from normal skin characterized using soluble immune complexes and monoclonal antibodies. *Acta Derm Venereol (Stockh)* 1991; 71: 99–103.
- Andersson CL, Looney RJ. Human leukocyte IgG Fc receptors. *Immunol Today* 1980; 7: 264–266.
- Matre R, Haugen A. The placental Fc γ -receptors studied using immune complexes of peroxidase. *Scand J Immunol* 1978; 8: 187–193.
- Stewart GA, Smith AK, Stanworth DR. Biological activities associated with the Fc γ fragment of rabbit IgG. *Immunochemistry* 1973; 10: 755–760.
- Ravech JV, Anderson CL. Fc γ R family: proteins, transcripts, and genes. In: Metzger H, ed. *Fc receptors and the action of antibodies*. Washington D.C.: American Society for Microbiology, 1990: 211–235.
- Köhler G, Milstein C. Continuous cultures of fused cells secreting antibodies of predefined specificity. *Nature* 1975; 256: 495–497.
- Matre R, Kristoffersen EK, Ulvestad E, Vedeler CA. Purification of a 40 kD human placental Fc γ -receptor using a monoclonal antibody. *Acta Path Microbiol Immunol Scand* 1989; 97: 733–737.
- Johnson GD, Nogueira Araujo GM de C. A simple method of reducing the fading of immunofluorescence during microscopy. *J Immunol Methods* 1981; 43: 349–350.
- Bjerke JR, Krogh H-K, Matre R. Factors mediating the binding of immune complexes to cryostat sections of psoriatic lesions. *Int Archs Allergy Appl Immunol* 1982; 68: 358–364.
- Livden JK. Fc γ -receptors on keratinocytes in psoriasis. *Arch Dermatol Res* 1988; 280: 12–17.
- Matre R, Tønder O, Thunold S, Solhaug JH. Properties of Fc γ -receptors in normal and malignant tissues. *Scand J Immunol* 1976; 5: 361–368.
- Matre R. Similarities of Fc γ -receptors on trophoblasts and placental endothelial cells. *Scand J Immunol* 1977; 5: 96–968.
- Nyland H, Matre R. Fc γ -receptors in human choroid plexus. *Acta Path Microbiol Scand Sect C* 1978; 86: 141–143.
- Van de Winkel JGJ, Anderson CL. Biology of human immunoglobulin G Fc receptors. *J Leuk Biol* 1991; 49: 511–524.
- Krogh HK, Tønder O. Immunoglobulins and anti-immunoglobulin factors in psoriatic lesions. *Clin Exp Immunol* 1972; 10: 623–633.
- Beutner EH, Kumar V, Jablonska S, Jones PC. Nature and function of stratum corneum/keratinocyte cytoplasm autoantibodies and their antigens. In: Beutner EH, Chorzelski TP, Kumar V, eds. *Immunopathology of the skin*. New York: Churchill Livingstone, 1987: 681–702.
- Metze D, Kersten A, Jurecka W, Gebhart W. Immunoglobulins coat microorganisms of skin surface: a comparative immunohistochemical and ultrastructural study of cutaneous and oral microbial symbionts. *J Invest Dermatol* 1991; 96: 439–445.
- Parish WE. Immunofluorescence. In: Rook A, Wilkinson DS, et al., eds. *Textbook of dermatology*. Oxford: Blackwell Scientific Publications, 1992: 180–194.