

LETTERS TO THE EDITOR

Segmental Neurofibromatosis Presenting as a Giant Naevus Spilus

Sir,

A 41-year-old woman presented at our department in a follow-up procedure after removal of a melanoma in situ from her right mamma. A huge café-au-lait spot with numerous naevocellular naevi (naevus spilus) was observed on her left hip, left thigh and left calf. The naevus spilus was strictly limited to the left side of her body by the mid-line. At the level of the navel the naevus was limited to normal skin by a horizontal line; it did not follow dermatomal distribution (Fig. 1a). According to the patient, this naevus had developed during early childhood. She also told us that she had been complaining of back pain for several years. An X-ray of her spine revealed a malformation of the fifth lumbar vertebra, and a shortening of her left extremity by 1 cm (see Fig. 2b). A computerized tomographic investigation of her head and spine did not show any tumorous changes. The ophthalmologic investigation concluded with normal findings. There were no further café-au-lait spots, no axillary freckling, no history of similar skin changes in her family. Histologic examination of a skin biopsy confirmed the diagnosis of a café-au-lait spot (lentiginous hyperplasia) with naevocellular naevi.

Neurofibromatosis is divided into 8 subgroups, NF I being the classical Mb. Recklinghausen, and NF V being the segmental form. The other 5 subgroups are defined clinically. Approximately 50 cases of segmental neurofibromatosis have been described in the literature, 6 of them without cutaneous or other neurofibromas (1-4).

REFERENCES

1. Nicholls EM. Somatic variation and multiple neurofibromatosis. *Hum Hered* 1969; 19: 473-479.
2. Riccardi VM. Neurofibromatosis: clinical heterogeneity. *Curr Prob Cancer* 1982; 7: 1-34.
3. Weleber RG, Zonana J. Iris hamartomas (Lisch nodules) in a case of segmental neurofibromatosis. *Am J Ophthalmol* 1983; 96: 740-743.
4. Gerhards G, Hamm H. Die unilaterale Lentiginose - eine segmentale Neurofibromatose ohne Neurofibrome. *Hautarzt* 1992; 43: 491-495.
5. Hughes GS, Kim Park H, Jones BE. Partial unilateral lentiginosis in a black patient with sickle cell anemia. *J Am Acad Dermatol* 1983; 8: 563-565.
6. Thompson GW. Partial unilateral lentiginosis. *Arch Dermatol* 1980; 116: 356.

Received January 24, 1994

Edgar Selvaag¹, Per Thune¹ and Tove Eeg Larsen², Departments of ¹Dermatology and ²Pathology, Ullevaal Hospital, University of Oslo, Oslo, Norway.

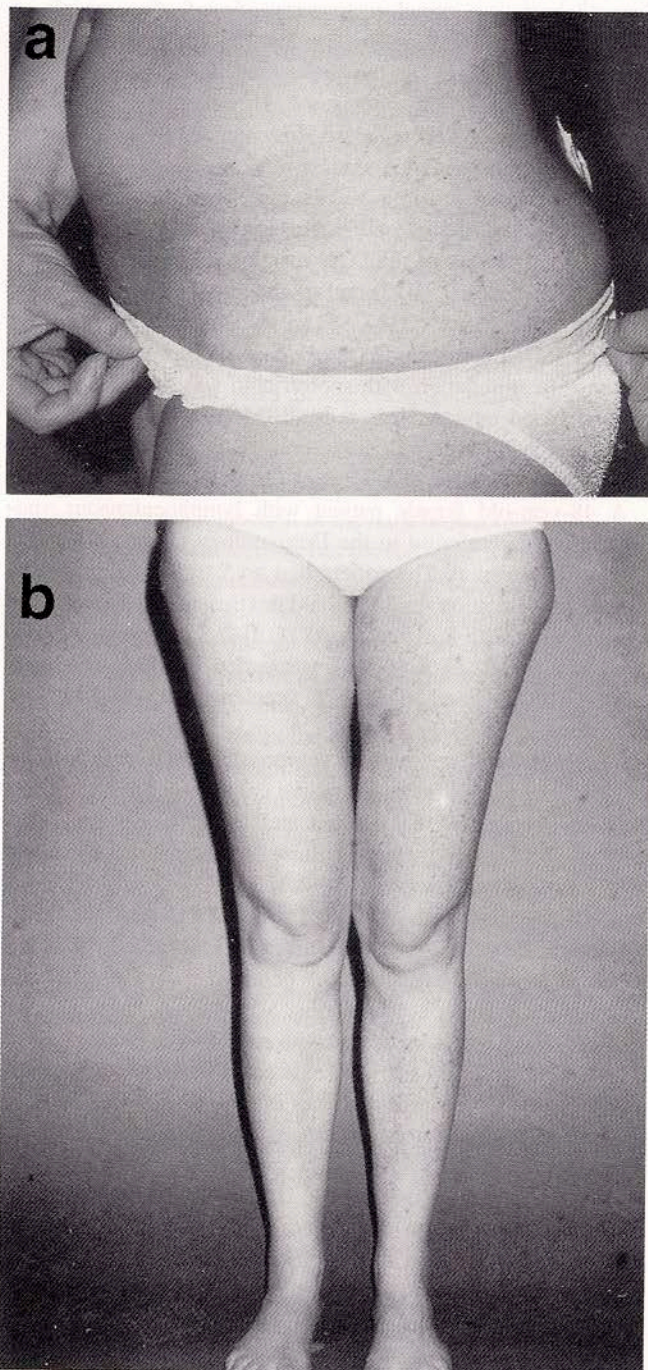


Fig. 1. (a) Giant café-au-lait spot with numerous naevocellular naevi (naevus spilus) strictly confined to the patient's left hip, left thigh and left calf by the mid-line. (b) Note the shortening of the patient's left leg.