

Pruritic Papular Eruption of the Acquired Immunodeficiency Syndrome

NORIHISA ISHII¹, TAKAFUMI NISHIYAMA¹, YASUYUKI SUGITA¹, HIROSHI NAKAJIMA¹ and ICHIRO AOKI²

Departments of ¹Dermatology and ²Pathology, Yokohama City University School of Medicine, Yokohama, Japan

We report a case of acquired immunodeficiency syndrome with pruritic papular eruption. The patient, a hemophiliac, presented with generalized pruritic, skin-colored papules and nodules. The chronic lesions were excoriated and hyperpigmented. The eosinophil count was elevated, but IgE was normal. The lesions and pruritus responded only to ultraviolet B phototherapy. While the mechanism is not known, ultraviolet B phototherapy may provide relief of AIDS-related pruritus. Key words: eosinophilia; hemophiliac; human immunodeficiency virus; ultraviolet B phototherapy.

(Accepted November 15, 1993.)

Acta Derm Venereol (Stockh) 1994; 74: 219–220.

N. Ishii, Department of Dermatology, Yokohama City University School of Medicine, 3–9 Fukuura, Kanazawa-ku, Yokohama 236, Japan.

The acquired immunodeficiency syndrome (AIDS), which occurs after infection by human immunodeficiency virus (HIV), is characterized by CD4⁺ T cell depletion, opportunistic infections and certain malignancies. Skin disorders commonly associated with HIV infection include seborrheic dermatitis, molluscum contagiosum, herpes simplex, syphilis, tinea corporis and Kaposi's sarcoma (1–3). Pruritic papular eruption (PPE) in patients who test positive for HIV is characterized by chronic pruritus and a papular eruption on the trunk and extremities (2, 4–8). Intense scratching produces multiple excoriations, prurigo-like nodules and numerous areas of postinflammatory hyperpigmentation. PPE has been described in Africans and Haitians (5), but there is no previous report on Japanese AIDS patients. We describe the clinical, histopathological and therapeutic aspects of PPE in a Japanese patient with AIDS.

CASE REPORT

This 38-year-old Japanese man was referred to the dermatology clinic at Yokohama City University Hospital in March, 1992. He suffered from hemophilia B and had become infected with HIV through the administration of coagulation factor concentrates imported mainly from the United States.

Serological examinations using ELISA (antigen, antibody, envelope, core), particle agglutination test, indirect fluorescence antibody and Western blotting of HIV (gp160, 120, 65, 55, 41–43, 32, 24, 18) were all positive for HIV infection.

Laboratory testing revealed mild anemia and a white blood cell count of approximately 5,000/mm³. The CD4/CD8 ratio was between 0.00 and 0.03, and the CD4-positive T cells numbered between 6 and 19/mm³. Serum IgE was normal and RAST using any antigen was negative. Serum eosinophils were increased to 8–20%. Repeated liver function testing revealed persistent elevations of serum GOT, GPT and gamma GTP. Serum electrolytes, urea, and creatinine were all within normal limits, and VDRL and FTA were non-reactive. *Demodex* mite or *Pityrosporum orbiculare/ovale* was not observed.

The patient was diagnosed as having HIV encephalopathy in July,

1992. He was classified as having AIDS (group IV-B). Skin involvement included condyloma acuminatum and a persistent phlegmon on the left lateral crural region. Starting in November, 1992, he received azidodeoxythymidine (AZT) for a few months, but without benefit.

Ever since his initial visit, the patient had exhibited small, firm, well-demarcated, skin-colored papules (usually 1–8 mm) symmetrically distributed on the trunk, extremities and face. There were no lesions on the palms, soles, or between the digits. Intense pruritus usually began with the appearance of the lesions. Scratching led to excoriations, prurigo-like lesions and marked post-inflammatory hyperpigmentation (Fig. 1).

Biopsy specimens taken from the prurigo-like eruption on the right lateral brachial region showed a moderately intense perivascular infiltrate composed of mononuclear cells without eosinophils. Other changes included mild papillary dermal edema, pigmentation and mild swelling of endothelial cells. Commensals were not revealed in the specimens. We diagnosed these lesions as PPE. The lesions and pruritus failed to respond to the topical administration of corticosteroids, crotamiton cream or emollients, or to oral antihistamines or dapsone. Light treatment was given 8 times for 1 month using an ultraviolet B (UVB) lamp (FL205·E – 30/DMR, Clinical Supply, Tokyo, Japan).

The initial UVB dose was 67% of the minimal erythematous dose (MED, 91 mJ/cm²) and was increased by 5% of the total dose at each treatment. The severity of the pruritus diminished after a few treatments. New prurigo-like eruptions disappeared with UVB treatment.

UVB was discontinued after 1 month because of severe fatigue with fever and hypoxia. The patient died of HIV encephalopathy and *Pneumocystis carinii* pneumonia in June, 1993. At that time he had no pruritus or prurigo-like eruptions.

DISCUSSION

We have reported an AIDS patient with PPE. As compared with the incidence of HIV in other developed countries, relatively few patients are infected with HIV in Japan (3,084 as of October 1993) including AIDS patients, 56% of whom are hemophiliacs. Recently, the transmission of HIV has been predominantly

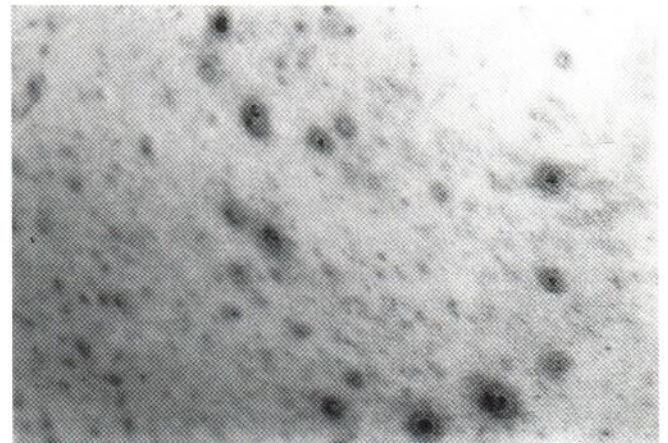


Fig. 1. Multiple hyperpigmented maculopapular eruptions and excoriations on the trunk.

heterosexual in Japan, involving female prostitutes from regions of high incidence in East Asia (3).

A variety of skin diseases have been associated with HIV infection, including candidiasis, seborrheic dermatitis, chronic herpes simplex infection and Kaposi's sarcoma, as well as other less common skin disorders (1,2). Such diseases can be particularly aggressive in patients with clinically evident HIV infection. Our patient exhibited oral candidiasis and condyloma acuminatum, important markers for AIDS. PPE, recently associated with AIDS (2,4-8), was also present.

Clinically, our case showed the papular lesions and distribution typical of PPE. Histological findings in PPE show a superficial and mid-dermal mixed perivascular and perifollicular infiltrate consisting of lymphocytes and eosinophils, with various degrees of follicular damage (7). We observed no eosinophils in the infiltrate. However, hyper eosinophilia was observed in the blood. There was no correlation between the density of eosinophils in tissue and the blood eosinophil count. A chronic type of PPE, prurigo simplex, has histologic features similar to PPE but without a prominent eosinophilic infiltrate (9). However, Hevia et al. (7) described one case without the eosinophilic infiltrate; they believe that the lack of an eosinophilic infiltrate does not support a diagnostic subdivision of PPE. Therefore, our patient showed the typical clinical, but not the histological, findings of PPE.

Ofuji's disease, or eosinophilic pustular folliculitis has been reported in AIDS patients (10,11). Findings in our patient did not resemble this disease either clinically or histopathologically. The cause of PPE is unknown. It is hypothesized that it represents an immune response to the HIV itself (2,5). It is prudent to recommend a complete dermatologic evaluation of patients with AIDS or AIDS-related complex (ARC) (2,7).

The PPE lesions responded only to UVB phototherapy. Our patient was subsequently hospitalized; the administration of UVB phototherapy twice weekly for 4 weeks greatly improved his skin condition. Its mechanism(s) in relieving the pruritus of PPE is unknown. However, it is also effective in treating the generalized pruritus associated with uremia (12) and cholestatic liver disease (13), again by an unclear mechanism of action. There are only a few reports in the literature describing a favorable response to UVB therapy in HIV-positive patients with generalized idiopathic pruritus (8,14). Gorin et al. (15) reported the relief of generalized pruritus in an AIDS patient using psoralen and ultraviolet A (PUVA) therapy. The successful use of UVB therapy in treating pustular folliculitis has also been reported (10).

The evidence indicates that UVB light is a potent immunomodulatory agent (16,17). For example, epidermal Langerhans' cells (16), dermal endothelial cells and mast cells (17) become significantly modified both in their appearance and immune function following exposure to UVB light. Low-dose UVB light inhibits contact hypersensitivity in experimental models (18). Pardo et al. (8) reported that the number of T cells within the lesions of PPE was reduced after UVB phototherapy of PPE with AIDS.

The risks of phototherapy are well known (16,17). For exam-

ple, an increase in the incidence of cutaneous malignancies following UV therapy would not be unexpected, particularly in HIV-positive patients who are already immunosuppressed. Despite the inherent risk, the dramatic response of our patient indicates that UVB phototherapy warrants further study as a treatment option in AIDS-related pruritus.

REFERENCES

- Kaplan MH, Sadick N, McNutt NS, Meltzer M, Sarngadharan MG, Pahwa S. Dermatologic findings and manifestations of acquired immunodeficiency syndrome (AIDS). *J Am Acad Dermatol* 1987; 16: 485-506.
- Goodman DS, Teplitz ED, Wishner A, Klein RS, Burk PG, Hershenbaum E. Prevalence of cutaneous disease in patients with acquired immunodeficiency syndrome (AIDS) or AIDS-related complex. *J Am Acad Dermatol* 1987; 17: 210-220.
- Ishii N, Ichiyama S, Nakajima H, Ito A. Sexually transmitted diseases in an HIV infected patient. *J Dermatol* 1993; 20: 171-174.
- James WD, Redfield RR, Lupton GP, Meltzer MS, Berger TG, Rodman OG, et al. A papular eruption associated with human T cell lymphotropic virus type III disease. *J Am Acad Dermatol* 1985; 13: 563-566.
- Colebunders R, Mann JM, Francis H, Bila K, Izaley L, Kakonde N, et al. Generalized papular pruritic eruption in African patients with human immunodeficiency virus infection. *AIDS* 1987; 1: 117-121.
- Liautaud B, Pape JW, DeHovitz JA, Thomas F, LaRoche AC, Verdier RI, et al. Pruritic skin lesions. A common initial presentation of acquired immunodeficiency syndrome. *Arch Dermatol* 1989; 125: 629-632.
- Hevia O, Jimenez-Acosta F, Ceballos PI, Gould EW, Penneys NS. Pruritic papular eruption of the acquired immunodeficiency syndrome: a clinicopathologic study. *J Am Acad Dermatol* 1991; 24: 231-235.
- Pardo RJ, Bogaert MA, Penneys NS, Byrne Jr GE, Ruiz P. UVB phototherapy of the pruritic papular eruption of the acquired immunodeficiency syndrome. *J Am Acad Dermatol* 1992; 26: 423-428.
- Uehara M, Ofuji S. Primary eruption of prurigo simplex subacuta. *Dermatologica* 1976; 153: 49-56.
- Buchness MR, Lim HW, Hatcher VA, Sanchez M, Soter NA. Eosinophilic pustular folliculitis in the acquired immunodeficiency syndrome. *N Engl J Med* 1987; 318: 1183-1186.
- Jenkins Jr D, Fisher BK, Chalvardjian A, Adam P. Eosinophilic pustular folliculitis in a patient with AIDS. *Int J Dermatol* 1988; 27: 34-35.
- Gilchrest BA, Rowe JW, Brown RS, Steinman TI, Arndt KA. Ultraviolet phototherapy of uremic pruritus. Long-term results and possible mechanism of action. *Ann Intern Med* 1979; 91: 17-21.
- Denman ST. A review of pruritus. *J Am Acad Dermatol* 1986; 14: 375-392.
- Weiss DS, Taylor JR. Treatment of generalized pruritus in an HIV-positive patient with UVB phototherapy. *Clin Exp Dermatol* 1990; 15: 316-317.
- Gorin I, Lessana-Leibowitch M, Fortier P, Leibowitch J, Escande JP. Successful treatment of the pruritus of human immunodeficiency virus infection and acquired immunodeficiency syndrome with psoralens plus ultraviolet A therapy. *J Am Acad Dermatol* 1989; 20: 511-513.
- Greene MI, Sy MS, Kripke M, Benacerraf B. Impairment of antigen-presenting cell function by ultraviolet radiation. *Proc Natl Acad Sci USA* 1979; 76: 6591-6595.
- Scheibner A, Hollis DE, McCarthy WH, Milton GW. Effects of sunlight exposure on Langerhans cells and melanocytes in human epidermis. *Photodermatology* 1986; 3: 15-25.
- Streilein JW, Bergstresser PR. Genetic basis of ultraviolet-B effects on contact hypersensitivity. *Immunogenetics* 1988; 27: 252-258.