

## Pachydermodactyly: Report of Two Cases

I. YANGUAS, J. J. GODAY and R. SOLOETA

Department of Dermatology, Hospital Santiago Apostol, Vitoria, Spain

**Pachydermodactyly is a rare and benign form of digital fibromatosis with only a few cases described in the literature. We report two cases of pachydermodactyly affecting young men. In one of them a knuckle pad was found, and the fibromatous thickening of the skin affected not only the finger joints but also the dorsum of the hands. This case can be included in the particular clinical form named pachydermodactyly trans-grediens. Key word: digital fibromatosis.**

(Accepted November 1, 1993.)

Acta Derm Venereol (Stockh) 1994; 74: 217-218.

I. Yanguas, Servicio de Dermatología, Hospital Santiago Apostol, C/Olaguibel 29, 01004 Vitoria, Spain.

Pachydermodactyly is a rare and benign form of digital fibromatosis. It affects young males, and it is characterized by acquired asymptomatic swelling around one or more proximal phalanges or proximal interphalangeal joints. Histological findings include a marked thickening of the dermis with extension of collagen fibers into the subcutaneous tissue.

We here present two cases of pachydermodactyly involving both hands.

### CASE REPORT

#### Case 1

A 17-year-old white man had a 2-year history of asymptomatic, diffuse swelling affecting dorsal and lateral sides of proximal interphalangeal joints at the 2nd, 3rd, and 4th fingers of both hands with slight involvement of the 5th finger. The lesions were much more evident on his left hand (Fig. 1).

The swellings were painless and he had correct motion of all his joints. They appeared as smooth, fusiform, padlike swellings over the dorsal and lateral sides of the affected fingers.

The skin of his left hand was hyperkeratotic, brown-coloured, with areas of mild erythema, extending to the areas of the metacarpophalangeal joints, and it was freely mobile.

A skin biopsy specimen revealed hyperkeratosis and acanthosis; the dermis was markedly thickened with an increased amount of collagen

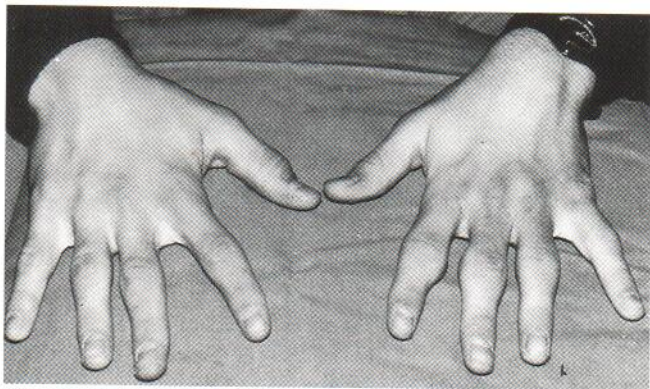


Fig. 1. Case 1. Fusiform swellings around the proximal interphalangeal joints from the 2nd to 5th finger, affecting both hands.

bundles, which extended into the subcutaneous fat (Fig. 2). Fibroblasts had no eosinophilic cytoplasmic inclusions, and there was no inflammatory infiltrate.

#### Case 2

An 18-year-old white man consulted us because of swellings of his fingers since the age of 10.

He had painless swellings over the dorsal and lateral sides of the proximal interphalangeal joints from the 2nd to 5th fingers of his right hand. On his left hand the lesions were only limited to the 2nd and 3rd proximal interphalangeal joints; the lesional clinical appearance of his 3rd finger was very similar to that of a knuckle pad (Fig. 3).

Skin changes were not only limited to the proximal interphalangeal joints; there was important fibromatous thickening of the overlying skin of the 2nd and 3rd metacarpophalangeal joints extending to the dorsal aspect of both hands. There was no movement limitation of his fingers.

The histological findings were similar to those of Case 1. In both cases the thumbs and toes were spared, and the patients denied continuous trauma or pressure over the involved areas. The general clinical examination showed normal findings and routine laboratory screening was normal. Roentgenograms of the hands showed soft-tissue swelling with no bone or articular abnormalities. The patients' family histories were non-contributory.

They both refused any method of surgical or chemical treatment.

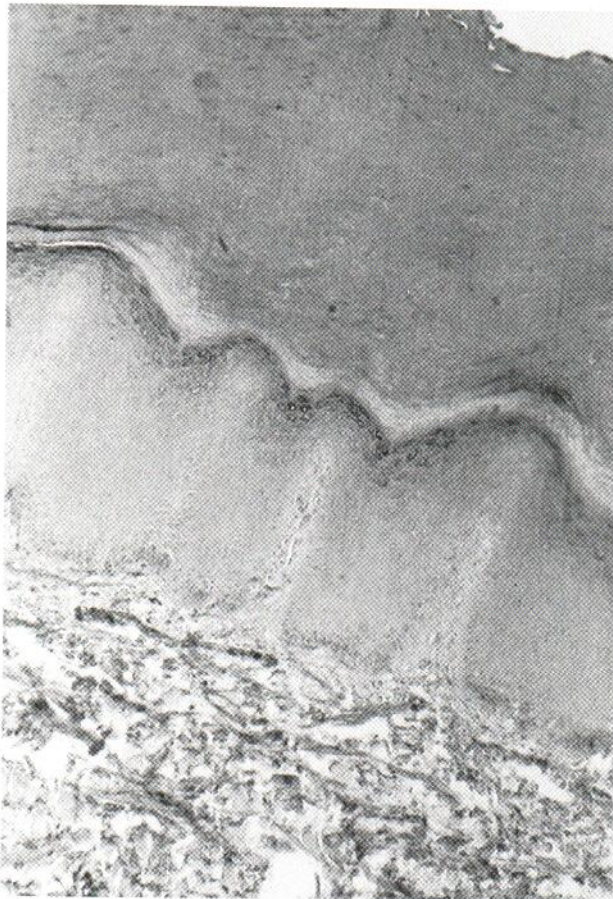

Fig. 2. Hyperkeratosis and acanthosis. Dermis is thickened by irregular bundles of collagen.

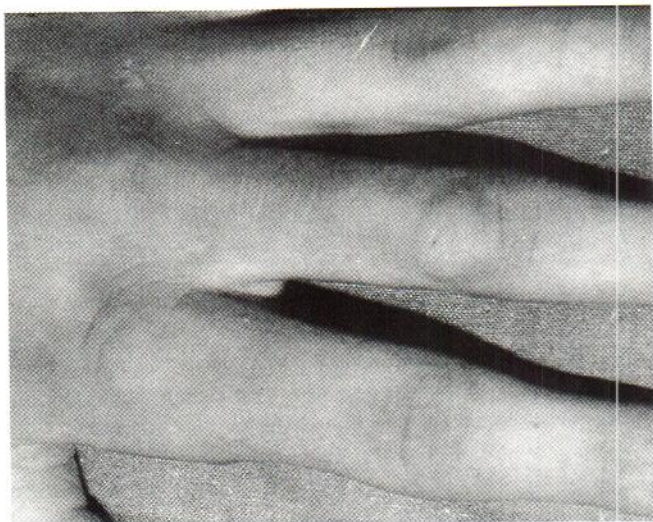

Fig. 3. Case 2. Left hand of the patient. Circumscribed fibromatous thickening over the dorsa of the proximal interphalangeal joint of the 3rd finger. Cutaneous thickness extended to the metacarpophalangeal areas and dorsum of the hand.

## DISCUSSION

We have only found 16 previous cases reported in the literature (1–11). This entity was initially considered as a variant of knuckle pad, as they share some clinical features such as location and fibrosis (1). However, pachydermodactyly affects preferably young men, whereas knuckle pad afflicts both men and women of almost any age. Moreover the latter does not involve the lateral sides of the fingers as pachydermodactyly does.

Pachydermodactyly belongs to the clinical spectrum of fibromatosis, and one patient with pachydermodactyly and Dupuytren's contracture has been reported (3). Our Case 2 showed the presence of a knuckle pad on one finger. This finding has to our knowledge not been previously reported.

Sola et al. (9) reported a case in which skin changes were also found on the metacarpophalangeal areas. Our Case 2 is very

similar, with cutaneous thickness extended to the dorsal aspect of his hands.

In most cases some epidermic alteration has been described. It has been defined as "thickened and craky", "slightly hyperkeratotic", "somewhat scaly", or "lichenification" (3, 4, 8, 10), in the same way as the left hand of Case 1.

There is no standard and effective treatment, and in most cases no therapy has been tried. Intralesional corticosteroids have been effective in some patients (5, 7), but not in others (4), and excision of the excess tissues has been used with varying success (2, 6). In one patient, the swellings underwent complete regression with the interruption of the sport activity that had subjected his fingers to continuous pressure (11).

## REFERENCES

1. Verbov J. Pachydermodactyly: a variant of the true knuckle pad. *Arch Dermatol* 1975; 111: 524.
2. Fleeter TB, Myrie C, Adams JP. Pachydermodactyly: a case report and discussion of pathologic entity. *J Hand Surg Am* 1984; 9: 764–766.
3. Reichert CM, Costa J, Barsky SH, Claysmith AP, Liotta LA, Enzinger FM, et al. Pachydermodactyly. *Clin Orthoped* 1985; 194: 252–257.
4. Kouskousis CE. Stump the experts. *J Dermatol Surg Oncol* 1985; 11: 209 and 349.
5. Hudson PM. Pachydermodactyly. *Br J Dermatol* 1989; 121 (Suppl 34): 111.
6. Marino JM, Villar ML, Pozo T, Quiñones PA. Cojinetes articulares laterales: una localización atípica de "Knuckle pads". *Actas Dermo-Sif* 1990; 81: 473–474.
7. Curley RK, Hudson PM, Marsden RA. Pachydermodactyly: a rare form of digital fibromatosis, report of four cases. *Clin Exp Dermatol* 1991; 16: 121–123.
8. Martin JC, Rennie JAN, Kerr KM. Pachydermodactyly: confused with JCA. *Ann Rheum Dis* 1992; 51: 1101–1102.
9. Sola A, Vazquez-Doval J, Sola J, Quintanilla E. Pachydermodactyly transgrediens. *Int J Dermatol* 1992; 31: 796–797.
10. Draluck JC, Kopf AW, Hodak E. Pachydermodactyly: first report in a woman. *J Am Acad Dermatol* 1992; 27: 303–305.
11. Iraci S, Bianchi L, Innocenzi D, Tomassoli M, Nini G. Pachydermodactyly: a case of an unusual type of reactive digital fibromatosis. *Arch Dermatol* 1993; 129: 247–248.