

Subcutaneous Mucormycosis in a Non-immunocompromised Patient Treated with Potassium Iodide

KAUSHAL K. VERMA and R. K. PANDHI

Department of Dermato-Venereology, All India Institute of Medical Sciences, New Delhi, India

A 55-year-old teacher had had painful subcutaneous swellings on both her arms for 6 years, after receiving intramuscular multivitamin injections for generalized weakness. She did not have fever, constitutional or systemic symptoms. Cutaneous examination revealed ill-defined, subcutaneous, firm, globular, indurated, tender swellings with central softening on both the arms. There was no systemic involvement or lymphadenopathy. Aspiration cytology from one of the lesions showed inflammatory exudate with a mucor-like fungus. Skin biopsy revealed granulomatous inflammation with fungal hyphae resembling mucor within the giant cells. The patient was diagnosed as subcutaneous mucormycosis and treated with saturated solution of potassium iodide. Both the lesions completely disappeared within 10 weeks without any side-effect of the therapy. Key words: opportunistic fungus; immunocompetent; therapy.

(Accepted October 11, 1993.)

Acta Derm Venereol (Stockh) 1994; 74: 215-216.

K. K. Verma, Department of Dermato-Venereology, All India Institute of Medical Sciences, New Delhi-110029, India.

Mucormycosis is a predominantly opportunistic infection caused by *Rhizomucor*, *Absidia*, *Rhizopus* and *Aspergillus* sp., occurring in uncontrolled diabetes mellitus, lymphoproliferative disorders, haematological malignancies, renal failure, transplant recipients on immunosuppressive therapy, severe metabolic diseases and other immunocompromised patients (1-4). Cutaneous involvement may occur secondary to haematogenous spread (5). Occasionally primary cutaneous infection can occur in non-immunocompromised individuals following cutaneous or subcutaneous inoculation of organisms due to local trauma, intravenous therapy or maceration of skin due to adhesive tapes (4, 6).

We report a case of subcutaneous mucormycosis in a non-immunocompromised woman following intramuscular injections.

CASE REPORT

A 55-year-old school teacher presented with painful, globular, deep-seated, ill-defined swellings on both the arms since 6 years. The lesions had started as pea-sized nodules, which slowly increased. She had received multivitamin injections on both the arms for generalized weakness from a medical practitioner 6 years earlier. There was no history of fever, constitutional or systemic symptoms.

Cutaneous examination revealed two ill-defined 8x8 cm and 6x6 cm subcutaneous, globular, firm, indurated, tender swellings with central softening on the outer aspect of the right and left arm, respectively. Skin overlying the lesions was normal. There were no other similar lesions or lymphadenopathy. Systemic examination was unremarkable. Routine haematological, renal and liver function tests, blood sugar, urine, stool and X-ray of the chest were within normal limits. X-ray of the arms did not reveal any bony involvement. A fine needle aspiration cytology

from the right arm swelling showed inflammatory exudate with a fungus resembling mucor. Skin biopsy from the right arm revealed granulomatous inflammation in the subcutaneous tissue, showing fungal hyphae within the giant cells resembling mucor (Fig. 1). The biopsy specimen using normal saline was inoculated on Saboraud's dextrose agar medium and incubated at 37°C and 25°C for 2 weeks, but the organism could not be cultured. A diagnosis of subcutaneous mucormycosis was established and the patient was treated with saturated solution of potassium iodide 10 drops three times a day for 3 weeks. The dose was increased to 12 drops three times a day for the next 2 weeks and further increased to 15 drops three times daily. The pain and tenderness disappeared completely with a reduction of about 50% in the size of the lesions in the first 4 weeks. There was more than 80% improvement in 7 weeks and in the subsequent 3 weeks both the lesions completely subsided. No side-effects, other than increased salivation and mild irritation of the eyes, were seen with the therapy. The patient has been off the treatment for the last 2 years without any evidence of recurrence of the lesions.

DISCUSSION

Primary cutaneous mucormycosis caused by *Rhizomucor*, *Absidia*, *Rhizopus* and *Aspergillus* sp. is an uncommon occurrence in non-immunocompromised individuals. The lesions have been reported following blunt trauma, burns and even insect bites (6-8). Under favourable conditions with adequate exposure or after inoculation, these normal saprophytes can infect the skin and subcutaneous tissue of even non-immunocompromised individuals (9). Since mucormycosis is often life-threatening, particularly in trauma patients, it requires an early diagnosis and prompt treatment (6). Intravenous amphotericin-B and oral potassium iodide constitute the mainstay of treatment, apart from surgical débridement in appropriate conditions (1, 4, 6, 8, 10). Oral ketoconazole has also been used by some workers (11). Our patient acquired the infection either from the traumatized skin caused by the needles or from the contaminated needle

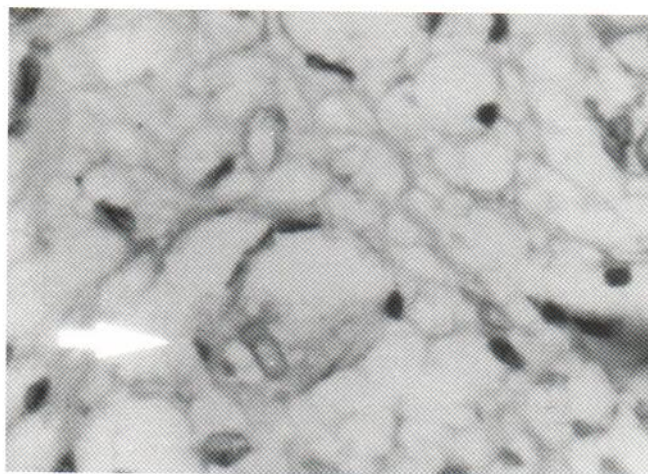


Fig. 1. Fungus (mucor) inside a giant cell (H & E x360).

itself used for intramuscular multivitamin injections, which is a rather unusual mode of acquiring this disease. Aspiration cytology showed the causative fungus, which was subsequently confirmed by skin biopsy where granulomatous infiltrate with fungal hyphae resembling mucor was seen in the giant cells. Histopathological features in these lesions largely depend on the immune status of the patient, which varies from absent to non-specific to granulomatous infiltrate (12). Necrosis and vessel wall invasion are seen in systemic infections extending to skin or in extensive primary cutaneous infections in immunocompromised patients (12). The presence of few organisms and granulomatous infiltrate in our patient is probably due to her normal immune status. Since the fungal hyphae were seen in cytology smear, the culture for other organisms including mycobacteria was not attempted. The patient was treated with oral saturated solution of potassium iodide for 10 weeks, which resulted in complete resolution of the lesions.

REFERENCES

1. Berenguer J, Solera J, Moreno S, Munoz P, Parras F. Mucormycosis. The disease spectrum in 13 patients. *Med Clin* 1990; 94: 766-772.
2. Baker RD. The phycomycosis. *Ann NY Acad Sci* 1970; 174: 592-605.
3. Diamond HJ, Phelps RG, Grordon ML, Lambroza E, Namdari H, Bottone EJ. Combined aspergillus and zygomycotic (*Rhizopus*) infection in a patient with acquired immunodeficiency syndrome presenting as inflammatory tinea capitis. *J Am Acad Dermatol* 1992; 26: 1017-1018.
4. Khardori N, Hayat S, Rolston K, Bodey GP. Cutaneous *Rhizopus* and *Aspergillus* infection in five patients with cancer. *Arch Dermatol* 1989; 125: 952-956.
5. Muniz-Grijalvo O, Rizo Valero A, Miranda Guisado ML, Rodriguez Canas T. Pulmonary mucormycosis with cutaneous metastasis. *Med Clin* 1992; 98: 715.
6. Cocanour CS, Miller-Crotchett P, Reed RL. Mucormycosis in trauma patients. *J Trauma* 1992; 32: 12-15.
7. McCarty IM, Flam MS, Pullen G, Jones R, Kassel SH. Outbreak of primary cutaneous aspergillosis related to intravenous arm boards. *J Paediatr* 1986; 108: 721-724.
8. Prevoo RL, Starink TM, De Haan P. Primary cutaneous mucormycosis in a healthy young girl. Report of a case caused by *Mucor hiemalis* Wehmer. *J Am Acad Dermatol* 1991; 24: 882-885.
9. Gartenberg G, Bottone EJ, Kensch GT, Kausch GT, Weitzman I. Hospital acquired mucormycosis (*Rhizopus rhizopodi formis*) of skin and subcutaneous tissue. *N Engl J Med* 1978; 299: 1115-1118.
10. Costa AR, Porto E, Tayam M, Valente NY, Lacaz-C-da S, Maranhao WM, Rodrigues MC. Subcutaneous mucormycosis caused by *mucor hiemalis* Wehmer f. *luteus* (Linnemann) Schipper 1973. *Mycoses* 1990; 33: 241-246.
11. Roger H, Biat I, Cambon M, Beyrou J, Souteyrand P. *Absidia corymbifera* cutaneous zygomycosis (Mucormycosis) gangrenosum-like ecthyma in a non-immunosuppressed, non-diabetic patient. Treatment with ketoconazole. *Ann Dermatol Venereol* 1989; 116: 844-846.
12. Veliath AJ, Rao R, Prabhu MR, Aurora AL. Cutaneous phycomycosis (mucormycosis) with fatal pulmonary dissemination. *Arch Dermatol* 1976; 112: 509-512.