

## Nd:YAG Laser Hyperthermia in the Treatment of Recalcitrant Verrucae Vulgares (Regensburg's Technique)

ALEXANDER PFAU<sup>1</sup>, TALAL AHMED ABD-EL-RAHEEM<sup>1,2</sup>, WOLFGANG BÄUMLER<sup>1</sup>,  
ULRICH HOHENLEUTNER<sup>1</sup> and MICHAEL LANDTHALER<sup>1</sup>

<sup>1</sup>Department of Dermatology, University of Regensburg, Germany and <sup>2</sup>Department of Dermatology, STD and Andrology, El-Menia University, Egypt

Heat therapy of cutaneous diseases has been used for decades. During the last years several kinds of energy sources, including electromagnetic energy from radiofrequency, microwaves and sonic energy from ultrasound, have been used to produce local hyperthermia. The general principle of this treatment is based on the fact that disease tissue which is being treated is more sensitive to the effects of elevated temperature than normal tissue and thus less able to recover after heat exposure. We report the case of a 54-year-old female patient with recalcitrant verrucae vulgares on the little finger of her right hand and on her left sole, who was treated with Nd:YAG laser hyperthermia. Laser energy was applied twice with an interval of 6 weeks. Laser output power was 10 W, spot size 8 mm and irradiation time up to 20 s. By this technique it was possible to receive a surface temperature of about 40°C for 30 s. After hyperthermia no skin changes like whitish discoloration, blistering or crusting were observed. After the patient had completed the second course a total remission took place. No recurrence was seen in a follow-up period of 3 months. This method could be used in the treatment of recalcitrant warts on the fingers and hands, perianal and other parts of the body including plantar surfaces. **Key words:** laserthermia; warts; heating technique.

(Accepted November 29, 1993.)

Acta Derm Venereol (Stockh) 1994; 74: 212–214.

A. Pfau, University of Regensburg, Franz-Josef-Strauß Allee 11, D-93042 Regensburg, Germany.

Controlled localized heating has been used in veterinary medicine for the treatment of benign (1) and malignant lesions (2, 3). The general principle is that disease tissue which is being treated is more sensitive to the effects of elevated temperature than normal tissue and is thus less able to recover after heat injury. Hyperthermia has for many years been investigated as a way of destroying diseased tissue. The temperature reached during conventional treatment by hyperthermia induced by microwave or radiofrequency applications (41–44°C) (4, 5) has been used in treating a variety of superficial and deep-seated tumours with varying degrees of remission.

Verrucae that are induced by human papillomavirus (HPV) are benign tumours of the skin. They are pleomorphic and can affect a variety of sites, principally skin of the limbs and plantar area, genital skin and mucosa. They occur at any age but are unusual in infants and young children. They spread by direct and indirect contact. Impairment of the epithelial barrier function by trauma, maceration or both greatly predispose to inoculation of the virus.

As a result of the lack of specific antipapillomavirus agents, the treatment of warts is a difficult problem. Hyperthermia has

been used for the treatment of cutaneous leishmaniasis (6, 7) and mycobacterium chelonae (8), since these organisms do not thrive at temperatures above 39–40°C. Many years ago, ultrasound heating of warts was described (9–11) but was presumably abandoned because of inefficient treatment schedules and poor response rates.

### MATERIAL AND METHODS

#### *Regensburg's technique*

Nd:YAG laser hyperthermia was tried in vitro on skin removed as a safety margin excision of a malignant melanoma. The measured temperature of this tissue was 23.1°C (= room temperature). Next, the skin was irradiated by Nd:YAG laser (Axyon GL 001 Nd:YAG laser machine produced by Aesculap Meditec, Germany) with a wavelength of 1064 nm, using 10 W, a single 20 s pulse time and a spot size diameter of the laser beam of 8 mm. As a result, the temperature of the surface of the excised skin was raised to 40–41°C, measured directly after irradiation by thermocouple and thermometer (Fluke 51 Thermometer, John Fluke MFG. CO., INC. Everett, Washington, USA). Putting the thermocouple to the backside of the sample (5 mm thickness), at the dermo-subcutaneous border, the temperature was 44–46°C. So a difference between surface and inside tissue temperature of 5°C was registered after heating procedure by Nd:YAG laser. We suggest that these values correspond with the living skin but the absolute temperature increase may be lower, due to the cooling effects of blood and lymph fluid (12).

The aim of our hyperthermia technique is to raise the temperature of living skin, containing the verruca, from its normal level to about 45°C. This is easily done by using a Nd:YAG laser beam, where a thermal penetration depth of 4–7 mm is reached (13). The measured temperature of the skin surface during heating should be 40–42°C. As our previous observations have shown, the inner temperature of the skin is about 45°C when we raise the surface temperature to 40°C.

For the treatment of verrucae vulgares (Table I) the hand piece is held

Table I. *Regensburg's technique*

- 
- I. Reaching the adequate temperature
    - No local anaesthesia
    - Apply Nd:YAG laser energy with 10 W, a spot size diameter of 8 mm, a pulse time of 20 s
    - Repeat this procedure until a surface temperature of 40°C is reached
  - II. Maintaining the adequate temperature
    - Continue to apply energy to keep a temperature of at least 40°C for a period of 30 s minimum
  - III. Controlling the adequate temperature
    - Measure the surface temperature by contacting the thermocouple with the top of the treated lesion (in order to measure the real temperature heating has to be interrupted)
    - Interrupt lasering for a moment when patient feels unbearable burning
-

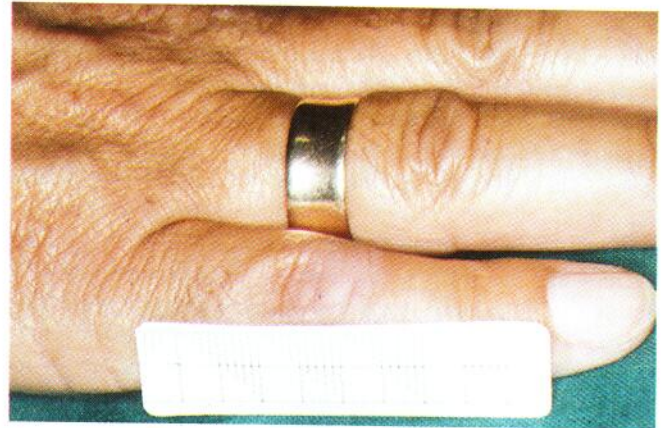
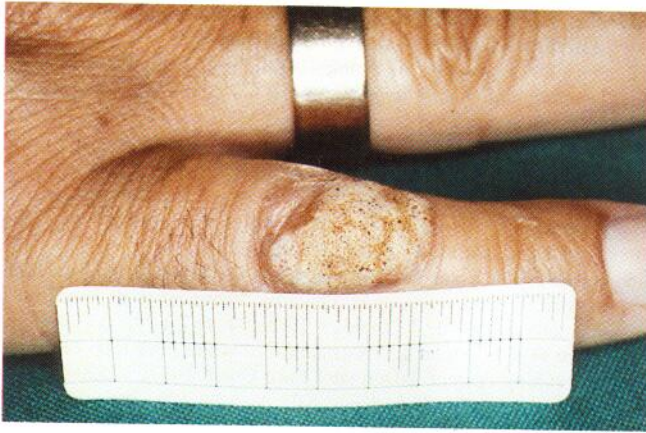
Fig. 1. (a) Sharply circumscribed, yellowish-grey hyperkeratotic lesion on the little finger. (b) Result after treatment with Nd:YAG laser hyperthermia – complete healing.

at a distance of 9 cm from the lesion with a spot size of 8 mm (defocused) and the lesion is divided into several parts if necessary. The energy power is 10 W and the irradiation period is a maximum of 20 s, repeatedly applied until a surface temperature of 40°C is reached, and this temperature is maintained for 30 s at least. No local anaesthesia is used because the procedure is easily tolerated. The patient only feels a slight burning sensation and is instructed to ask the surgeon to stop lasering when this burning becomes hard to bear. Furthermore previous experience proved that local anaesthesia had an unfavourable influence on the healing process. This was due to the lack of patient control of pain sensation, leading to a third degree burn. Surface skin temperature is controlled by thermocouple. After 6 weeks the patient is seen for reevaluation and the next session is performed (Table I).

#### Case report

A 54-year-old female patient presented with verrucae vulgares on the little finger of her right hand and on her left sole. They had been present for more than 2 years and had been repeatedly treated with local acids, keratolytic and antimetabolic solutions and cryosurgery. So far the different treatments had not been followed by any visible success. On the skin covering the interphalangeal joint of the little finger of the right hand we found a sharply circumscribed, yellowish-grey hyperkeratosis measuring 1.7 × 1.0 cm with punctate black spots due to blood deposits. On the lateral aspect of the sole of the right foot there was another solitary hyperkeratotic lesion of yellowish-brown colour also containing black spots and measuring 1.7 × 1.0 cm. Both lesions were treated with Nd:YAG laser hyperthermia using the technique described above. The application was repeated after an interval of 6 weeks. The control another 6 weeks later showed a complete remission of both warts. There was no recurrence in a follow-up period of 6 months.

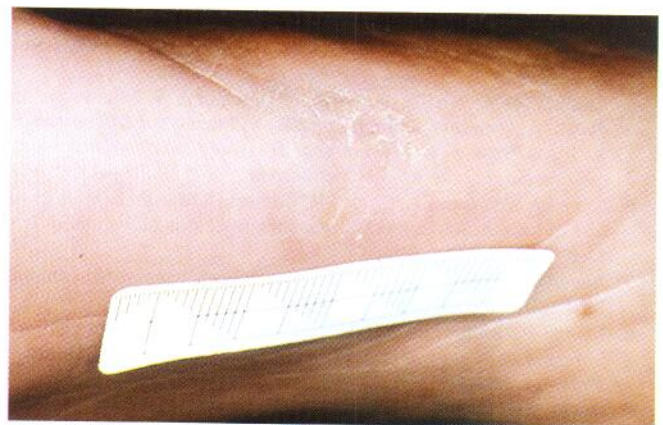
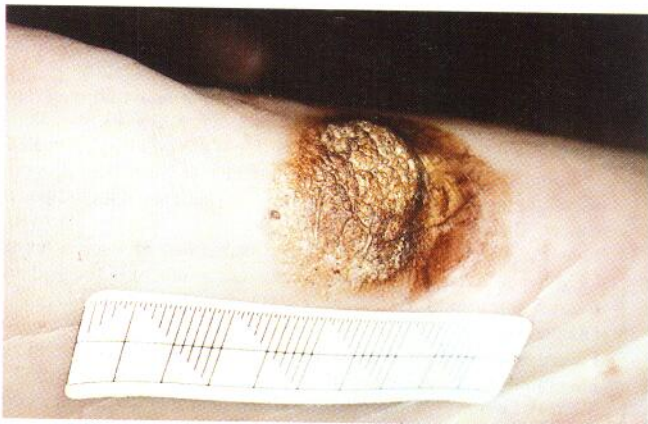

Fig. 2. (a) Yellowish-brown hyperkeratotic lesion on the sole of the right foot. (b) Result after treatment with Nd:YAG laser hyperthermia – complete healing.

#### DISCUSSION

The treatment of warts is often considered as a difficult problem because of the lack of specific antipapillomatous agents available for therapy. The goal of current modalities is to destroy the infected cells by cryosurgery or other physical means (14–19), to exert an antimetabolic effect (20–22), to induce an enhanced immunologic response to the infected tissue (23–26) or to wish away the warts by psychological means (27, 28). When these techniques fail, some clinicians surgically excise the warts. Over the past few years, the carbon dioxide laser (CO<sub>2</sub>) has become a relatively common modality in the treatment of warts and especially lesions known to be resistant to other traditional modalities (29). Drawbacks as scarring of the skin, irradiated skin, a prolonged period of postoperative recovery, infection, late bleeding as well as the presence of viable viral particles in the laser plume during the laser procedure were described (30, 31).

Hyperthermia, for example, was used for the treatment of cutaneous leishmaniasis (6, 7) and mycobacterium chelonae (8). The general principle is that diseased tissue which is being treated is more sensitive to the effects of elevated temperature than normal tissue and able to recover after heat injury. Several kinds of energy resources have been developed during the last years to produce local hyperthermia, including electromagnetic

energy from radiofrequency (32), microwaves (33), sonic energy from ultrasound (34) and laser energy from Nd:YAG laser referred to as laserhyperthermia (35).

In 1992, Stern & Levine (36) demonstrated that localized heating can cause regression of warts in a high percentage of cases. Their data do not allow one to claim "cures", since long-term follow-up was not accomplished. However, their patients were followed up for an average of 15.6 weeks after therapy and there was no evidence of recurrence after clinical resolution of the individual warts. The 86% complete regression rate compares favourably with other modalities of treatment.

The mechanism of the action of heat in wart therapy is not known. It is possible that epidermal necrosis from a superficial burn physically removes the wart virus, much as any destructive mode of therapy does. There is the possibility that heat directly destroys the virus or that the inflammatory response itself contributes to viral eradication.

Nd:YAG laser hyperthermia could be an effective method for treating verrucae vulgares. As the skin remains intact there is no bleeding during the application and the treatment is not followed by scarring, both considerable advantages compared with CO<sub>2</sub> laser treatment. The method is not too painful and is controlled by the patients pain threshold. The procedure is rapid and has to be repeated only a few times; therefore the compliance of the patients can be regarded as excellent. Furthermore this treatment is not expensive if compared with basic traditional methods.

The aim of this work was to describe a new technique using Nd:YAG laser for hyperthermia in the treatment of verrucae vulgares. Since Nd:YAG lasers are present in many centres, e.g. urologic, gastroenterologic and gynecologic departments, this method could easily be used in the routine treatment of warts following the given parameters. More investigations on a greater number of patients will be carried out to determine the efficacy, to examine the ideal parameters and to study further the range of indications of this promising method.

## REFERENCES

1. Leuker DC, Kainer RA. Hyperthermia for the treatment of dermatomycosis in dogs and cats. *Vet Med* 1981; 16: 658-659.
2. Grier RL, Brewer WG Jr, Thielen GH. Hyperthermic treatment of superficial tumors in cats and dogs. *J Am Vet Assoc* 1980; 177: 227-233.
3. Kainer RA. Current concept in the treatment of bovine ocular squamous cell tumors. *Vet Clin North Am* 1984; 6: 609-622.
4. Storm KF, Kaiser LR, Goodnight JE. Thermotherapy for melanoma metastases in liver. *Cancer* 1982; 49: 1243-1248.
5. Lindholm CE, Kjellman E, Nilson P, Hertzman S. Microwave induced hyperthermia and radiotherapy in human superficial tumors - clinical results with a comparative study of combined versus radiotherapy alone. *Int J Hyperthermia* 1987; 3: 393-411.
6. Neva FA, Petersen EA, Corsey R, Bogsert H, Martinez D. Observation of local heat treatment for cutaneous leishmaniasis. *Am J Trop Med* 1984; 33: 800-804.
7. Junaid AJN. Treatment of cutaneous leishmaniasis with infrared. *Int J Dermatol* 1986; 25: 470-472.
8. Levine N, Rothschild JG. Treatment of Mycobacterium chelonae infection with controlled localized heating. *J Am Acad Dermatol* 1991; 24: 867-870.
9. Daelos ZK, Levine N. Hyperthermic treatment of cutaneous malignancies. *J Am Acad Dermatol* 1983; 8: 623-628.
10. Rowe RJ, Gray JM. Ultrasound therapy of plantar warts. *Arch Dermatol* 1960; 82: 1008-1009.
11. Cherup N, Urban J, Bender LF. The treatment of plantar warts with ultrasound. *Arch Phys Med* 1963; 44: 602-609.
12. Pensel J, Hofstetter A, Frank F, Keiditsch E, Rothenberger K. Temporal and spatial temperature profile of the bladder serosa in intravesical Nd:YAG laser irradiation. *Eur Urol* 1981; 7: 298-303.
13. McKenzie AL. Physics of thermal processes in laser-tissue interaction. *Phys Med Bio* 1990; 35(9): 1175-1209.
14. Kalivas L, Penick E, Kalivas J. Personality factors as predictors of therapeutic response to cryosurgery in patients with warts. *J Am Acad Dermatol* 1989; 20(3): 429-432.
15. Bunney MH, Nolan MW, Williams DA. An assessment of methods of treating viral warts by comparative treatment trials based on a standard design. *Br J Dermatol* 1976; 94: 667-679.
16. Wyre HW Jr, Stolar R. Excimer laser treatment of warts by a loop electrode and cutting current. *J Dermatol Surg Oncol* 1977; 3: 520-522.
17. Beutner KR, Friedman-Kien AE, Artman NN. Patient applied podofilox for treatment of genital warts. *Lancet* 1989; i: 831-833.
18. Logan RA, Zachary CB. Outcome of carbon dioxide laser therapy for persistent cutaneous viral warts. *Br J Dermatol* 1989; 121: 99-109.
19. Macht SH. Superficial radiotherapy of warts: results of treating 531 warts. *Radiology* 1977; 122: 231-232.
20. Bunney MH, Nolan NW, Buxton PK, Going SM, Prescott BJ. The treatment of resistant warts with intralesional bleomycin: a controlled clinical trial. *Br J Dermatol* 1984; 4: 633-649.
21. Goette DK. Topical chemotherapy with 5-fluorouracil. *J Am Acad Dermatol* 1981; 4: 633-649.
22. Golmetti C, Cerri D, Schuima AA, Menni S. Treatment of extensive warts with etretinate: a clinical trial in 20 children. *Pediatr Dermatol* 1987; 4: 254-258.
23. Buckner D, Price NM. Immunotherapy of verrucae vulgares with dinitrochlorobenzene. *Br J Dermatol* 1978; 98: 451-455.
24. Naylor MF, Neldner KH, Yarbrough GK, Rosio TJ, Iriando M, Yearly J. Contact immunotherapy of resistant warts. *J Am Acad Dermatol* 1988; 19: 679-683.
25. Androphy EJ, Dvoretzky I, Maluish AE, Wallace HJ, Lowy DR. Response of warts in epidermodysplasia verruciformis to treatment with systemic and intralesional alpha interferon. *J Am Acad Dermatol* 1984; 11: 197-202.
26. Eron LJ, Judson F, Tucker S. Interferon therapy for condylomata acuminata. *N Engl J Med* 1989; 315: 1059-1064.
27. Johnson RE, Barber TX. Hypnosis, suggestions, and warts: an experimental investigation implicating the importance of "believed-in efficacy". *Am J Clin Hypn* 1978; 20: 165-174.
28. Litt JA. Don't excise-exorcise: treatment of subungual and peri-ungual warts. *Cutis* 1978; 22: 673-677.
29. Logan RA, Zachary CB. Outcome of carbon dioxide laser therapy for persistent cutaneous viral warts. *Br J Dermatol* 1989; 121: 99-105.
30. Sawchuk WS, Weber PJ, Lowy DR, Dzubow LM. Infectious papillomavirus in the vapor of warts treated with carbon dioxide laser or electrocoagulation: detection and protection. *J Am Acad Dermatol* 1989; 21: 41-49.
31. Taylor MB. Successful treatment of warts. *Postgrad Med* 1988; 84: 126-128.
32. Enami B, Perez CA. Interstitial thermoradiography: an overview. *Endocurietherapy/Hypothermia Oncol* 1985; 1: 35-40.
33. Hornback NB, Shupe RE, Shidnia H, Joe BT, Sayol E, Marshall C. Preliminary clinical results of combined 433 Mega Hertz microwave therapy and radiation therapy in patients with advanced cancer. *Cancer* 1977; 40: 2854-2868.
34. Lele PP, Parker KJ. Temperature distributions in tissues during local hyperthermia by stationary or seated beams of unfocused and focused ultrasound. *Br J Cancer* 1982; Suppl. 45: 108-121.
35. Diakuzono N, Joffe SN, Tajiri H, Suzuki S, Tsunekawa H, Ohyama M. Laserthermia: a computer controlled contact Nd:YAG system for interstitial local hyperthermia. *Med Instrum* 1987; 21: 275-277.
36. Stern P, Levine N. Controlled localized heat therapy in cutaneous warts. *Arch Dermatol* 1992; 128: 945-948.