

# Immunohistochemical Localization of p53 Protein in Malignant Hemangioendothelioma

SHINICHI INOHARA

Department of Dermatology, Hyogo College of Medicine, Nishinomiya, Hyogo, Japan

The immunohistochemical localization of p53 protein was examined in skin tissue sections, including normal vascular endothelial cells and the skin tissue sections from lesions of granuloma telangiectaticum with proliferation of vascular endothelial cells and malignant hemangioendothelioma, a malignant tumor originated from vascular endothelial cells. It was found that p53 protein was positive in 2 out of 4 cases of malignant hemangioendothelioma. Thus, immunohistochemical detection of p53 protein proved useful in the diagnosis of malignant hemangioendothelioma.

(Accepted August 16, 1993.)

Acta Derm Venereol (Stockh) 1994; 74: 161–162.

S. Inohara, Department of Dermatology, Hyogo College of Medicine, Nishinomiya, Hyogo 663, Japan.

Mutations of the p53 tumor suppressor gene have been reported in many kinds of human malignant tumors (1). Mutant p53 protein has a greatly extended intracellular half-life and so accumulates to much higher concentrations in cells (2). This has made it possible to conduct immunohistochemical examinations using a monoclonal antibody against p53 protein (2).

There has been no report on the abnormality of p53 in malignant tumors originated from vascular endothelial cells. In this study, immunohistochemical localization of p53 protein was examined in skin tissue sections, including normal vascular endothelial cells and the skin tissue sections from lesions of granuloma telangiectaticum with proliferation of vascular endothelial cells and malignant hemangioendothelioma, a malignant tumor originated from vascular endothelial cells.

## MATERIALS AND METHODS

Normal skin of 5 healthy subjects, skin lesions of 5 cases of granuloma telangiectaticum and 4 cases of angiosarcoma were excised surgically. Specimens were formalin-fixed and subsequently embedded in paraffin wax prior to sectioning. 5- $\mu$ m sections from the specimens were mounted on glass slides, air-dried, then de-waxed and rehydrated through graded ethanol. After hydration in phosphate-buffered saline (PBS), the sections were incubated with anti-p53 protein monoclonal antibody (BP53-12(2); Japan Tanner, Kobe, Japan, 1:20 dilution) for 1 h at room temperature. The sections were washed in PBS and visualized by the avidin-biotin detection system (Dakopatts Japan, Kyoto, Japan).

## RESULTS

p53 protein positivity was not detected in the specimens of normal individuals and patients with granuloma telangiectaticum (Fig. 1a, b). However, p53 protein-positive cells were found in 2 out of 4 cases of malignant hemangioendothelioma. p53 protein-positive nuclear staining was seen in some of the tumor cells (Fig. 1c).

## DISCUSSION

It has been made clear by the present study that p53 protein can serve as a tumor marker for malignant hemangioendothelioma. p53 protein has already been shown immunohistochemically in

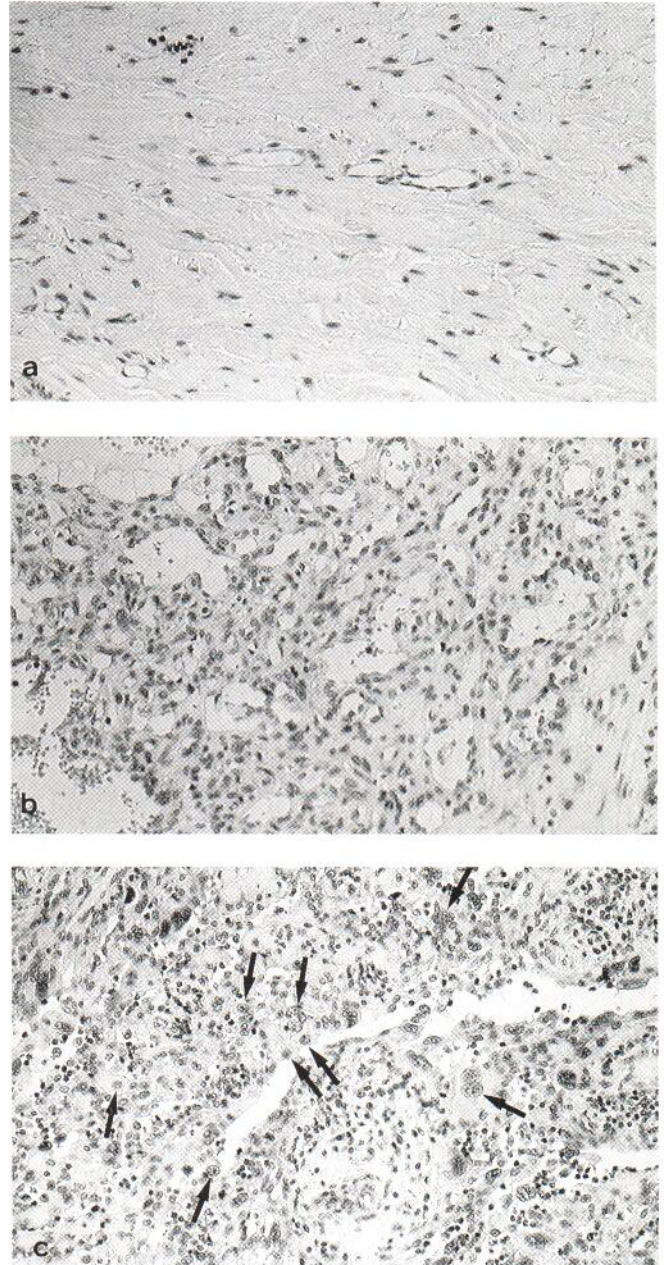


Fig. 1. Immunohistochemical localization of p53 in normal capillaries (a), granuloma telangiectaticum (b) and malignant hemangioendothelioma (c) ( $\times 200$ ).



many kinds of human malignant tumors (2). In addition, p53 protein has been confirmed immunohistochemically in various kinds of skin cancer (4–6). However, the positivity rate and the number of positive cells differ according to the kinds of skin cancer. In the present study, p53 protein was positive in 2 out of 4 cases of malignant hemangioendothelioma, and p53 protein was present in only some of the tumor cells in the cases where p53 protein was positive (Fig. 1c). As to the positivity rate of p53 protein in malignant hemangioendothelioma, it cannot be discussed, since the number of cases is limited. However, the number of p53 protein-positive cells in the cases where p53 protein was positive seems to be smaller than the number already reported concerning squamous cell carcinoma (SCC) of the epidermis. The same was true when compared with our examination of SCC (7). So the reason why the positivity rate of p53 protein and the number of p53 protein-positive cells in the cases where p53 protein is positive are different according to the kind of malignant tumor remains obscure.

Recently, however, a possibility has been suggested that p53 protein is concerned with the later stage of development in colorectal cancer (8) and with the early stage in SCC of the epidermis (4). Therefore it is also possible that the time at which p53 protein becomes positive differs according to the kind of malignant tumor. As concerns the role of p53 protein in the development of malignant hemangioendothelioma, further investigations are needed.

## ACKNOWLEDGEMENTS

The author wishes to thank Miss R. Fujimoto and K. Hashizume for their skilful technical assistance.

## REFERENCES

1. Hollstein M, Sidransky D, Vogelstein B, Harris CC. p53 mutations in human cancers. *Science* 1991; 253: 49–53.
2. Bártek J, Bártková J, Vojtesek B, et al. Aberrant expression of the p53 oncoprotein is a common feature of a wide spectrum of human malignancies. *Oncogene* 1991; 6: 1699–1703.
3. Lever WF, Lever GS. *Histopathology of the skin*. 7th edn. Philadelphia: J. B. Lippincott, 1990: 695–697.
4. McGregor JM, Yu CC-W, Dublin EA, Levison DA, Macdonald DM. Abberant expression of the p53 tumour-suppressor protein in non-melanoma skin cancer. *Br J Dermatol* 1992; 127: 463–469.
5. Stephenson TJ, Royds J, Silcocks PB, Bleehen SS. Mutant p53 oncogene expression in keratoacanthoma and squamous cell carcinoma. *Br J Dermatol* 1992; 127: 566–570.
6. Ro YS, Cooper PN, Lee JA, et al. p53 protein expression in benign and malignant skin tumours. *Br J Dermatol* 1993; 128: 237–241.
7. Inohara S, Okamoto E, Kitano Y. Immunocytological localization of cdc2 in human keratinocytes – comparative study of p53 and PCNA. *Arch Dermatol Res* (submitted).
8. Fearon ER, Vogelstein B. A genetic model for colorectal tumorigenesis. *Cell* 1990; 61: 759–767.