

## Steroid Injection Therapy for Pseudocyst of the Auricle<sup>1</sup>

HIDEAKI MIYAMOTO<sup>1</sup>, MIHO OIDA<sup>1</sup>, SUMI ONUMA<sup>1</sup> and MITSUAKI UCHIYAMA<sup>2</sup>

<sup>1</sup>Division of Dermatology, Hiratsuka Mutual Aid Hospital, Hiratsuka, and <sup>2</sup>Division of Dermatology, Kanagawa Prefecture Cancer Center, Yokohama, Japan

**In our clinic, we encountered 8 patients with pseudocyst of the auricle during a 6-year period from 1987 to 1992 and injected steroid solution locally into the pseudocysts. Three of these patients had no recurrences and 4 were treated successfully after 1–3 recurrences. In only one case was this therapy ineffective. After 11 injections, which resulted in permanent deformity of the auricle, the patient underwent surgery. We believe that local steroid injection therapy should be the first choice method for treating auricular pseudocysts. However, frequent injections can cause auricular deformity and if there are more than 3 recurrences, the pseudocyst should be managed surgically. The lactate dehydrogenase levels of the cystic fluid were determined in 3 of the 8 patients and proved high; in only one patient was the etiology of the pseudocyst thought to be associated with minor trauma. Key words: Lactate dehydrogenase; Ear deformities; Trauma.**

(Accepted August 30, 1993.)

Acta Derm Venereol (Stockh) 1994; 74: 140–142.

H. Miyamoto, Division of Dermatology, Hiratsuka Mutual Aid Hospital, 9–11, Oiwake, Hiratsuka City, 254, Japan.

Pseudocyst of the auricle is a rarely reported lesion that is characterized by intercartilaginous cyst formation affecting the upper half of the auricle (1). Various therapeutic approaches have been used to treat auricular pseudocysts. In 1985, Okuma (2) described 3 patients who were treated successfully with a non-surgical technique, which included needle aspiration followed by local steroid injection. We have tried this intralesional corticosteroid therapy in 8 patients using Okuma's method (2) and 7 were managed successfully.

### MATERIALS AND METHODS

#### Patients

Eight Japanese patients (7 men and 1 woman, aged 16–50 years) with pseudocyst of the auricle who were seen in the Division of Dermatology at the Hiratsuka Mutual Aid Hospital between 1987 to 1992 participated in this study. Seven were diagnosed according to their clinical courses and features and one after additional histopathological examination. One patient (case 4) suffered from severe atopic dermatitis and his intelligence quotient was 70; another patient (case 7) could not sit up owing to cerebral paralysis from birth and was usually lying in bed with the affected ear on the pillow. The other patients had no complications.

#### Methods

Local anesthesia (1% w/v lidocaine, 1 ml) of the pseudocyst was carried out. The anesthetized area was pierced with a sterile hypodermic needle and all the pseudocystic fluid was aspirated into an empty syringe.

Steroid fluid (triamcinolone suspension, 13.3 mg/ml) was injected to fill the pseudocyst cavity almost to its original size using another syringe. Gauze was then pressed gently on the auricular surface to stop the bleeding and prevent the fluid from escaping through the needle hole.

Each patient was followed up every week for 4 weeks.

### RESULTS

Three patients (cases 1, 3 and 5) were cured by 1 or 2 injections and had no recurrences; 2 patients (cases 2 and 7) were cured by 2 or 4 injections and each had one recurrence; 1 patient (case 8) was cured by 2 injections and had 2 recurrences; and 1 patient (case 6) was cured by 7 injections and had 3 recurrences. Despite receiving 11 injections over 10 months, one patient (case 4) had 9 recurrences, and the auricular cartilage was deformed. The deformation remained after surgical compression suture therapy, after which no recurrence was observed.

The lactate dehydrogenase levels in the cystic fluid were determined in 3 patients and were high (1043 IU/l in case 6, 4430 IU/l in case 7 and 2678 IU/l in case 8, Table I). Their serum lactate dehydrogenase levels were within the normal range. The isozymic pattern of lactate dehydrogenase was not examined.

### DISCUSSION

Lactate dehydrogenase levels in the cystic fluid of auricular pseudocysts have been reported to be high (3–5). We observed this in the 3 patients in whom we measured the levels. Umebayashi et al. (5) examined the lactate dehydrogenase isozymic pattern and reported that types 4 and 5 were predominant in the cystic fluid, whereas types 1 and 2 predominated in the serum. They speculated that the pseudocyst is maintained in an active disease state because type 4 and 5 are primarily unstable and easily inactivated in the cystic fluid and in the serum (6).

The cause of pseudocyst of the auricle remains to be established, as most patients deny any history of inflammation or trauma. However, cases with antecedent trauma and a fracture in the conchal cartilage (7) and associated with minor trauma, such as sleeping on a hard pillow or wearing stereo headphones or a motorcycle helmet, have been reported (8). In our series, the pseudocyst of case 7 may have been associated with minor trauma, because she usually lay in bed with the affected ear against the pillow, as she suffered from cerebral paralysis.

Various treatments for pseudocyst of the auricle have been reported, namely needle aspiration (9), incision and drainage with pressure dressing (10–12), needle aspiration with pressure dressing (8, 13–15), drainage and pressure dressing (16), compression suture therapy (17, 18), intralesional administration of tincture of iodine (1, 11, 12), intracartilaginous trichloroacetic acid and pressure dressing with button bolsters (19), intramuscular corticosteroid therapy (8), high-dose oral corti-

<sup>1</sup> Presented at the 89th Annual Meeting of the Japanese Dermatological Association.

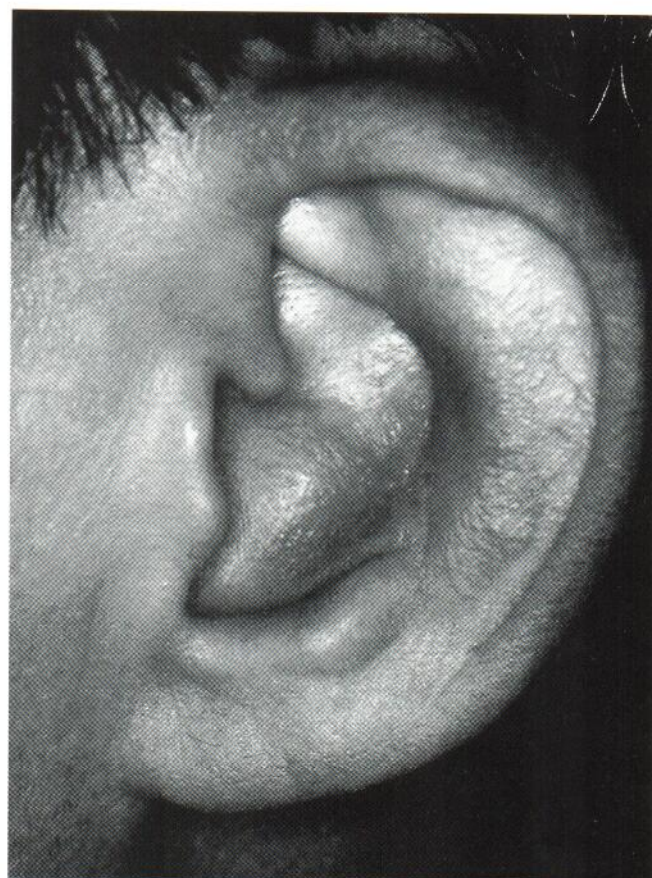
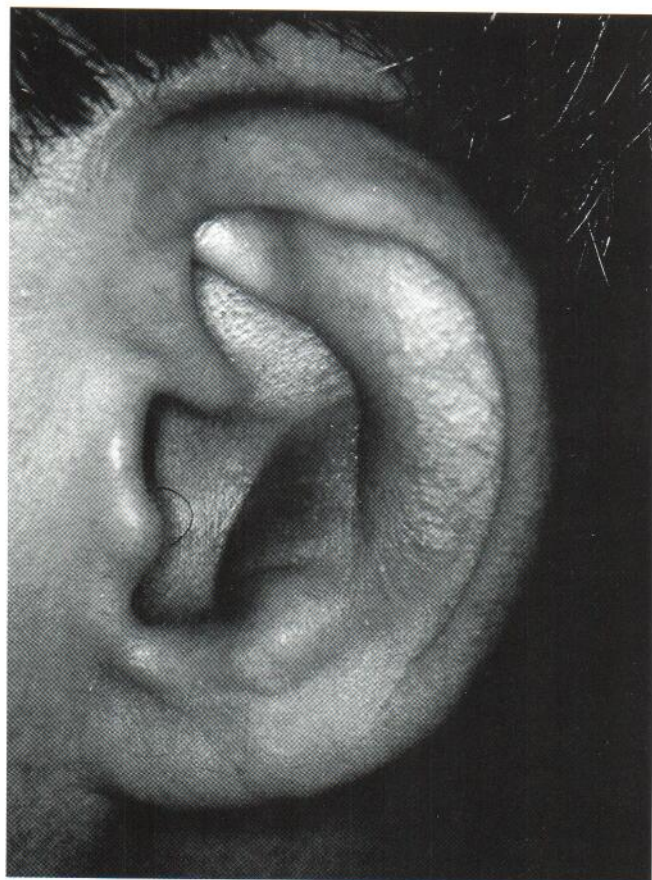


Fig. 1. (A) Pseudocyst of the auricle in the concha of the left ear of patient no. 3. (B) Almost normal appearance of the auricle 4 days after treatment.

costeroid therapy (20) and intralesional corticosteroid therapy (2, 8, 21). Each treatment has its demerits, such as reaccumulation of fluid within the lesion, or is a difficult surgical technique. In patients treated with intralesional corticosteroid therapy, a permanent deformity of the ear has been observed (8). But Kunachak (21) reported that no auricular deformation occurred in 32 patients treated with intralesional corticosteroid therapy, 31 of 32 whom had no recurrences and only one required a second treatment. In our series, 3 of the 8 patients had no recurrences and 4 were treated successfully after 1–3 recurrences. In only one patient was intralesional corticosteroid

therapy ineffective and auricular deformity occurred, attributable to the frequent corticosteroid injections administered and a larger pseudocystic cavity than in the other patients. In conclusion, we believe that steroid injection therapy should be the first choice treatment for pseudocyst of the auricle, since this method is very simple compared with surgical techniques, especially for dermatologists not interested in surgery. In the majority of cases, it is also effective. If there are more than 3 recurrences, a surgical procedure, such as compression suture therapy (18), should be carried out. Although we administered a second injection before the first had achieved its utmost effect in some cases, it is necessary to wait at least 3 weeks to ascertain whether the first has been successful.

Table I. Eight cases treated with intralesional corticosteroid

LDH = lactate dehydrogenase.

Case No.	Age/sex	Recurrence	Total no. of injections	Complication	Examination of cyst fluid
1.	42/M	None	2	None	Not done
2.	24/M	1	4	None	Not done
3.	41/M	None	1	None	Not done
4.	26/M	9	11	IQ 70, atopic dermatitis	Germiculture: <i>Staphylococcus aureus</i>
5.	46/M	None	2	None	Not done
6.	50/M	3	7	None	LDH 1043
7.	16/F	1	2	Cerebral paralysis	LDH 4430
8.	43/M	2	2	None	LDH 2678

## REFERENCES

- Engel D. Pseudocyst of the auricle in Chinese. *Arch Otolaryngol* 1966; 83: 197–202.
- Okuma M. Treatment for pseudocyst of the auricle. *Jpn J Dermatol* 1985; 95, 390.
- Takino C, Furui Y. Two cases of pseudocyst of the auricle. *Rinsho Hifuka* 1983; 37: 905–909.
- Hashizume S, Morita M, Iwata H, Nozaki E, Ikari Y, Chiba N. Bilateral pseudocyst of the auricle. *Rinsho Hifuka* 1989; 43: 1047–1051.
- Umebayashi Y, Ueno K. A case of pseudocyst of the auricle. *Rinsho Derma* 1991; 33: 679–682.
- Maekawa M. *Rinsho kensa Mook*, Kanehara Shuppan (Tokyo). 1982: 18–29.
- Grabski WJ, Salasche SJ, MacCollough ML, Angeloni VL. Pseu-

- docyst of the auricle associated with trauma. Arch Dermatol 1989; 125: 528-530.
8. Gramb R, Kim R. Pseudocyst of the auricle. J Am Acad Dermatol 1984; 11: 58-63.
  9. Ramesh V. Pseudocyst of the auricle. Dermatologica 1986; 172: 125-126.
  10. Job A, Bhanu TS, Mathai R, Raghaven R. Pseudocyst of the auricle. J Laryngol Otol 1988; 102: 344-345.
  11. Hansen JE. Pseudocyst of the auricle in Caucasians. Arch Otolaryngol 1967; 85: 13-14.
  12. Santos VB, Polisar IR, Ruffy ML. Bilateral pseudocyst of the auricle in a female. Ann Otol Rhinol Laryngol 1974; 83: 9-11.
  13. Choi S, Lam KH, Chan Kw, Ghadially FN, Anthony SM. Endochondral pseudocyst of the auricle in Chinese. Arch Otolaryngol 1984; 110: 792-796.
  14. Lapins NA, Odom RB. Seroma of the auricle. Arch Dermatol 1982; 118: 503-505.
  15. Shanmugham MS. Pseudocyst of the auricle. J Laryngol Otol 1985; 99: 701-703.
  16. Zhu LX, Wang X. New technique for treating pseudocyst of the auricle. J Laryngol Otolaryngol 1990; 104: 31-32.
  17. Ophir D, Marshak G. Needle aspiration and pressure sutures for auricular pseudocyst. Plastic Reconstruct Surg 1991; 87: 783-784.
  18. Karakshian GV, Lutz-Nagey LL, Anderson R. Pseudocyst of the auricle: compression suture therapy. J Dermatol Surg Oncol 1987; 13: 74-75.
  19. Cohen PR, Katz BE. Pseudocyst of the auricle: successful treatment with intracartilaginous trichloroacetic acid and button bolsters. J Dermatol Surg Oncol 1991; 17: 255-258.
  20. Job A, Raman R. Medical management of pseudocyst of the auricle. J Laryngol Otolaryngol, 1992; 106: 159-161.
  21. Kunachak S, Prakunhungsit S. A simple treatment for endochondral pseudocyst of the auricle. J Otolaryngol 1992; 21: 139-141.